

# MI-COD

MSS INDIA- Case Of the Day



11/11/2024


Case contributor- Dr. Suvinay Saxena

Musculoskeletal Society of India (MSS) &  
Indian Journal of Musculoskeletal Radiology  
(IJMSR), the official publication of MSS India

For MICOD case archives visit  
<https://www.indianmss.org/>

*Authentic source of MSK  
Radiology*

For daily MSK radiology updates, follow us on

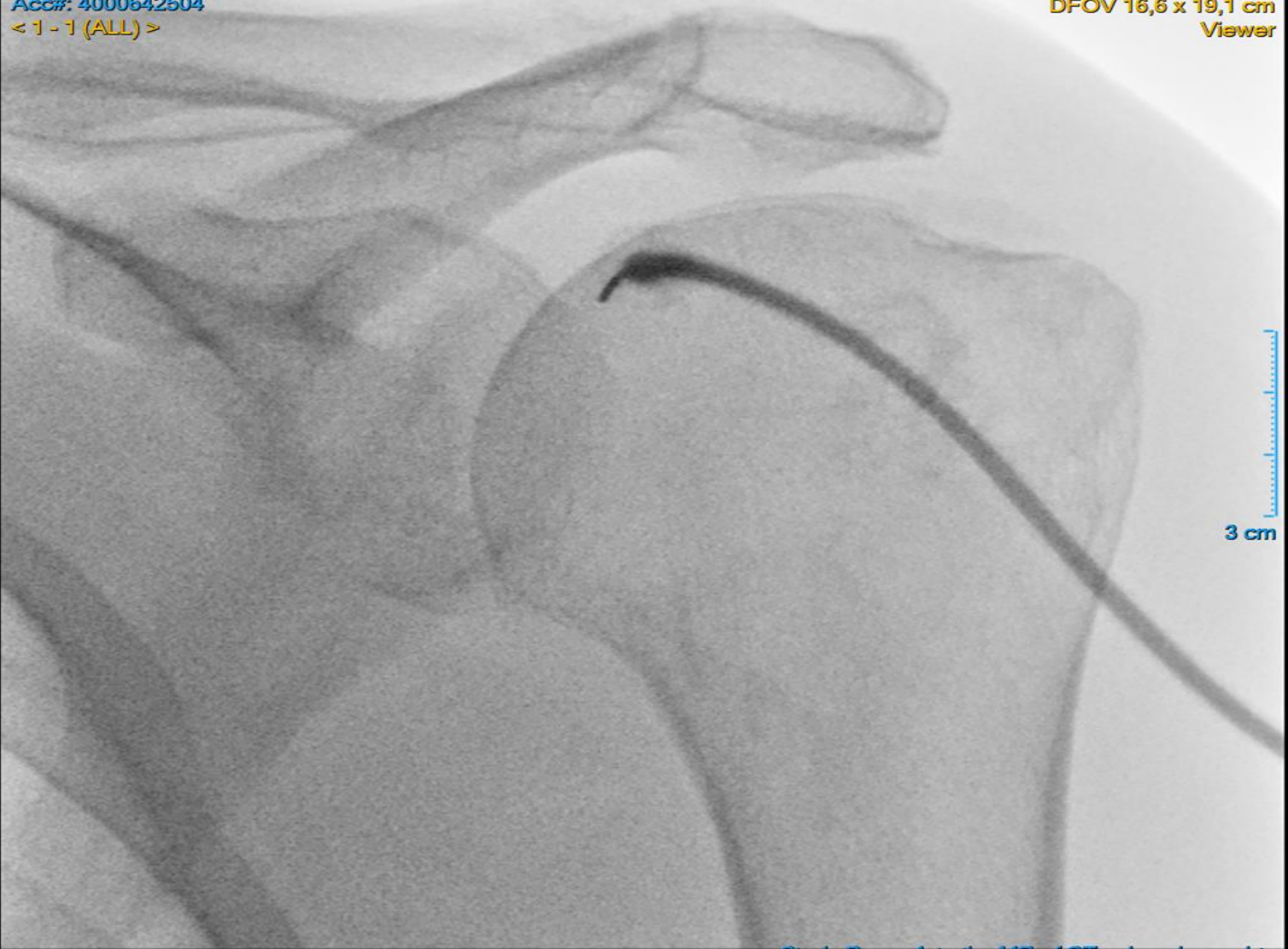


@MSKSocietyIndia  
@IJMSR\_MSSIndia

@indiask  
@IJMSR

20-2-1952  
Laterality: R  
SI:1  
Acc#: 4000642504  
< 1 - 1 (ALL) >

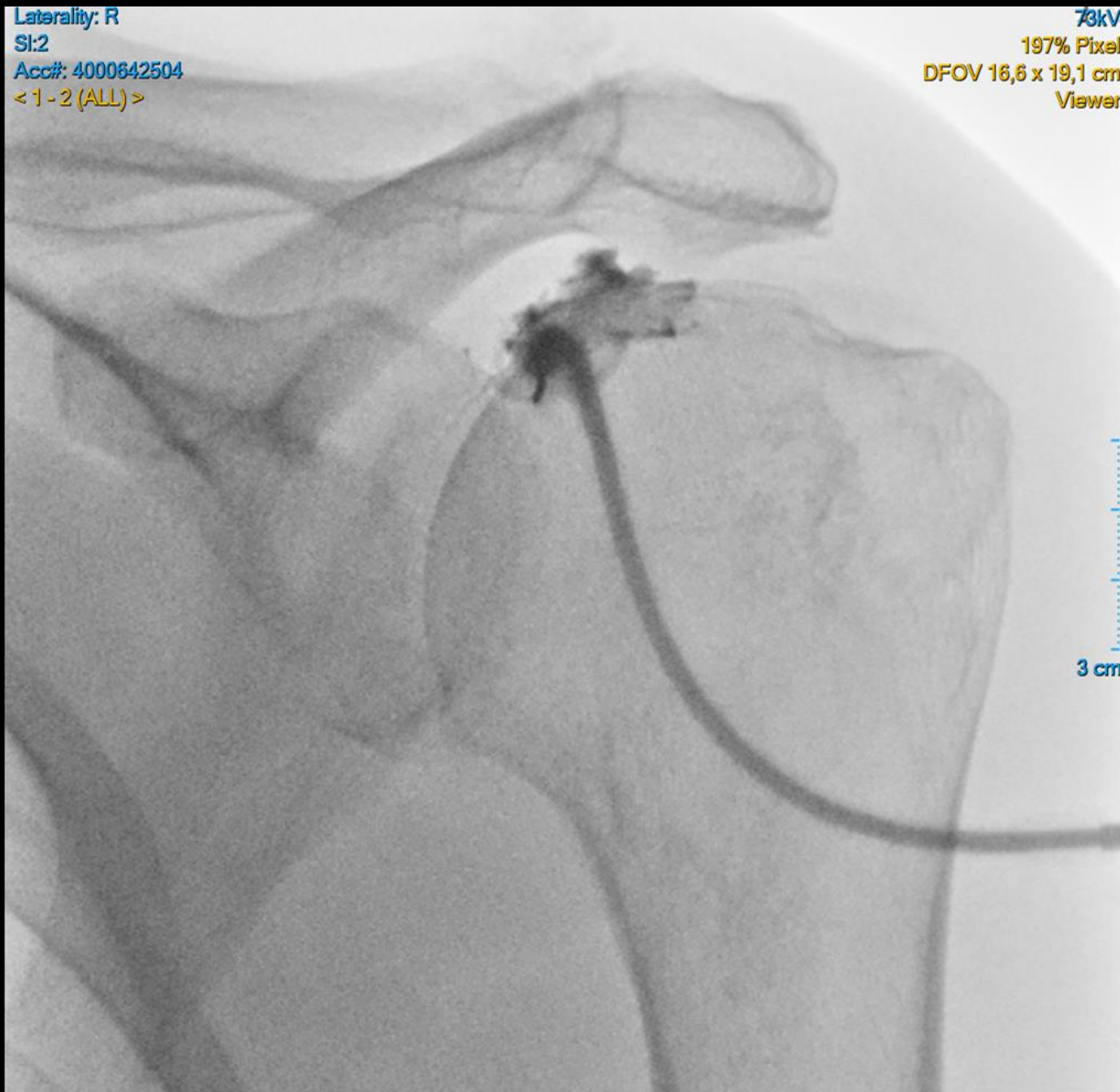
Canon Inc. CXDI Controller RF  
73kV  
197% Pixel  
DFOV 16,6 x 19,1 cm  
Viewer



3 cm

Laterality: R  
SI:2  
Acc#: 4000642504  
< 1 - 2 (ALL) >

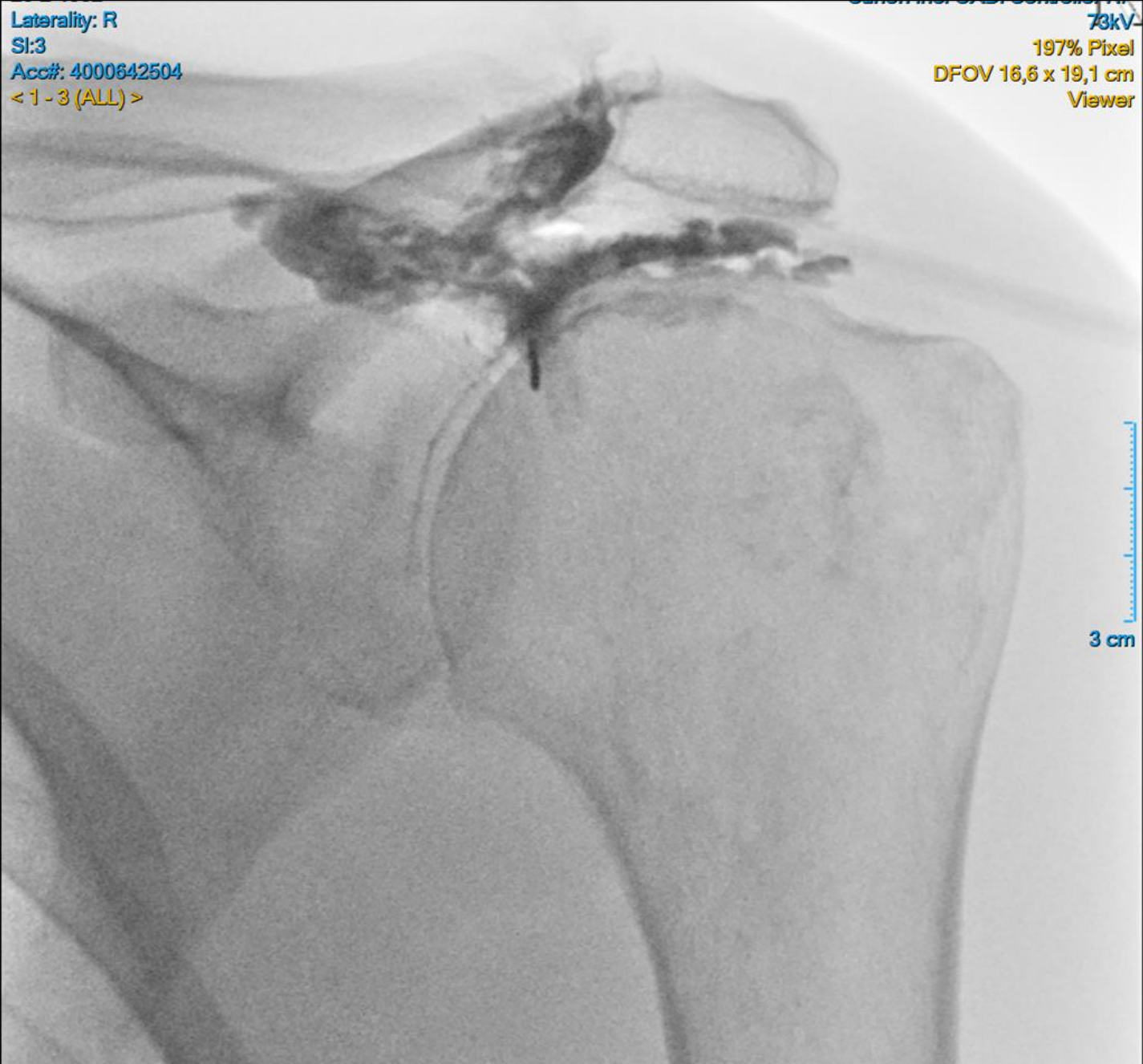
73kV-  
197% Pixel  
DFOV 16,6 x 19,1 cm  
Viewer



3 cm

Laterality: R  
SI:3  
Acc#: 4000642504  
< 1 - 3 (ALL) >

73kV  
197% Pixel  
DFOV 16,6 x 19,1 cm  
Viewer



- **What is the ideal needle position??**
- **What are your findings?**
- **What's the phenomenon called and what will you suspect on MRI?**