

MI-COD

MSS INDIA- Case Of the Day



06/11/2024

Case contributor – Dr. Sagar Tomar

Musculoskeletal Society of India (MSS) &
Indian Journal of Musculoskeletal Radiology
(IJMSR), the official publication of MSS India

For MICOD case archives visit <https://www.indianmss.org/>

Check out our latest publication at <https://mss-ijmsr.com/>

Authentic source of MSK Radiology

For daily MSK radiology updates & great educational
contents, follow us on



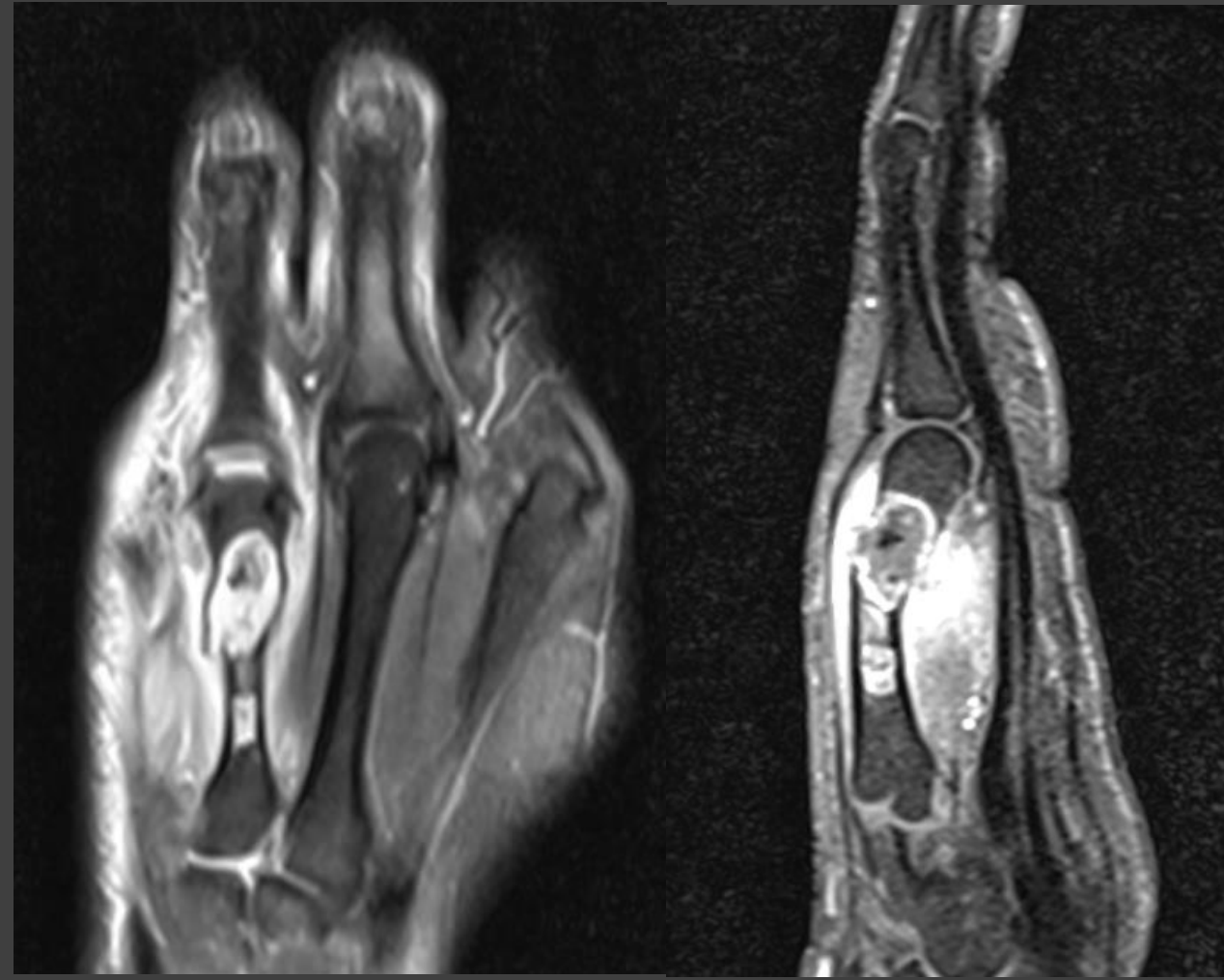
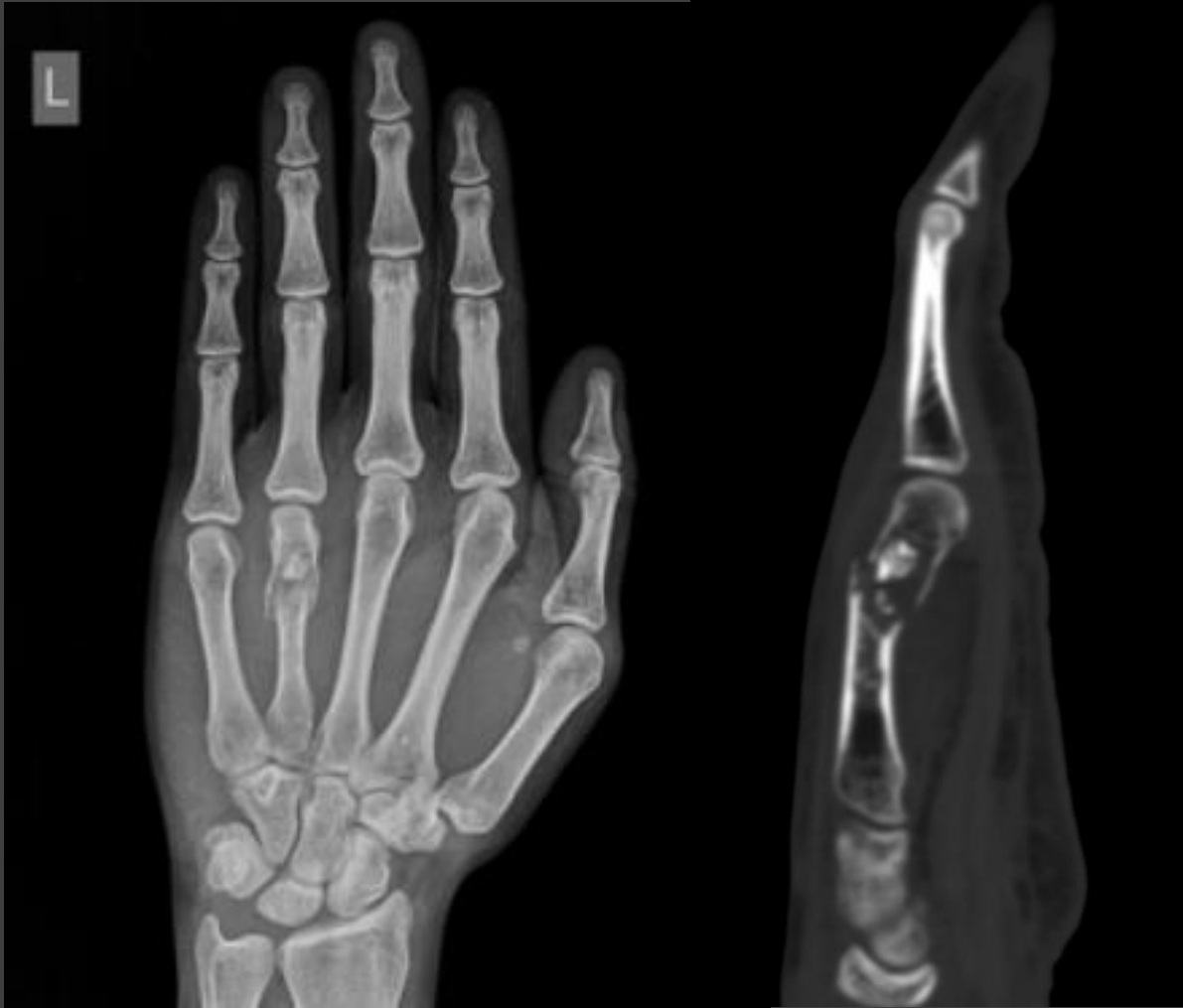[@indiamsk](https://www.instagram.com/indiamsk)
[@IJMSR](https://www.instagram.com/ijmsr)



[@MSKSocietyIndia](https://twitter.com/MSKSocietyIndia)
[@IJMSR MSSIndia](https://twitter.com/IJMSR_MSSIndia)



30-year-old with complaints of pain after fall



30-year-old with complaints of pain after fall

What is the most likely diagnosis ?

- A. Tubercular dactylitis.
- B. Metastasis.
- C. Enchondroma with pathological fracture.
- D. Low grade chondrosarcoma.

Q . Do you think it's a single lesion or there are two lesions with intervening normal marrow in between. ?

