

MI-COD

MSS INDIA- Case Of the Day



04/11/2024

Case contributor – Dr. Sagar Tomar

Musculoskeletal Society of India (MSS) &
Indian Journal of Musculoskeletal Radiology
(IJMSR), the official publication of MSS India

For MICOD case archives visit <https://www.indianmss.org/>
Check out our latest publication at <https://mss-ijmsr.com/>

Authentic source of MSK Radiology

For daily MSK radiology updates & great educational
contents, follow us on



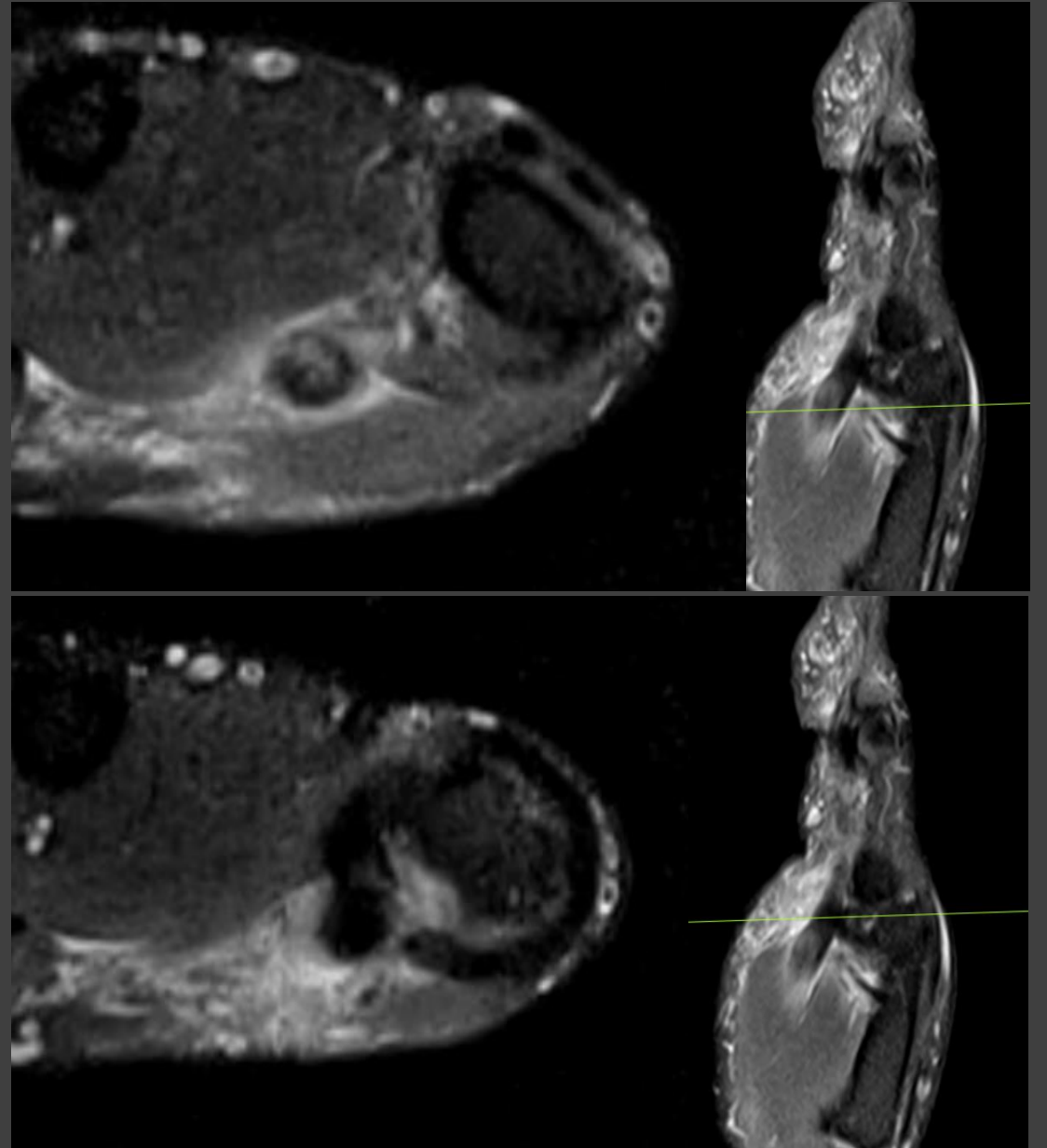
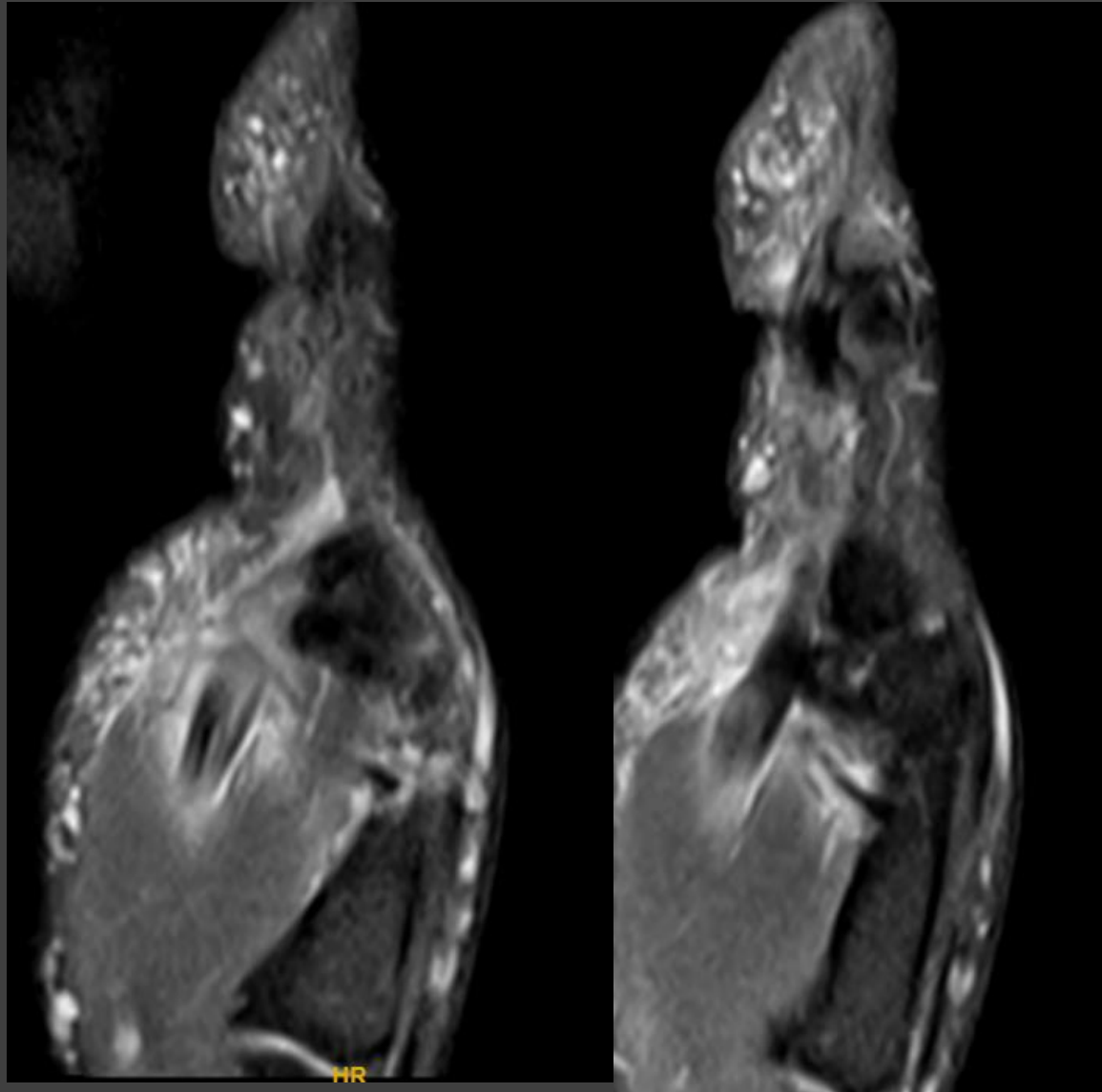
[@indiamsk](https://www.instagram.com/indiamsk)
[@IJMSR](https://www.instagram.com/ijmsr)



[@MSKSocietyIndia](https://twitter.com/MSKSocietyIndia)
[@IJMSR MSSIndia](https://twitter.com/IJMSR_MSSIndia)



Images



50-year-old with pain and inability to flex thumb for 1-week. No obvious trauma. However, the patient did say it all started with bowling over an extended weekend holiday.

Which of the following statements is true?

- A. Focal tendinosis of the FPL with intrasubstance striations in Zone III.
- B. Edematous A1 pulley.
- C. Tenosynovitis.
- D. Some degree of A1 pulley thickening along the ulnar aspect.
- E. All the above.

