

MI-COD

MSS INDIA- Case Of the Day



01/11/2024

Case contributor – Dr. Sagar Tomar

Musculoskeletal Society of India (MSS) &
Indian Journal of Musculoskeletal Radiology
(IJMSR), the official publication of MSS India

For MICOD case archives visit <https://www.indianmss.org/>

Check out our latest publication at <https://mss-ijmsr.com/>

Authentic source of MSK Radiology

For daily MSK radiology updates & great educational
contents, follow us on



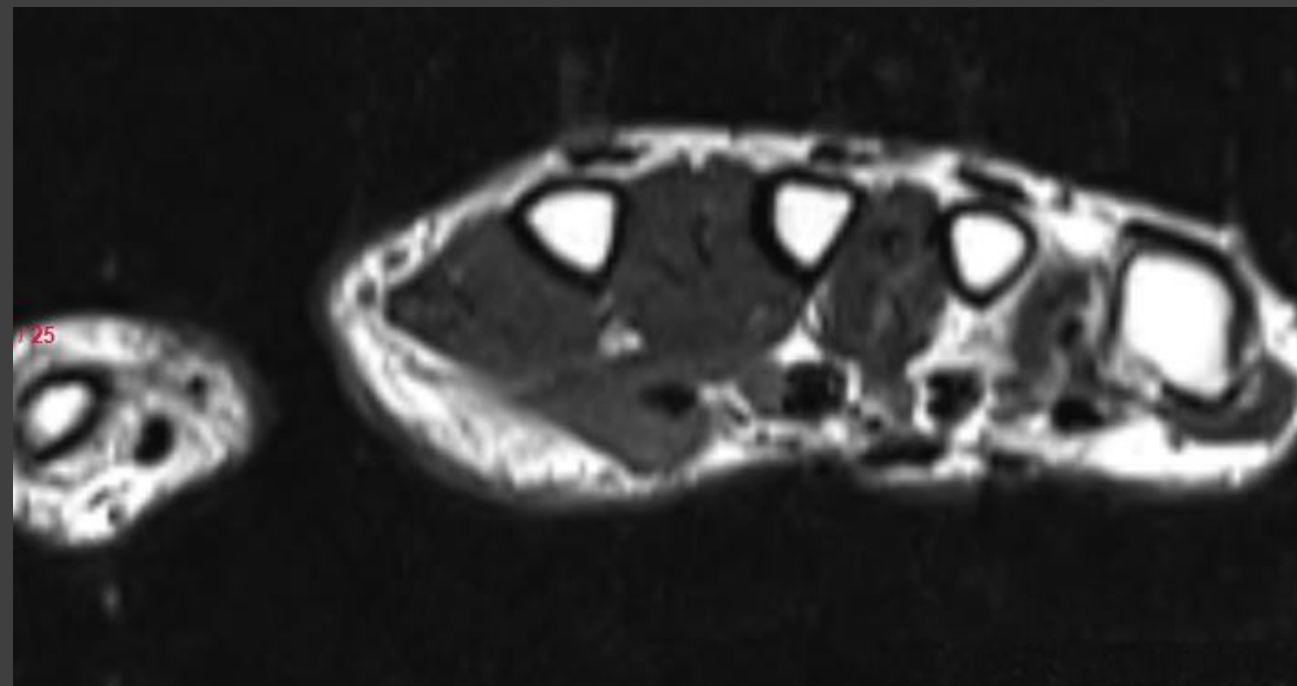
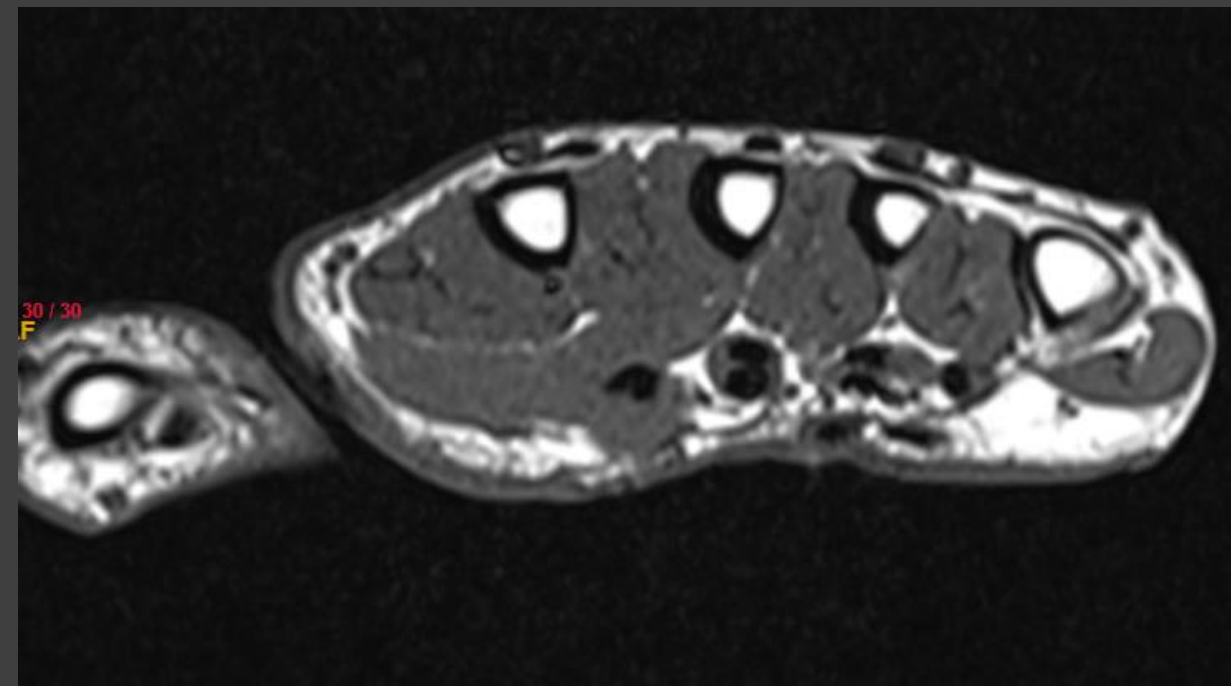
[@indiamsk](https://www.instagram.com/indiamsk)
[@IJMSR](https://www.instagram.com/ijmsr)



[@MSKSocietyIndia](https://twitter.com/MSKSocietyIndia)
[@IJMSR MSSIndia](https://twitter.com/IJMSR_MSSIndia)



Images



Question

For the given case, which of the following structures/ structures will produce flexor contracture of both the MCP and PIP joints?

- A. Peritendinous cord.
- B. Natatory cord.
- C. Spiral Cord.
- D. Lateral cord.
- E. Central cord.