

MI-COD

MSS INDIA- Case Of the Day



29/10/2024

Case contributor – Dr. Sagar Tomar

Musculoskeletal Society of India (MSS) &
Indian Journal of Musculoskeletal Radiology
(IJMSR), the official publication of MSS India

For MICOD case archives visit <https://www.indianmss.org/>

Check out our latest publication at <https://mss-ijmsr.com/>

Authentic source of MSK Radiology

For daily MSK radiology updates & great educational
contents, follow us on



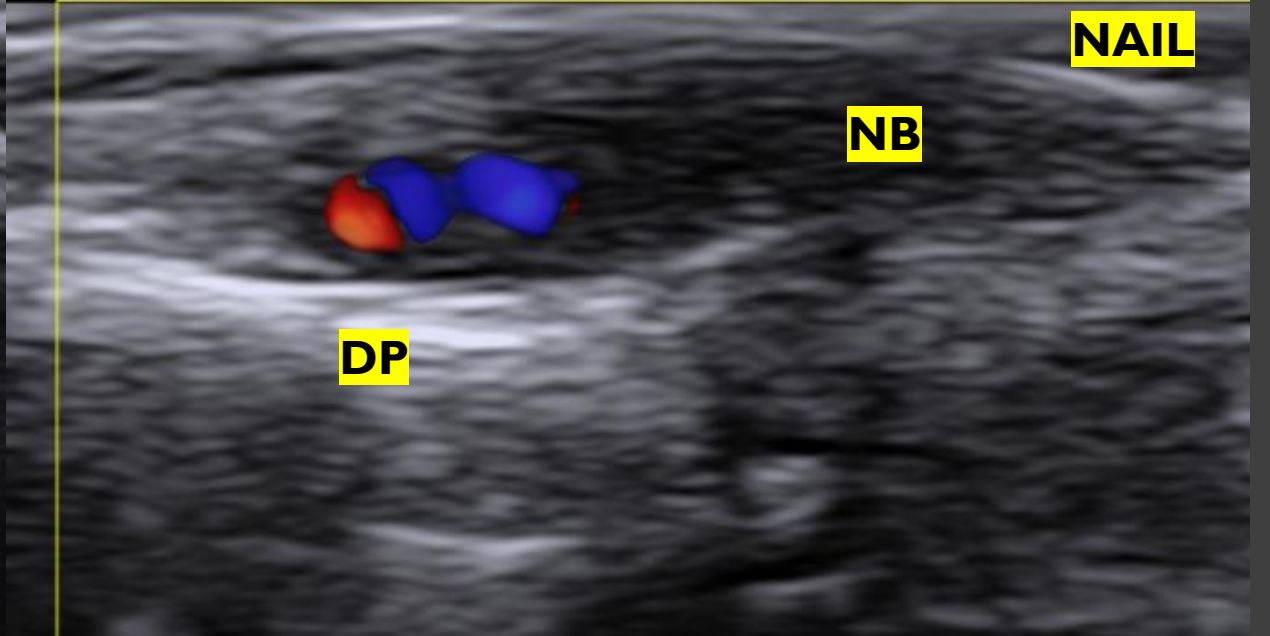
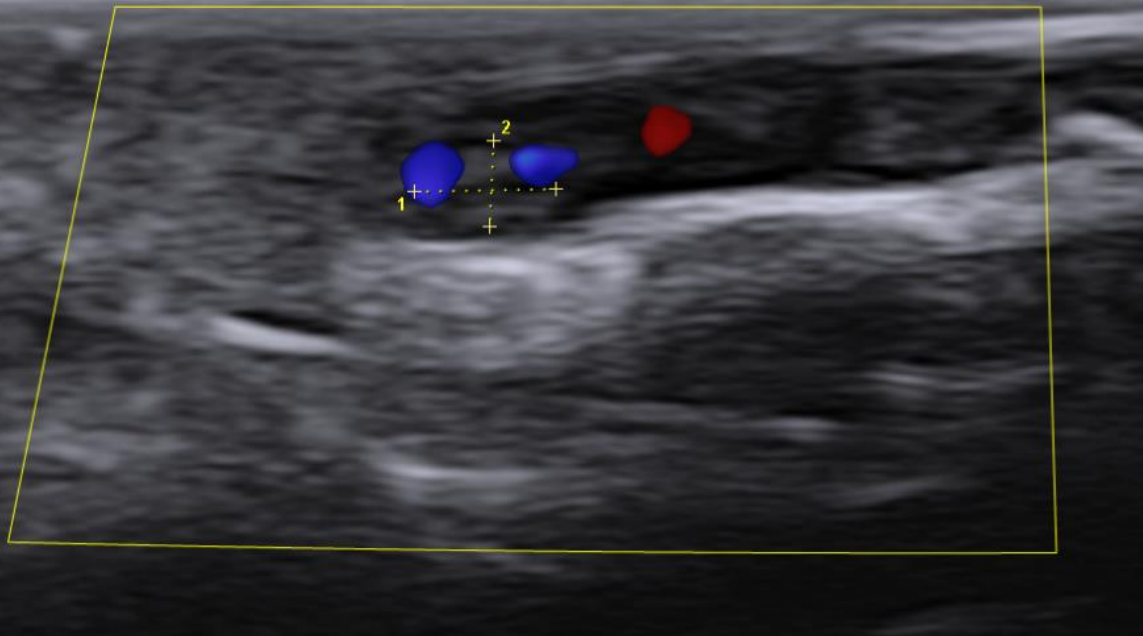
[@indiamsk](https://www.instagram.com/indiamsk)
[@IJMSR](https://www.instagram.com/ijmsr)



[@MSKSocietyIndia](https://twitter.com/MSKSocietyIndia)
[@IJMSR MSSIndia](https://twitter.com/IJMSR_MSSIndia)



Images



	+	▶
1	D	0.18 cm
2	D	0.11 cm

Question

Which of the following is an incorrect statement regarding the given lesion?

- A. This lesion is a hamartoma rather than a true tumor.
- B. The etiology of these lesions can be familial.
- C. These lesions are richly vascularized, appearing as ovoid blush on contrast MRI.
- D. Surgery is curative with no chance of recurrence.