

# MI-COD

MSS INDIA- Case Of the Day



28/10/2024

Case contributor

Dr. Chidambaranathan & Dr. Swathi Kiran

Musculoskeletal Society of India (MSS) &  
Indian Journal of Musculoskeletal Radiology  
(IJMSR), the official publication of MSS India

For MICOD case archives visit <https://www.indianmss.org/>

Check out our latest publication at <https://mss-ijmsr.com/>

*Authentic source of MSK Radiology*

For daily MSK radiology updates & great educational  
contents, follow us on



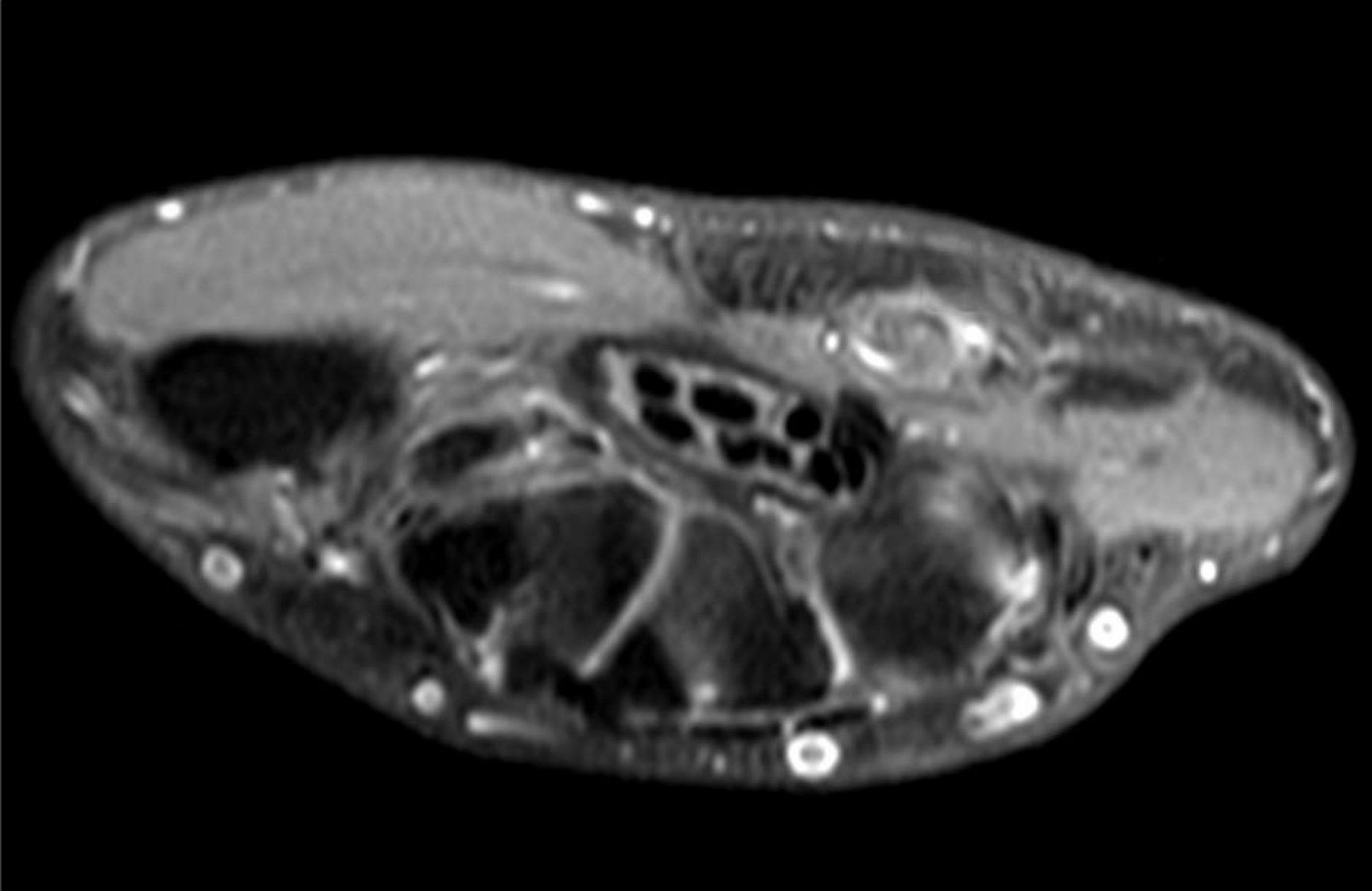
[@indiamsk](https://www.instagram.com/indiamsk)  
[@IJMSR](https://www.instagram.com/ijmsr)



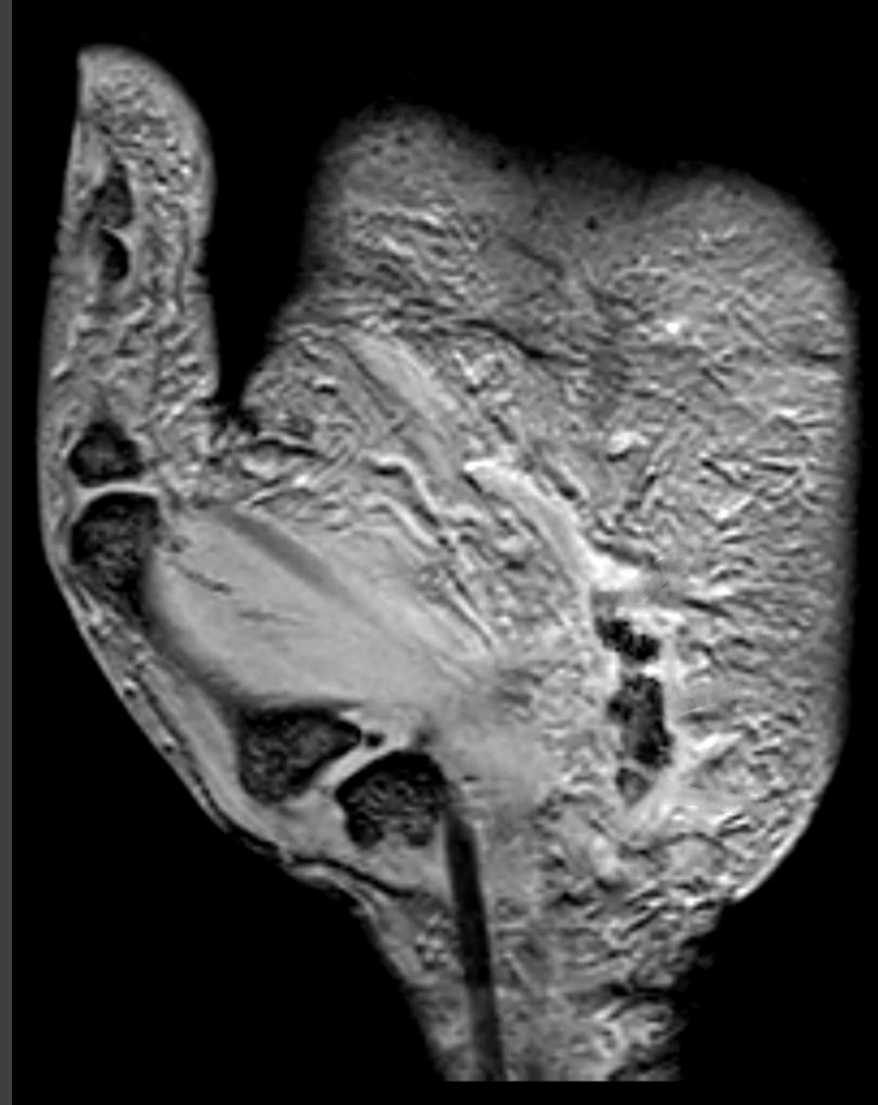
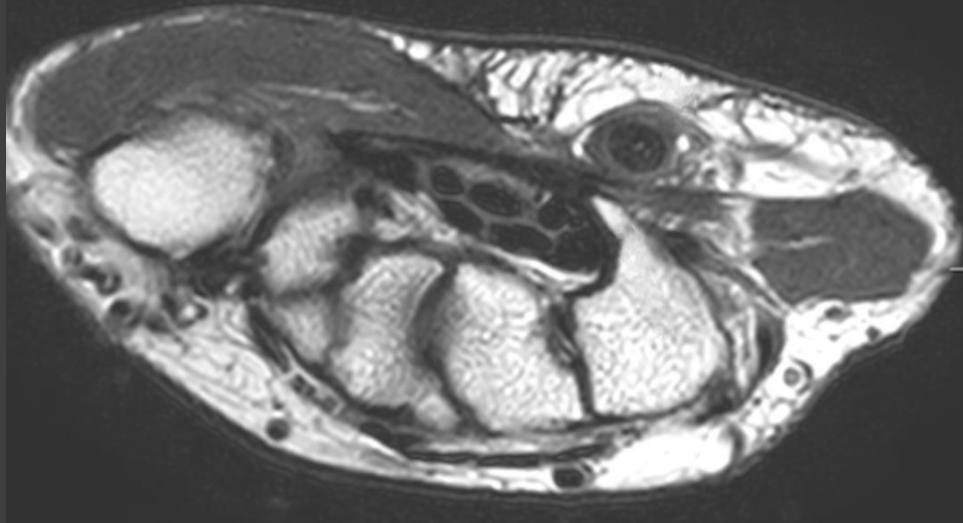
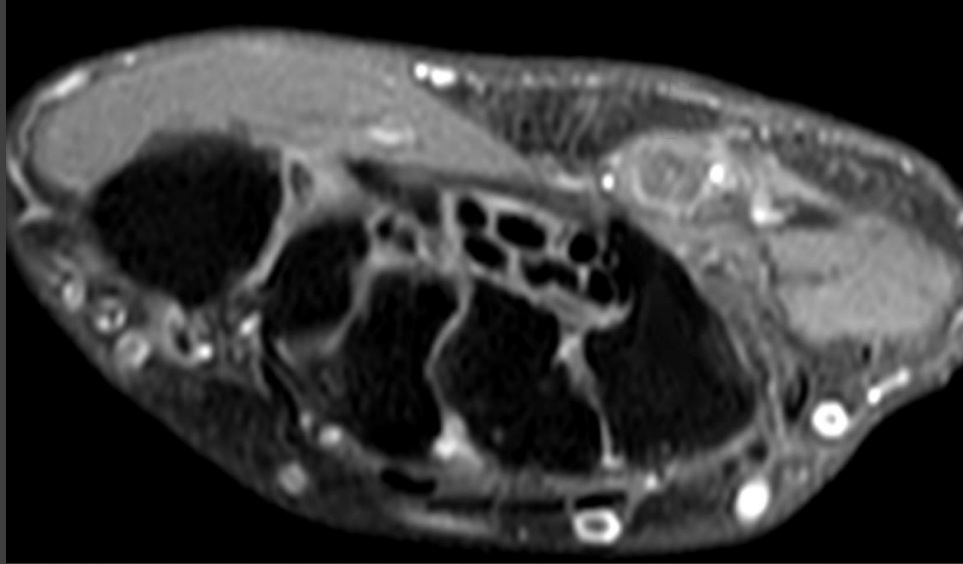
[@MSKSocietyIndia](https://twitter.com/MSKSocietyIndia)  
[@IJMSR MSSIndia](https://twitter.com/IJMSR_MSSIndia)



*70-year-old gentleman, tennis player with history of pain and nodular swelling in left hand for 2 weeks*



*70-year-old gentleman, tennis player with history of pain and nodular swelling in left hand for 2 weeks*



*How do you proceed further? Any additional sequence to clinch the diagnosis?*