

MI-COD

MSS INDIA- Case Of the Day



25/10/2024

Case contributor – Dr (Prof). Rajesh Botchu
and colleagues

Musculoskeletal Society of India (MSS) &
Indian Journal of Musculoskeletal Radiology
(IJMSR), the official publication of MSS India

For MICOD case archives visit <https://www.indianmss.org/>
Check out our latest publication at <https://mss-ijmsr.com/>

Authentic source of MSK Radiology

For daily MSK radiology updates & great educational
contents, follow us on



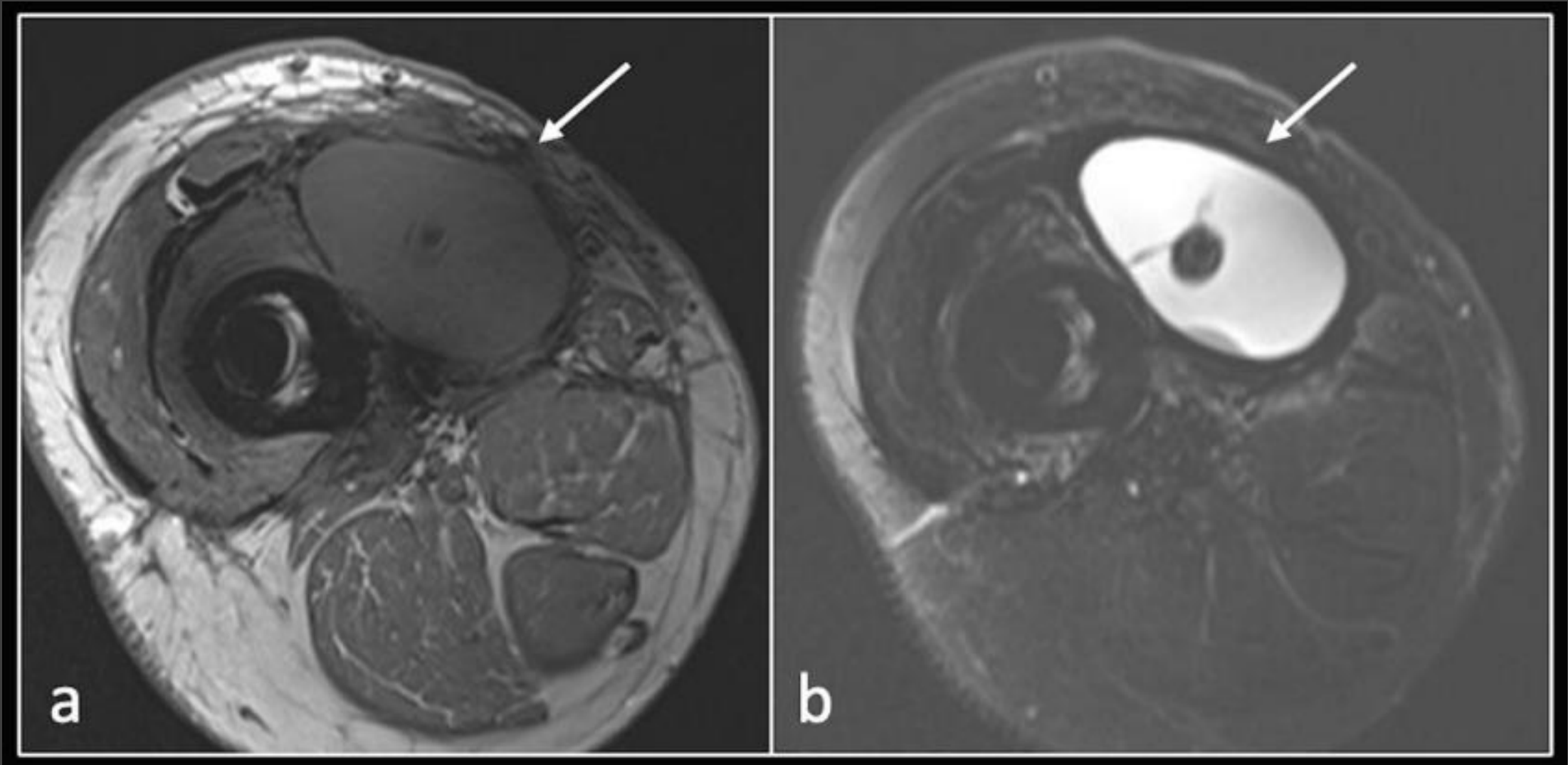
[@indiamsk](https://www.instagram.com/indiamsk)
[@IJMSR](https://www.instagram.com/ijmsr)



[@MSKSocietyIndia](https://twitter.com/MSKSocietyIndia)
[@IJMSR MSSIndia](https://twitter.com/IJMSR_MSSIndia)



Axial T1 (a) and STIR (b) MRI images of right thigh



Findings and possibilities please..