

MI-COD

MSS INDIA- Case Of the Day



16/10/2024


Case contributor- Dr. Umamaheshwar reddy

Musculoskeletal Society of India (MSS) &
Indian Journal of Musculoskeletal Radiology
(IJMSR), the official publication of MSS India

For MICOD case archives visit
<https://www.indianmss.org/>

*Authentic source of MSK
Radiology*

For daily MSK radiology updates, follow us on



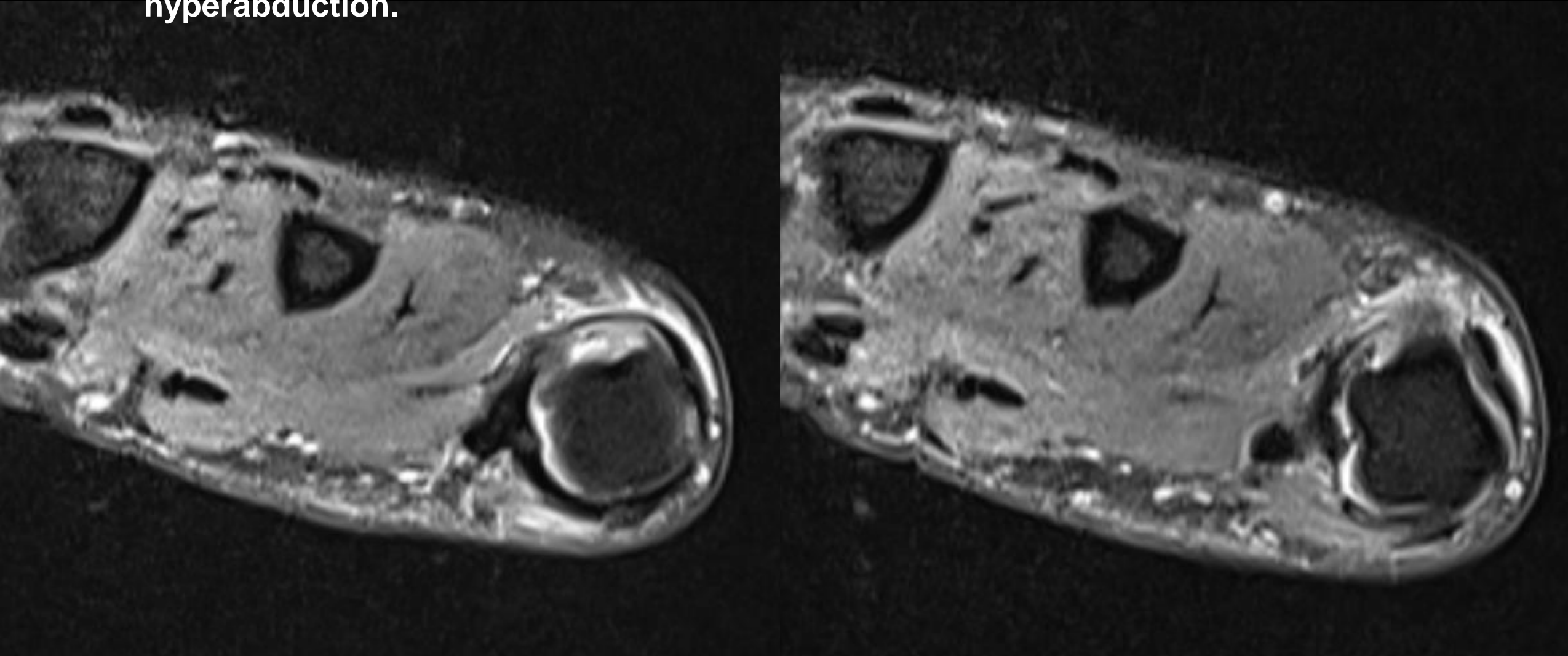
@MSKSocietyIndia

@indiask

@IJMSR_MSSIndia

@IJMSR

- 37 years old woman with pain in the thumb and limited flexion following hyperabduction.



➤ Why is it important to diagnose and treat promptly?

➤ Name analogous lesions if any.

