

MI-COD

MSS INDIA- Case Of the Day



15/10/2024

Case contributor- Dr. Dharmendra k.
Singh

Musculoskeletal Society of India (MSS) &
Indian Journal of Musculoskeletal Radiology
(IJMSR), the official publication of MSS India

For MICOD case archives visit
<https://www.indianmss.org/>

*Authentic source of MSK
Radiology*

For daily MSK radiology updates, follow us on



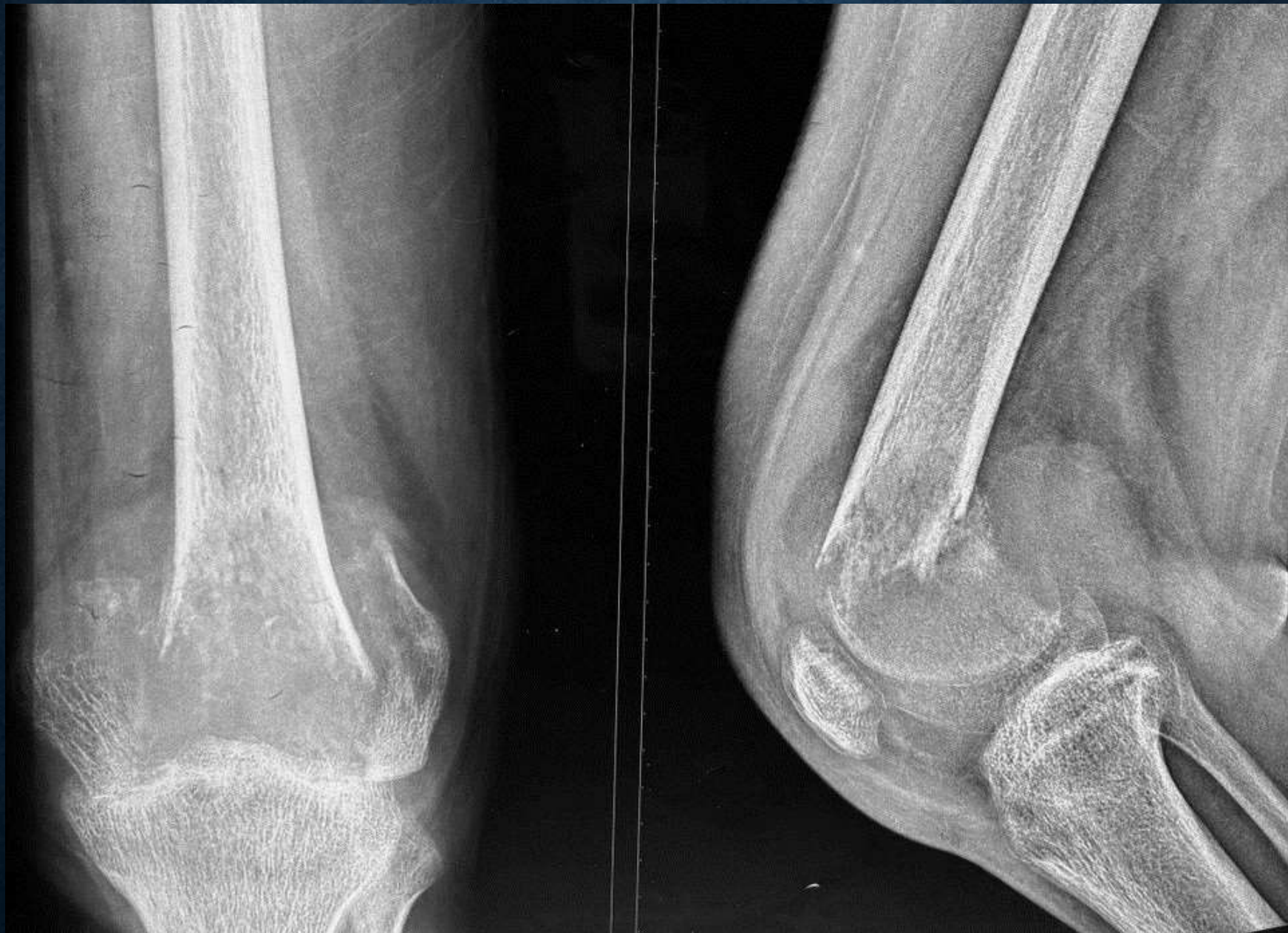@MSKSocietyIn
dia

@indiams
k

@IJMSR_MSSin

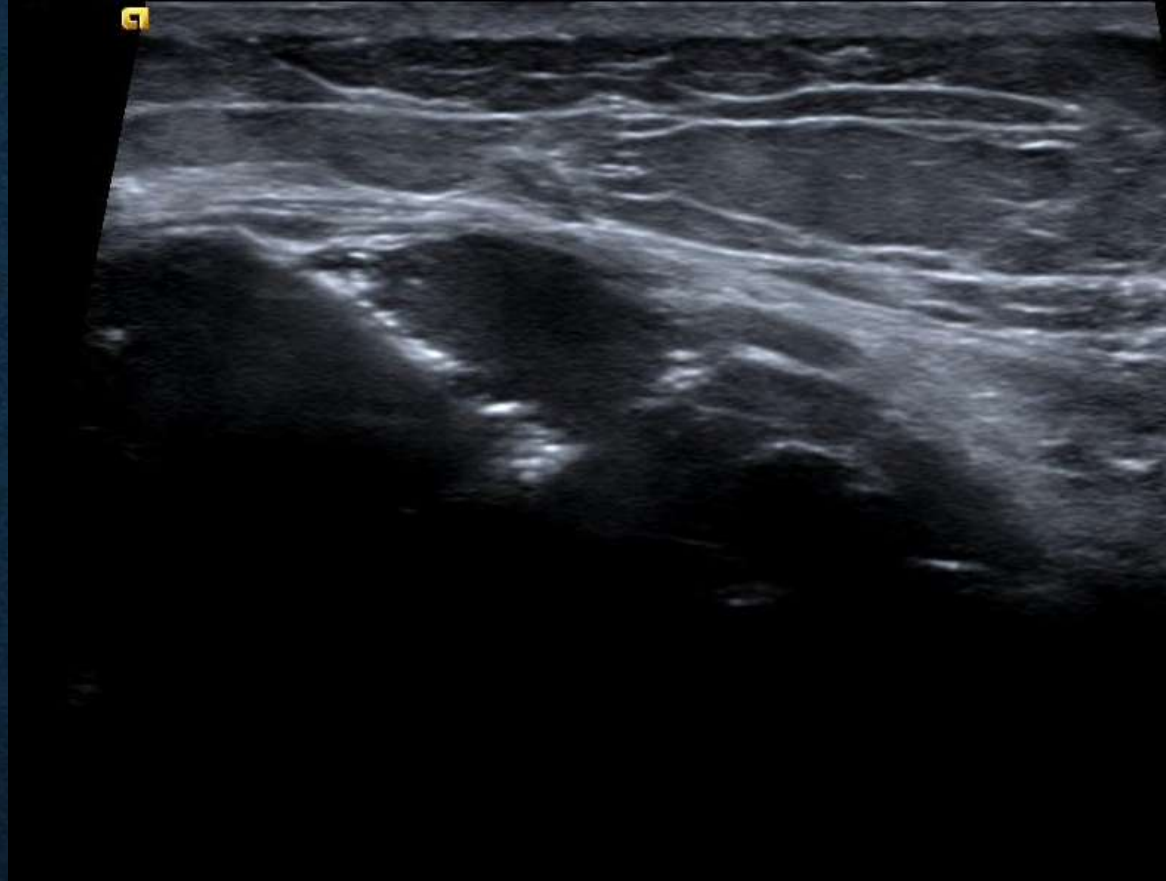
@IJMSR

- 19 year male complains of pain and swelling in left knee for 7 months.
- It is progressive in nature.
- There is no history of trauma.

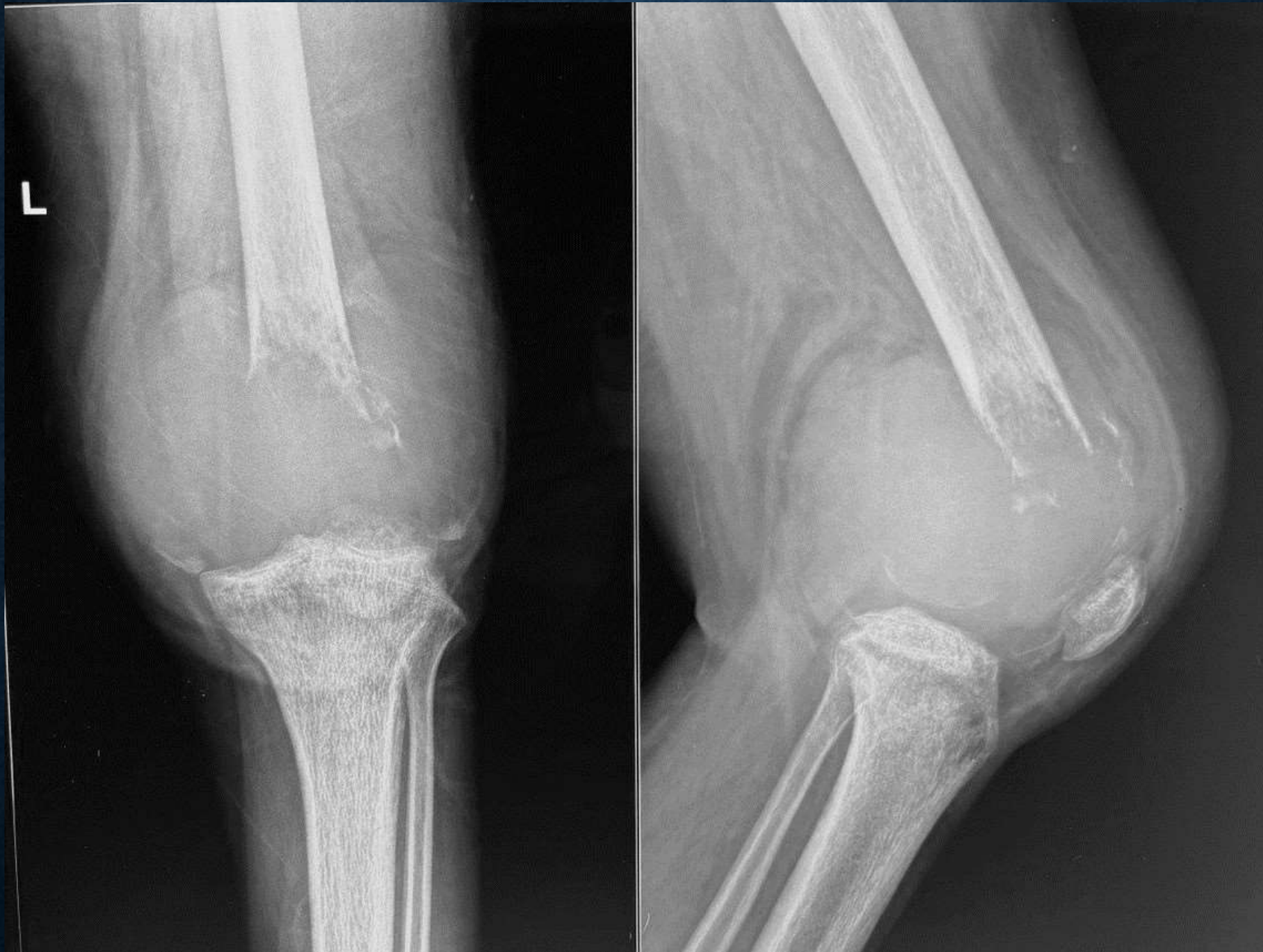

Jan 2024

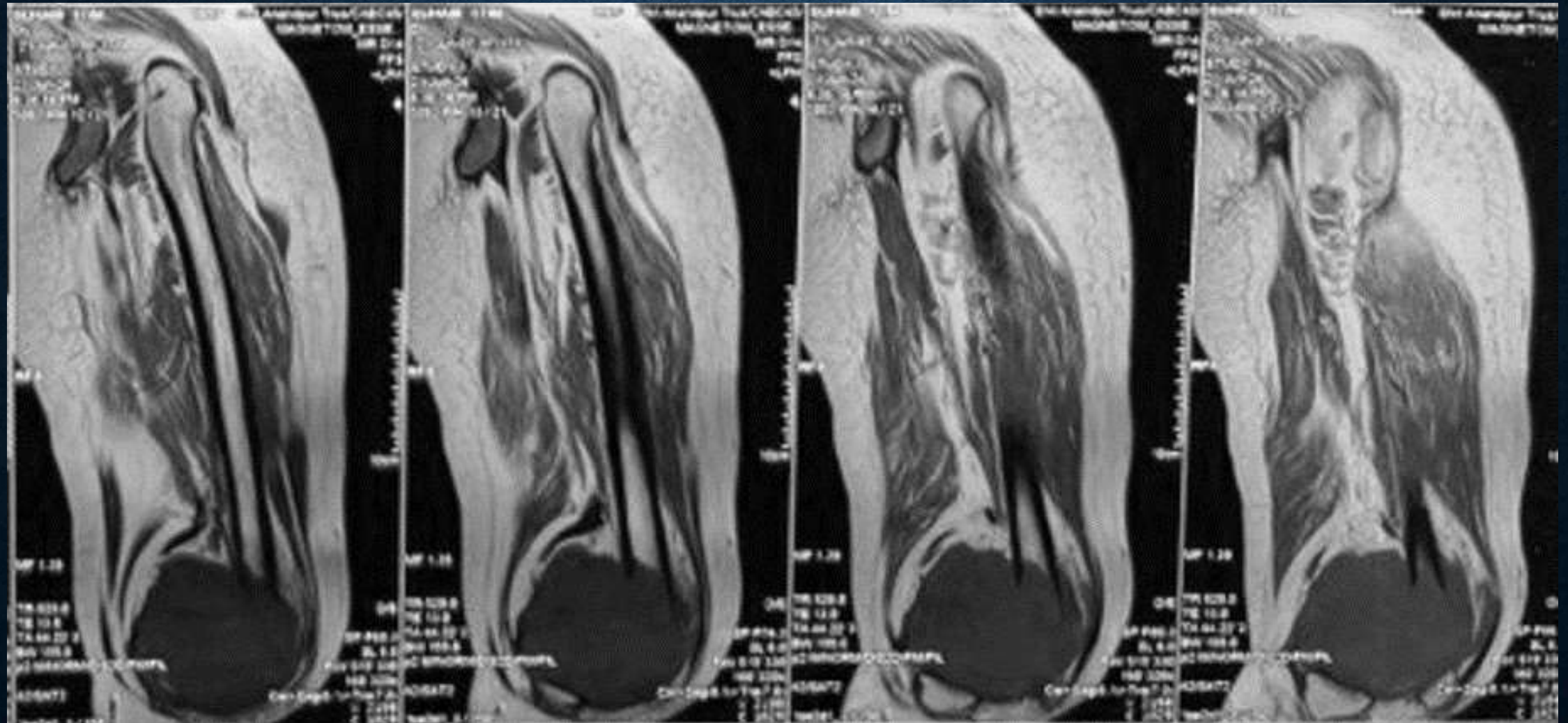
US-guided Biopsy was performed



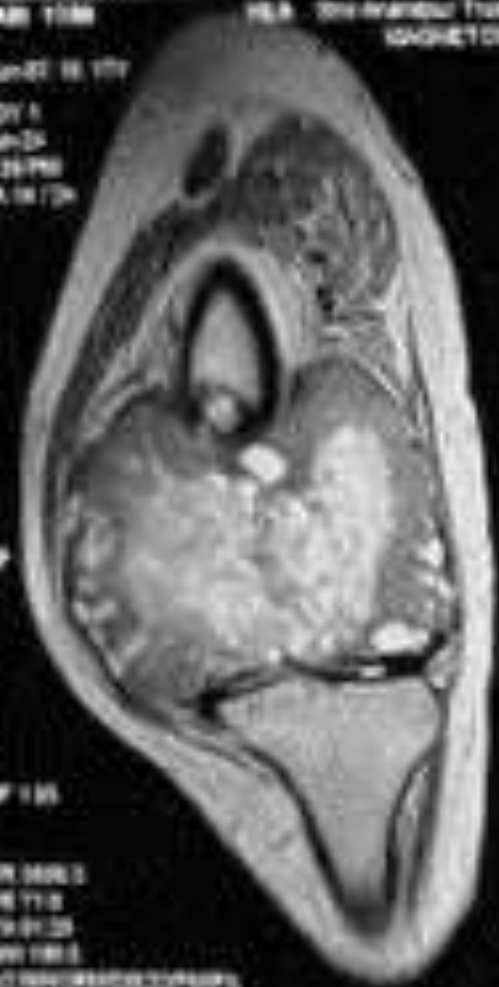
HPE: Giant cell tumor. Patient was started Denosumab



Follow up Radiograph: June 2024

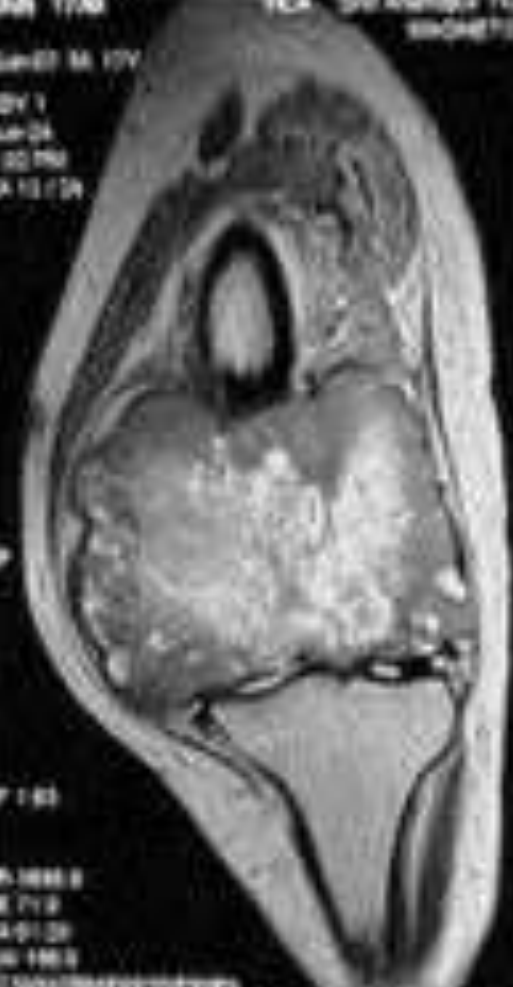

MR01_11/100
HSA - Sagittal T1W
15-Jan-24 16:17
STUDY 1
1-Jan-24
20:29:59
18A 18 73



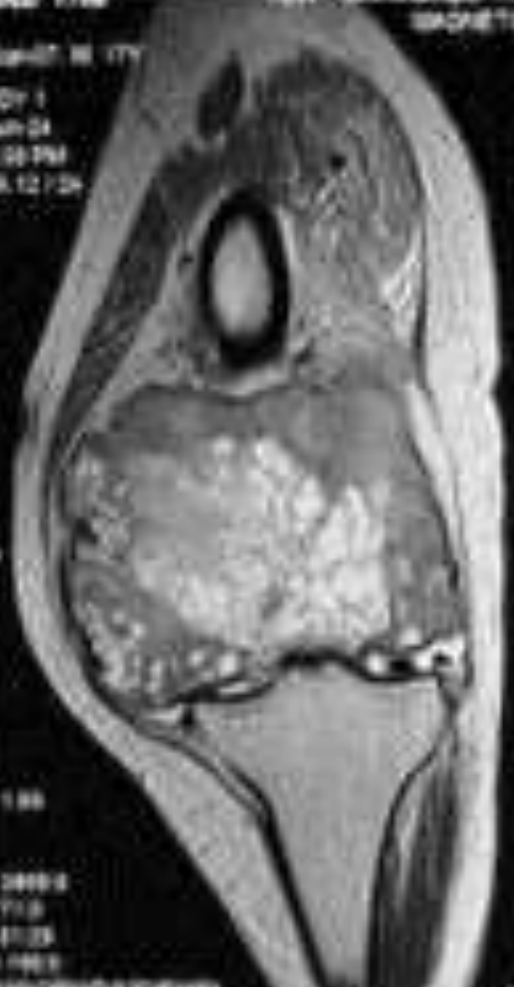MR 100
TR 300.0
TE 71.0
TA 01:20
SP 180.0
SL 4.00.0
FOV 200.000
AS/NAT
SFO: 2.5P1-1
S: 180
SAR 1.17

HSA - Sagittal T1W
15-Jan-24 16:17
STUDY 1
1-Jan-24
20:29:59
18A 18 73



MR 100
TR 300.0
TE 71.0
TA 01:20
SP 180.0
SL 4.00.0
FOV 200.000
AS/NAT
SFO: 2.5P1-1
S: 180
SAR 1.17

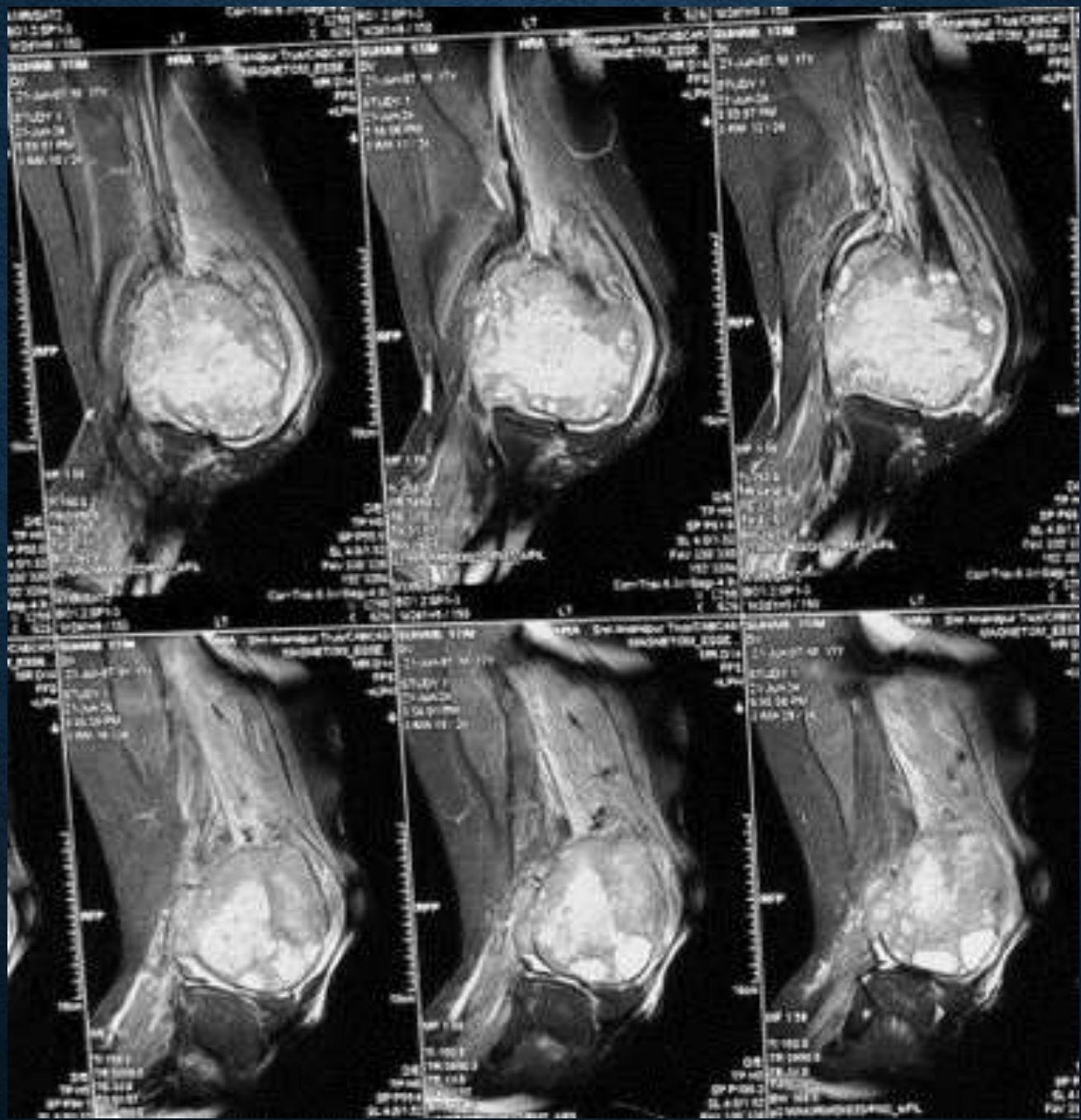
HSA - Sagittal T1W
15-Jan-24 16:17
STUDY 1
1-Jan-24
20:29:59
18A 18 73



MR 100
TR 300.0
TE 71.0
TA 01:20
SP 180.0
SL 4.00.0
FOV 200.000
AS/NAT
SFO: 2.5P1-1
S: 180
SAR 1.17

HSA - Sagittal T1W
15-Jan-24 16:17
STUDY 1
1-Jan-24
20:29:59
18A 18 73

MR 100
TR 300.0
TE 71.0
TA 01:20
SP 180.0
SL 4.00.0
FOV 200.000
AS/NAT
SFO: 2.5P1-1
S: 180
SAR 1.17



What went wrong

What's the diagnosis