

MI-COD

MSS INDIA- Case Of the Day



25/09/2024

Case contributor – Dr. Suvinay Saxena

Musculoskeletal Society of India (MSS) &
Indian Journal of Musculoskeletal Radiology
(IJMSR), the official publication of MSS India

For MICOD case archives visit
<https://www.indianmss.org/>

Authentic source of MSK Radiology

For daily MSK radiology updates, follow us on

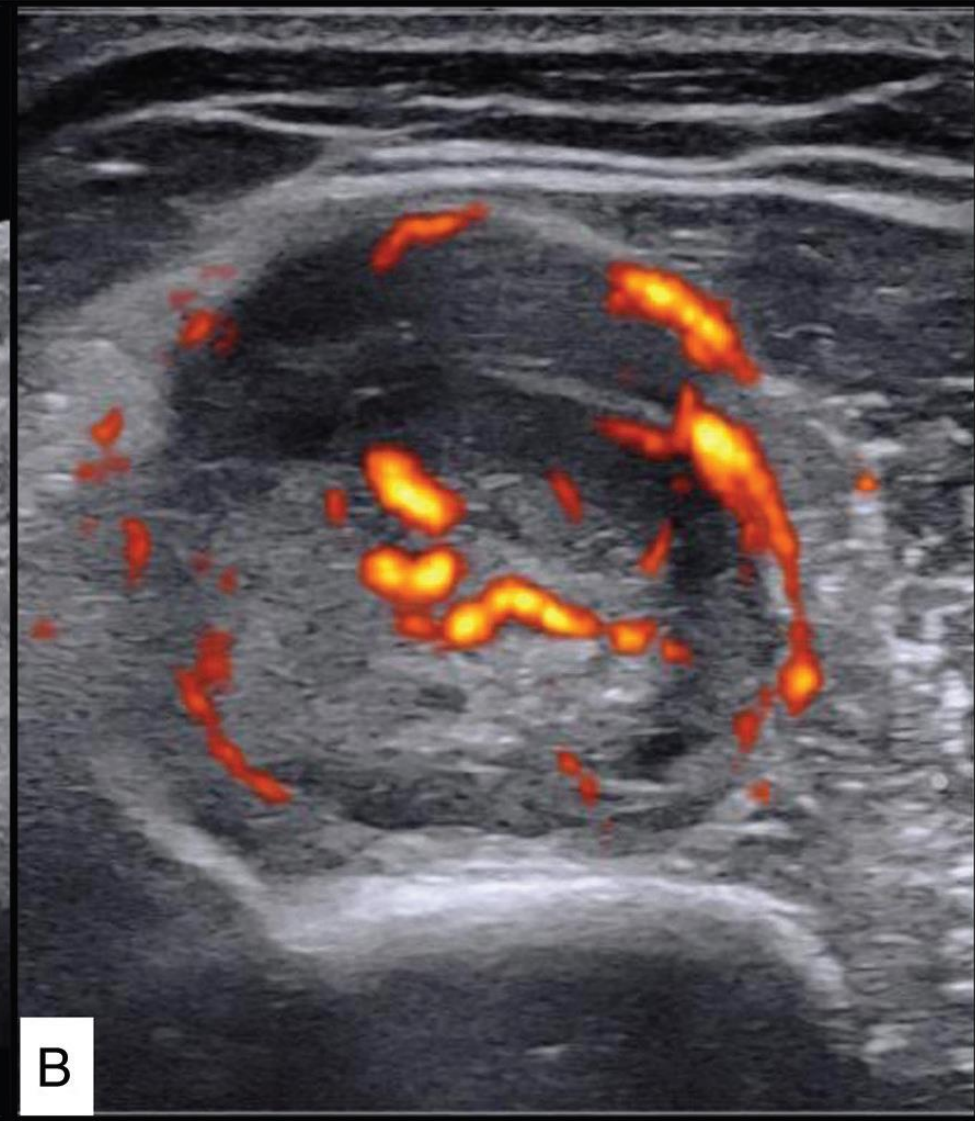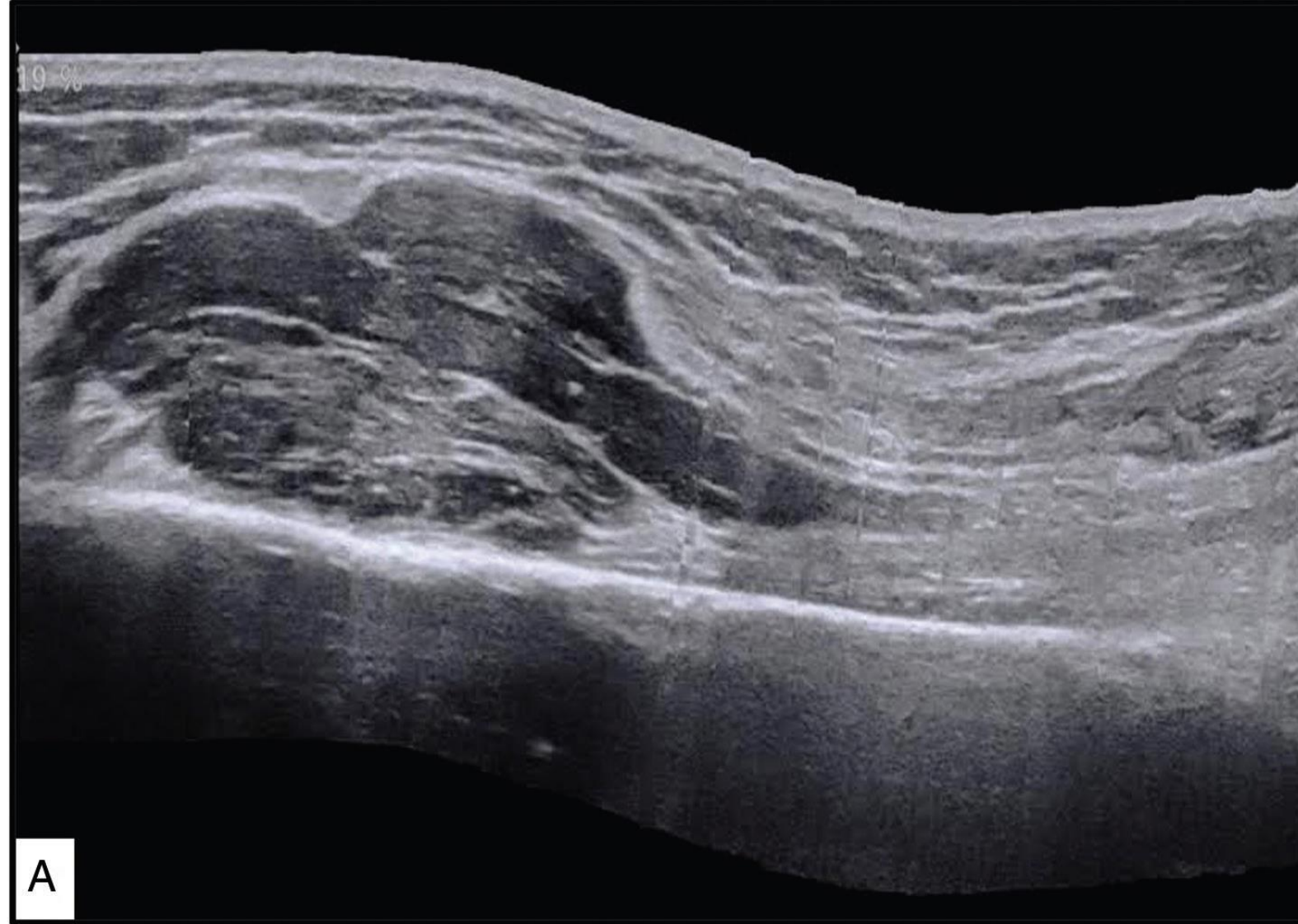


@MSKSocietyIndia
@IJMSR_MSSIndia



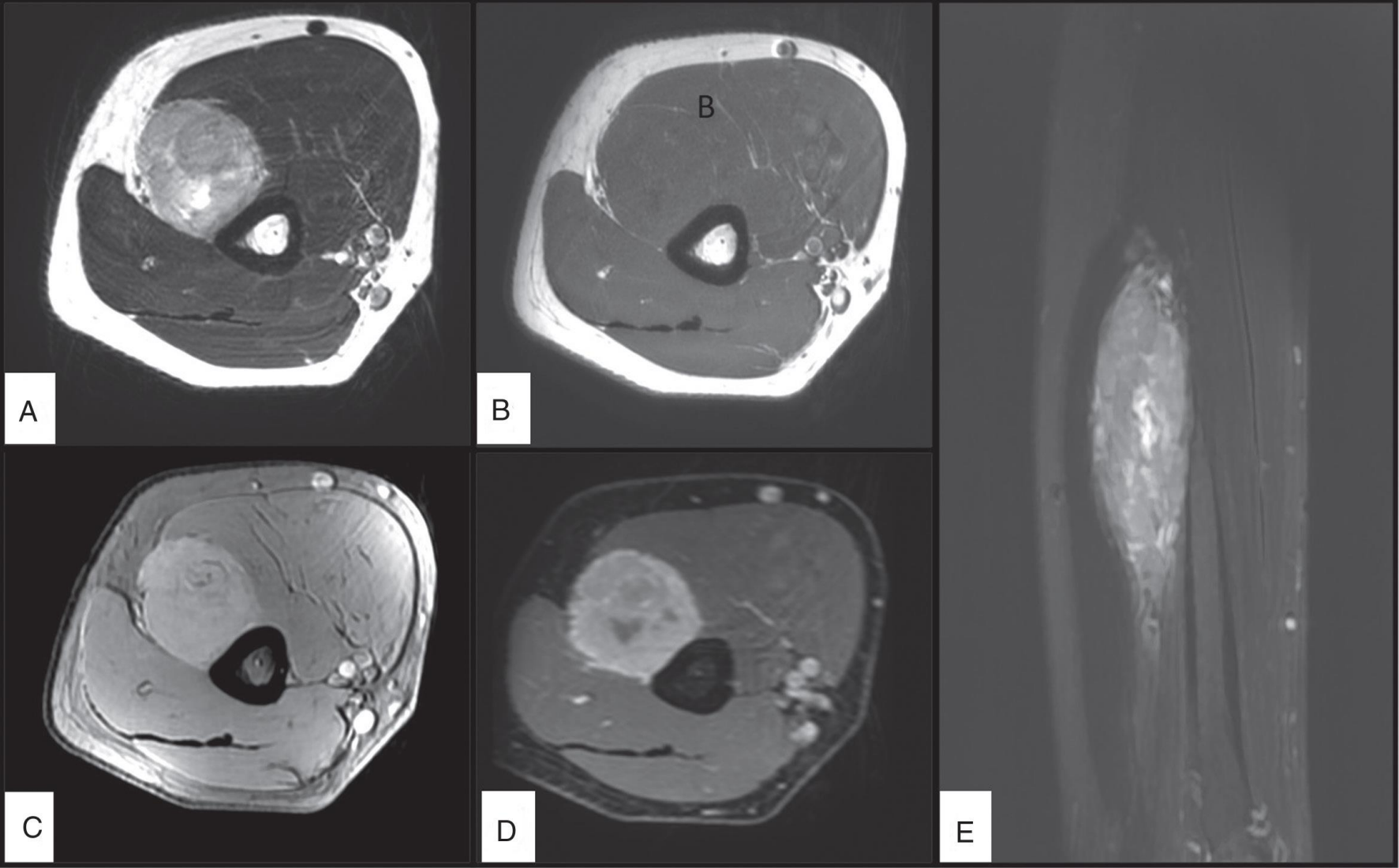
@indiamsk
@IJMSR

32-year-old gentleman with progressive weakness in the extension of the right hand for 3 months



Findings please..

32-year-old gentleman with progressive weakness in the extension of the right hand for 3 months



Findings please..