


# MI-COD

MSS INDIA- Case Of the Day



16/09/2024

Case contributor – Dr. Chaitali Parekh

Musculoskeletal Society of India (MSS) &  
Indian Journal of Musculoskeletal Radiology  
(IJMSR), the official publication of MSS India

For MICOD case archives visit  
<https://www.indianmss.org/>

*Authentic source of MSK Radiology*

For daily MSK radiology updates, follow us on

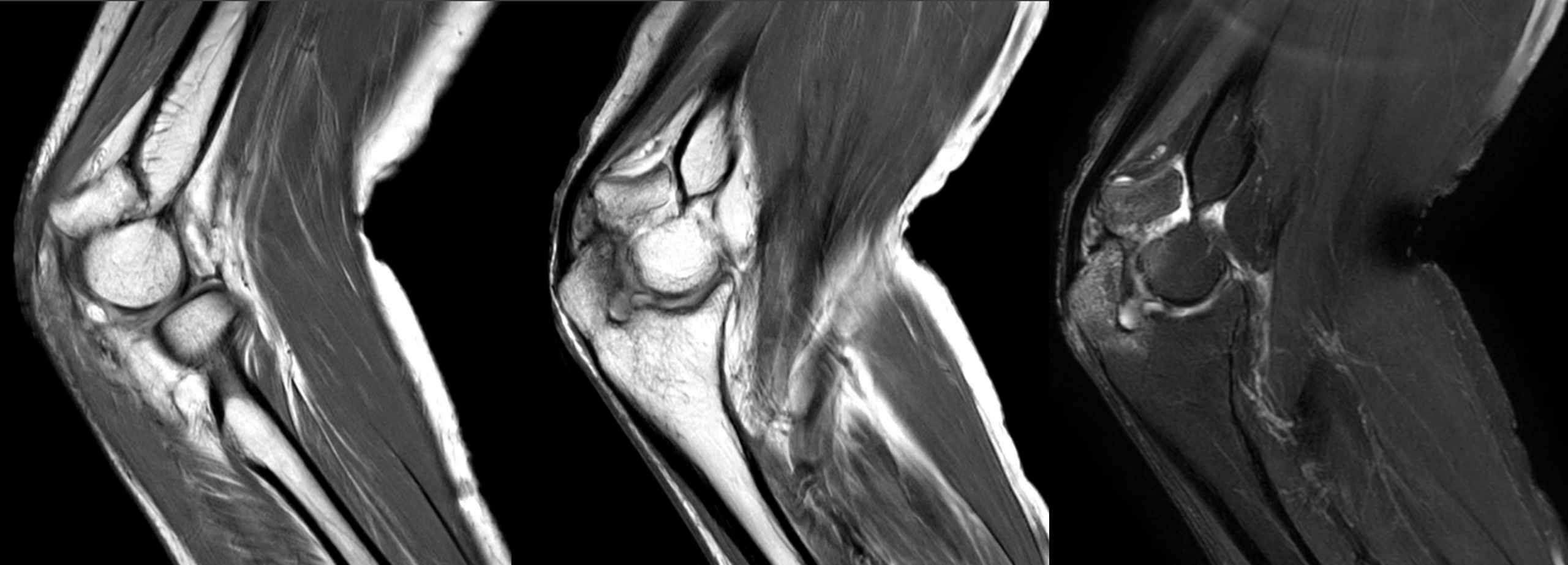


@MSKSocietyIndia  
@IJMSR\_MSSIndia



@indiamsk  
@IJMSR

Neglected trauma 6 months back, now unable to completely extend the elbow



Possibilities please?