


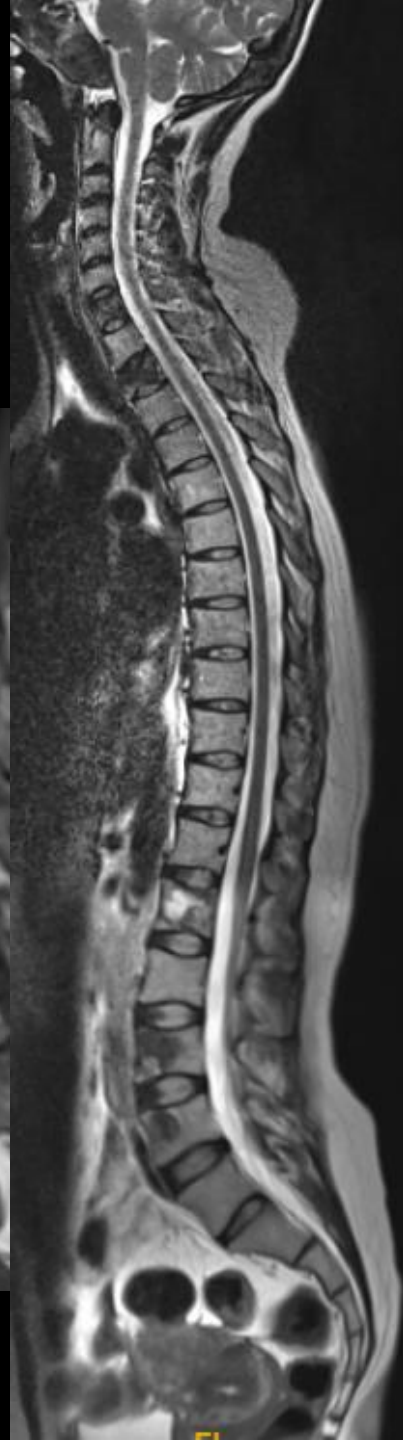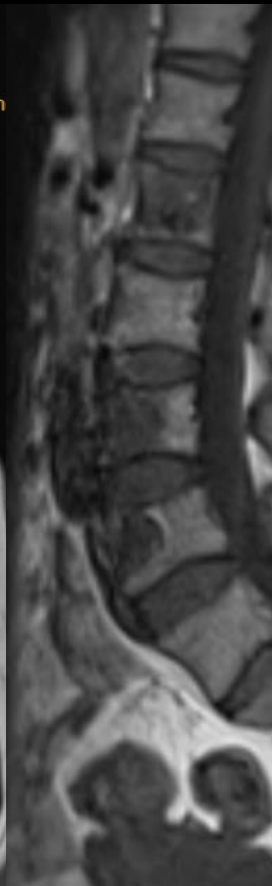
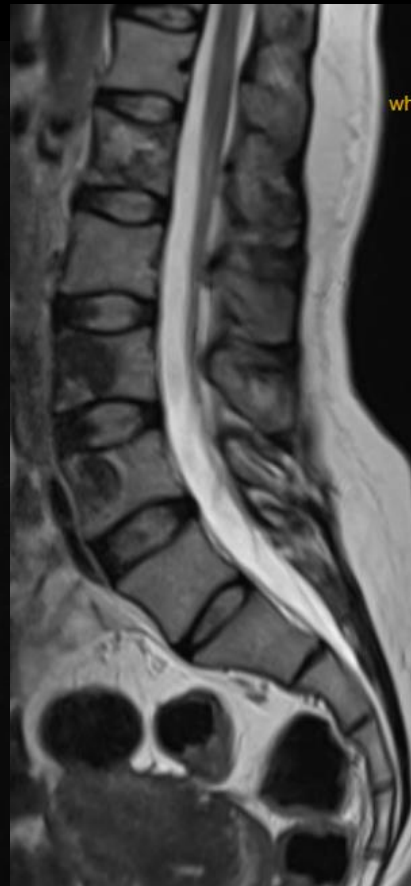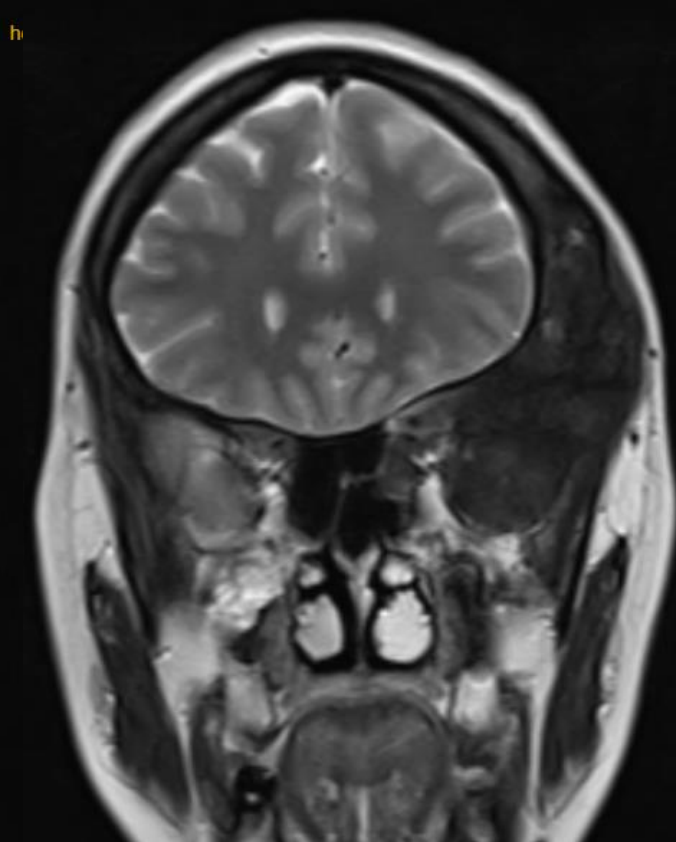
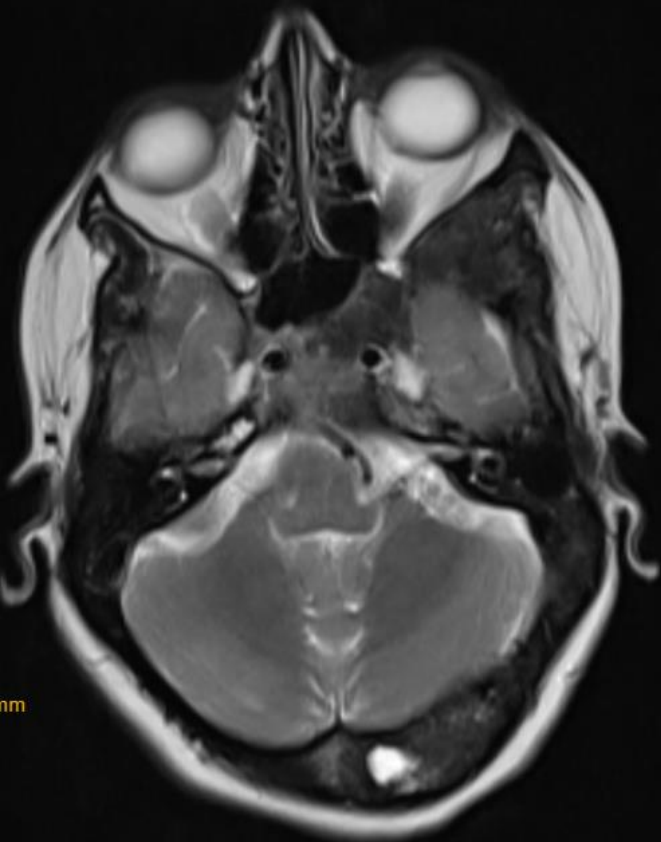MICOD –11/09/2024
Case contributor – Dr Sagar Tomar

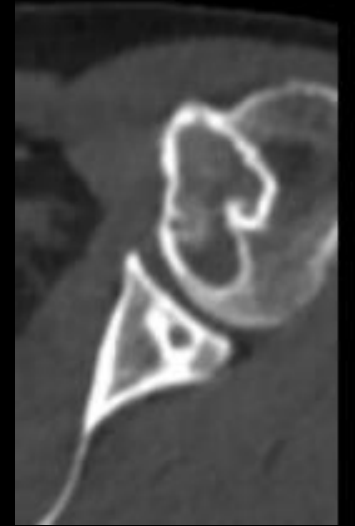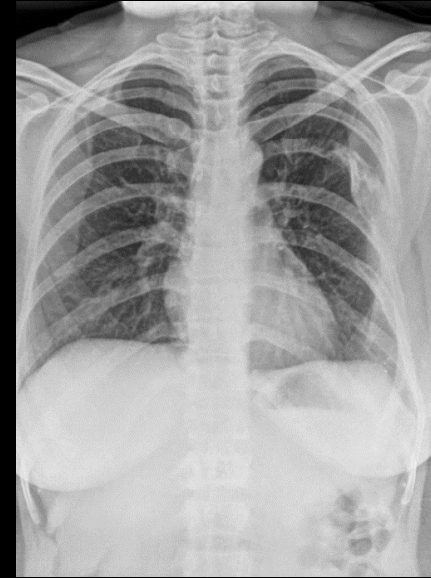
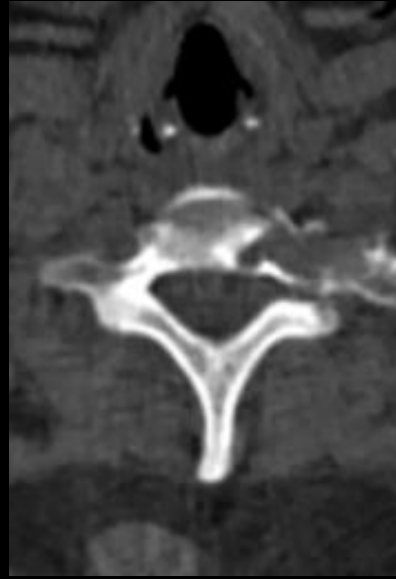
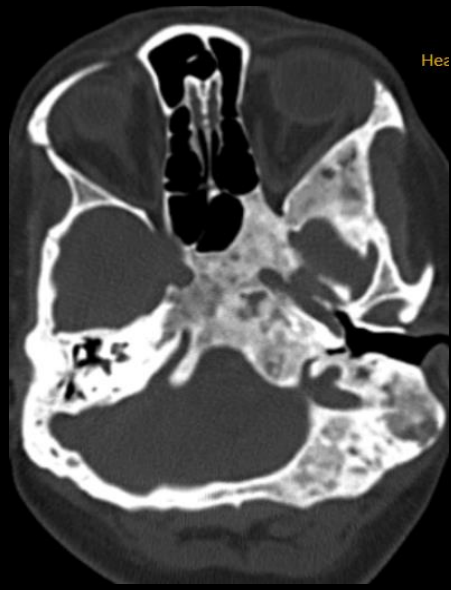
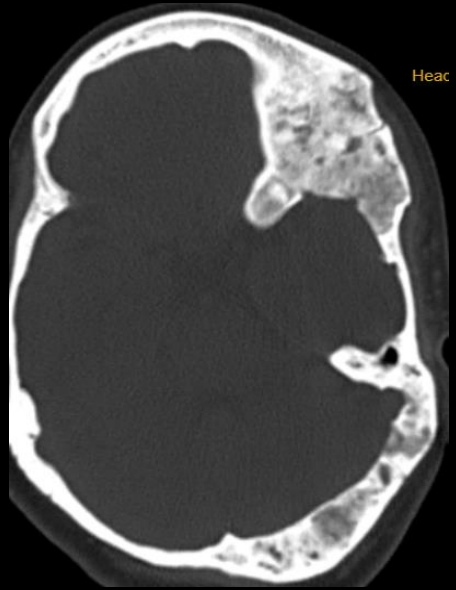
MI-COD

MSS INDIA- Case Of the Day



35 year old female with complaints of headache





Additional images
Diagnosis ?

A close-up, shallow depth-of-field photograph of a doctor in a white lab coat. The doctor's face is partially visible in the background, looking towards a computer monitor. In the foreground, a silver stethoscope with a grey tube lies on a wooden desk. The text "Diagnosis ?" is overlaid in white, sans-serif font on the right side of the stethoscope.

Diagnosis ?