

MICOD – 09/09/2024

Case contributor – Dr Sagar Tomar

# MI-COD

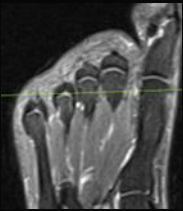MSS INDIA- Case Of the Day



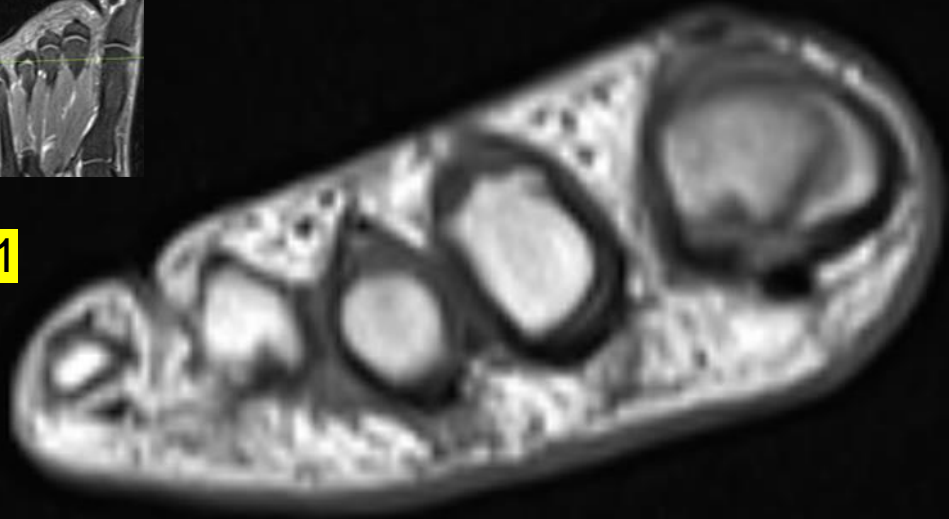
55 year old with forefoot pain

Diagnosis

Q- Why is diagnosis more obvious on image labelled 2.



1



2

