

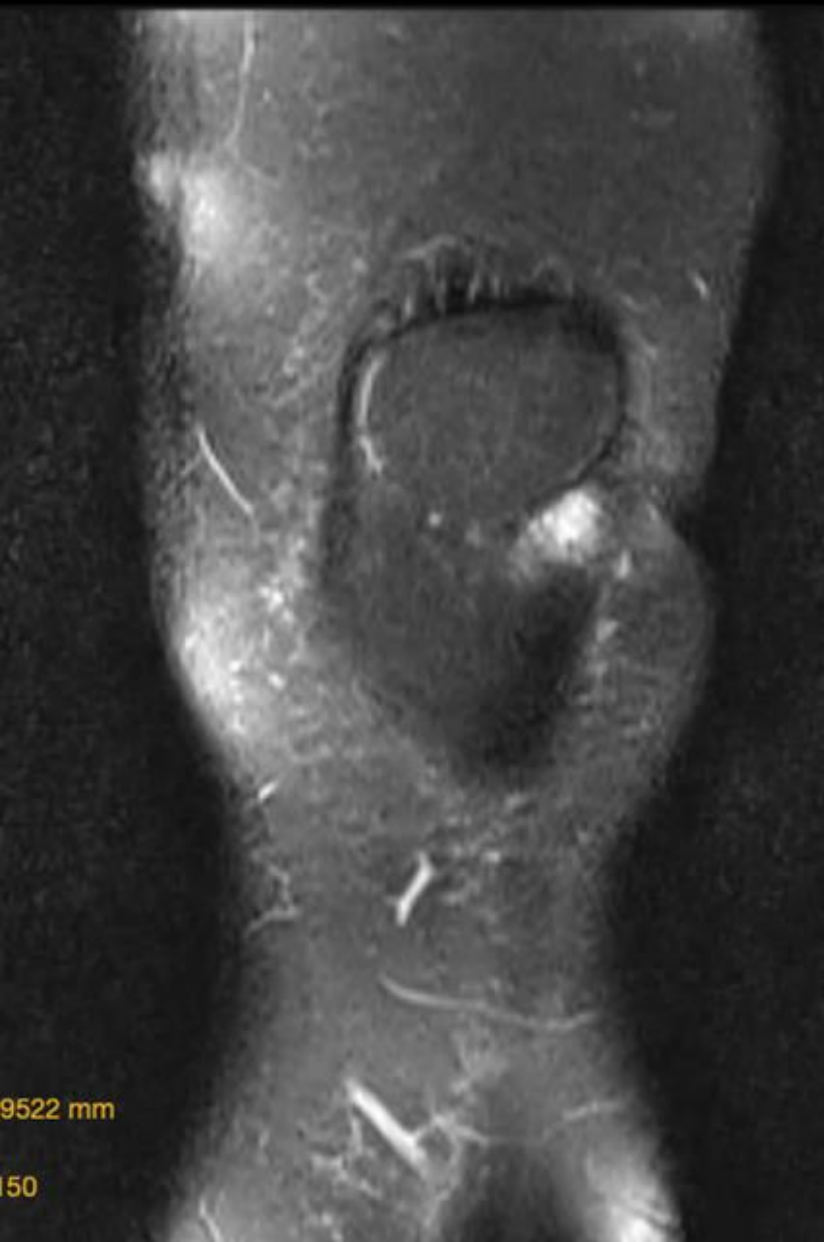
MICOD –06/09/2024

Case contributor – Dr Sagar Tomar

MI-COD

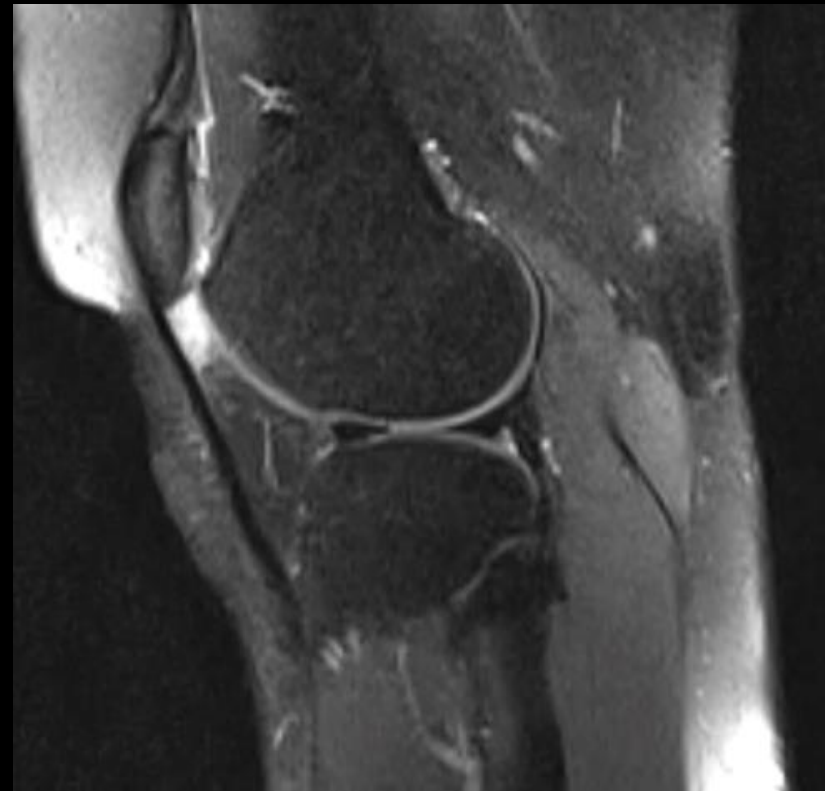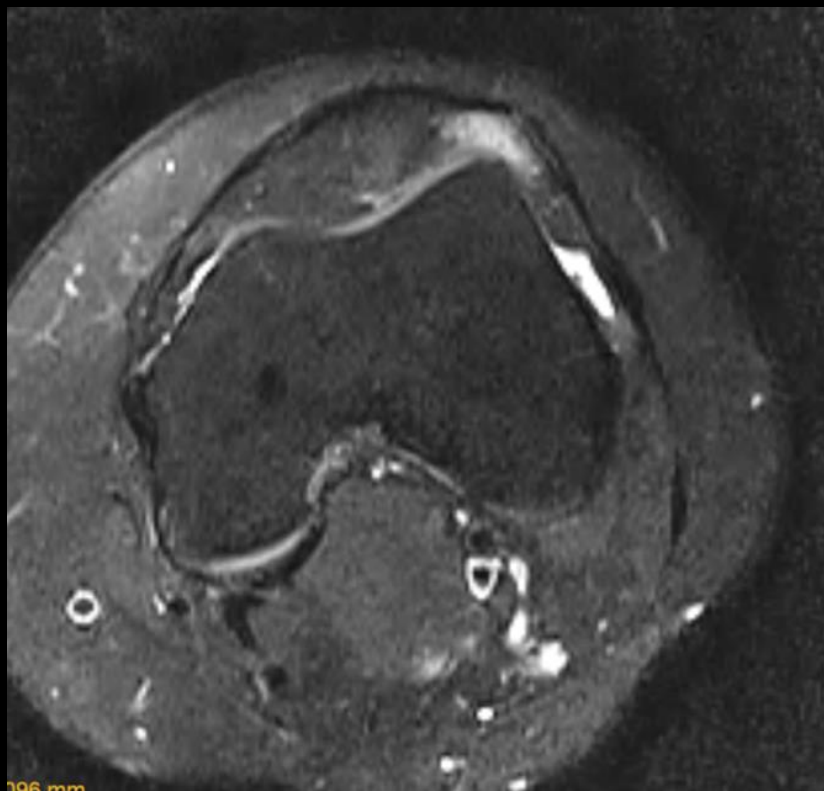
MSS INDIA- Case Of the Day





CASE 2

- 26 year female with complains of knee pain since 1 year.
- Exacerbated by yoga
- Diagnosis ?



A close-up, shallow depth-of-field photograph of a doctor in a white lab coat. The doctor's face is partially visible in the background, looking towards a computer monitor. In the foreground, a silver stethoscope with a grey rubber tubing lies on a wooden surface. The text "Diagnosis ?" is overlaid in white, sans-serif font on the right side of the stethoscope.

Diagnosis ?