


MICOD –05/09/2024

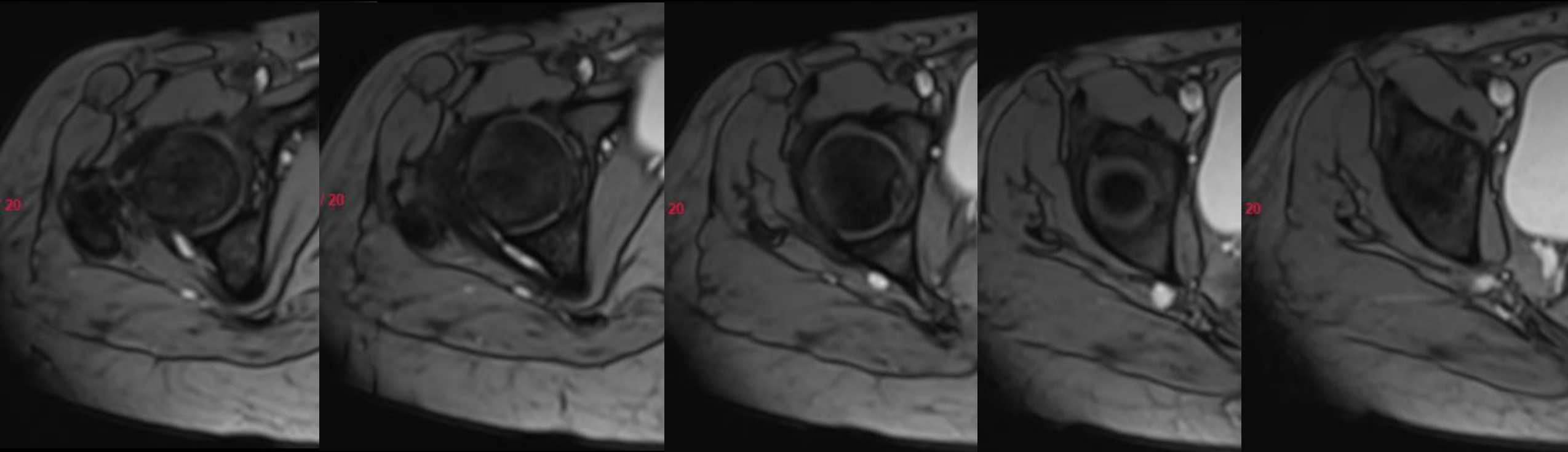
Case contributor – Dr Sagar Tomar

MI-COD

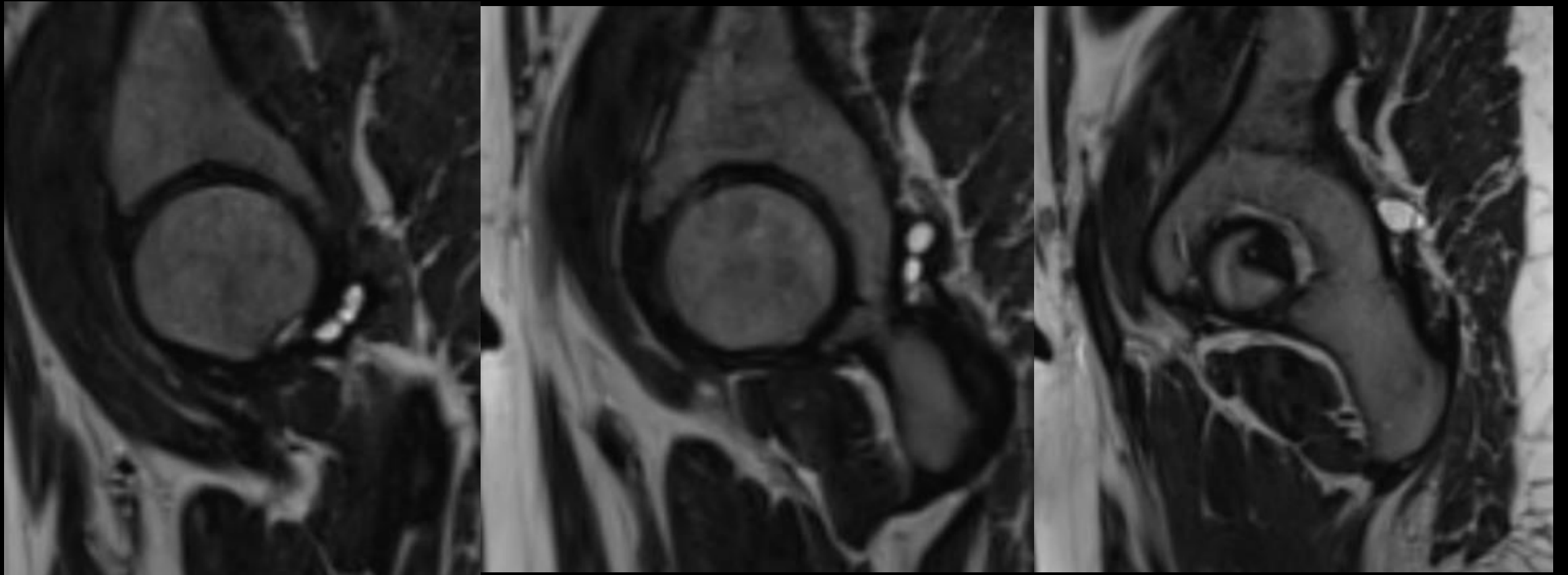
MSS INDIA- Case Of the Day

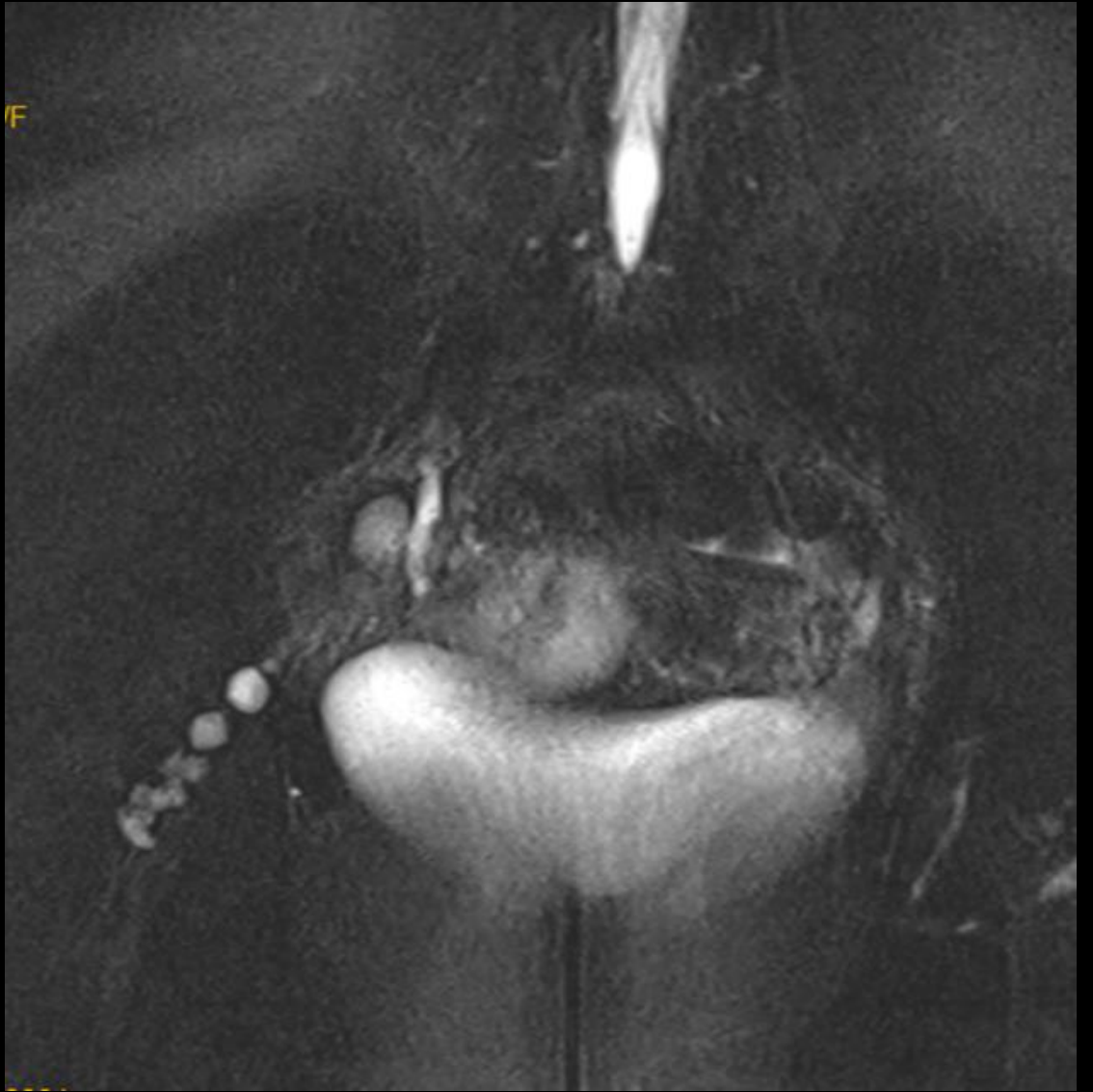
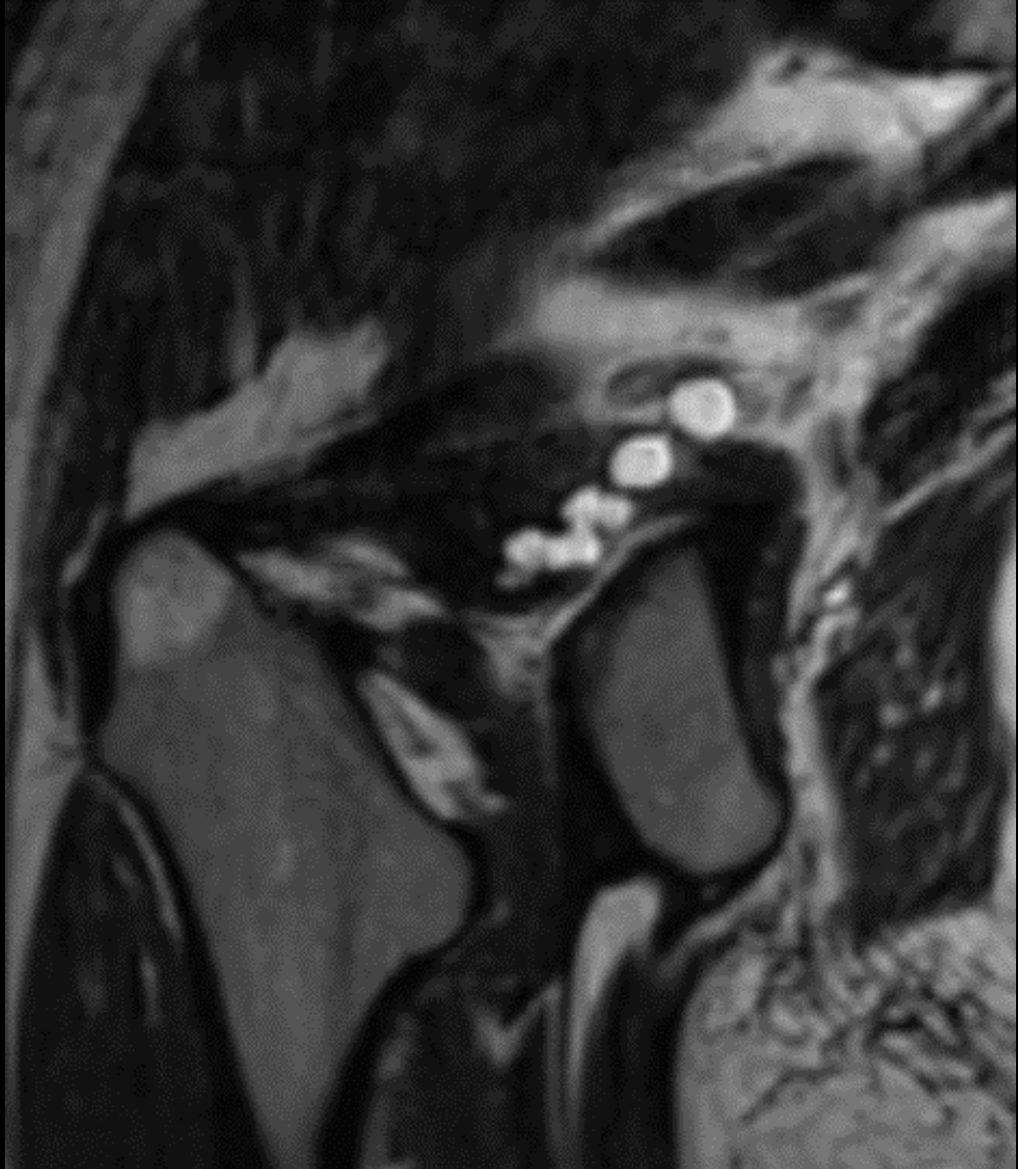

- 27 year old female with right hip pain since many months.



Additional images





A close-up, shallow depth-of-field photograph of a doctor in a white lab coat. The doctor's face is partially visible in the background, looking towards a computer monitor. In the foreground, a silver stethoscope with a grey tube lies on a wooden surface. The text "Diagnosis ?" is overlaid in white on the right side of the image.

Diagnosis ?