


MICOD –04/09/2024

Case contributor – Dr Vaishali Upadhyaya

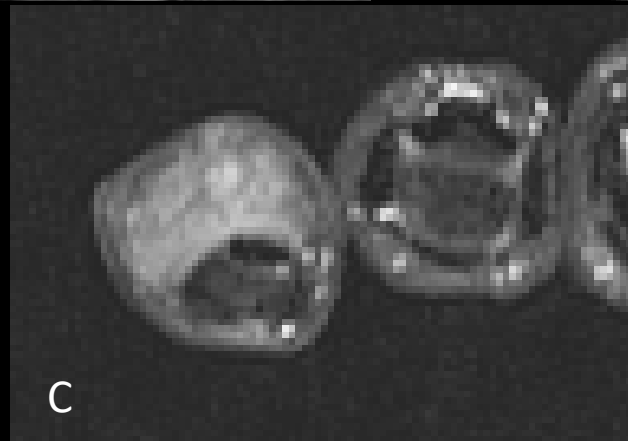
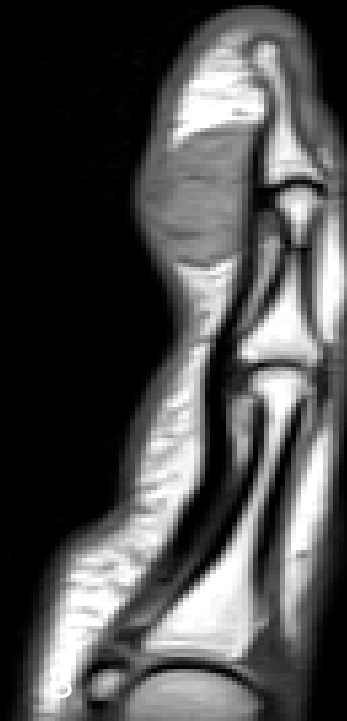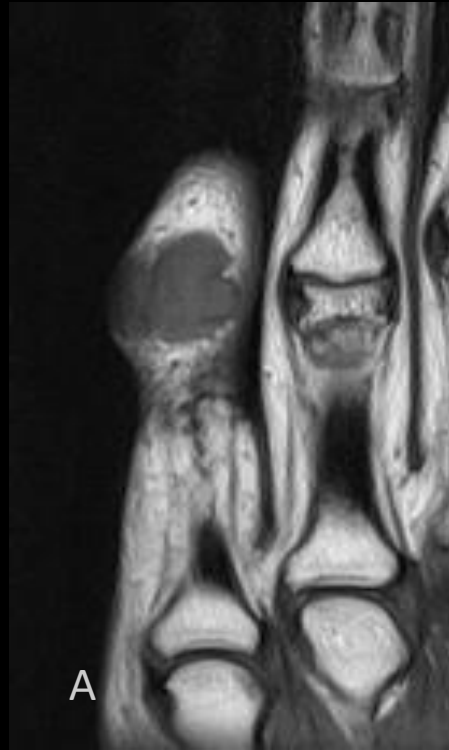
MI-COD

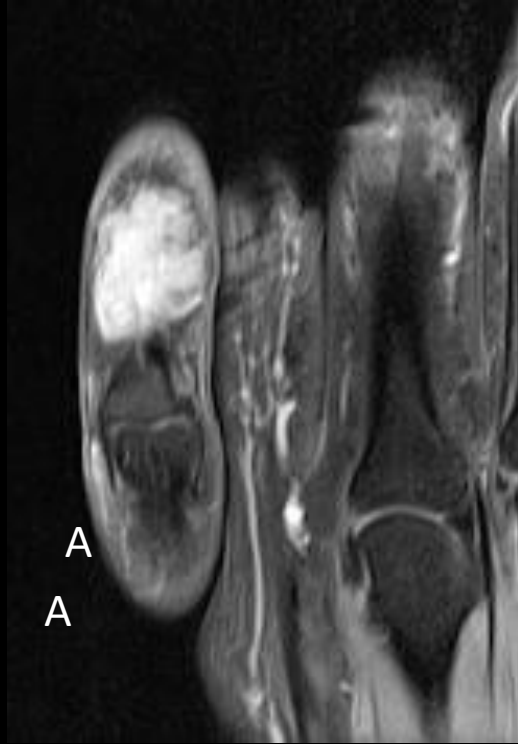MSS INDIA- Case Of the Day



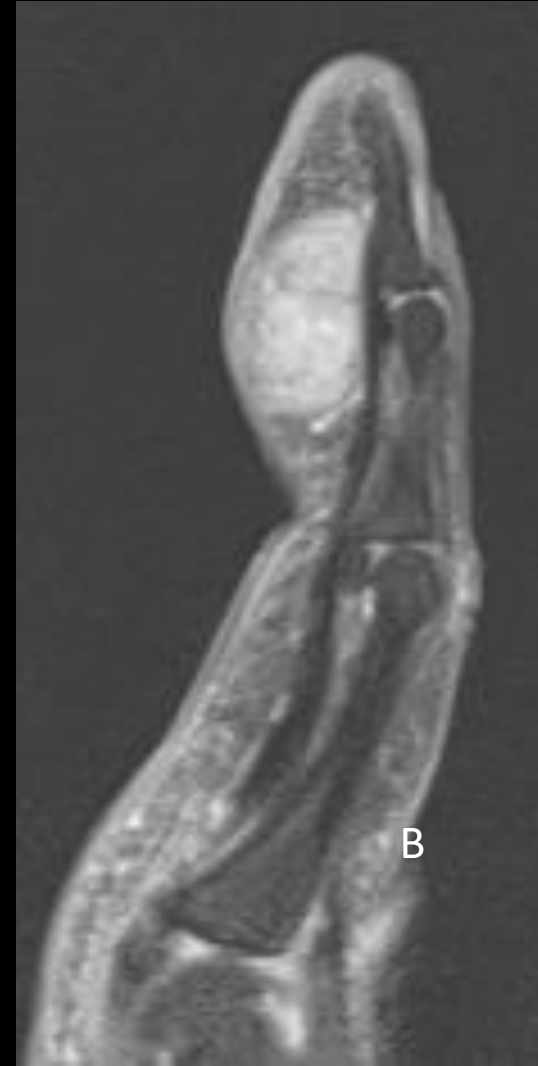- 42-year-old lady with h/o gradually increasing painless swelling on volar aspect of left little finger distally for past eight months

Coronal
T1W(A), Sag
T2W (B) and
axial PD fat
sat (C)
images





Coronal (A) and Sagittal(B)
T1W post contrast fat sat
images



A close-up, shallow depth-of-field photograph of a doctor in a white lab coat. The doctor's face is partially visible in the background, looking towards a computer monitor. In the foreground, a silver stethoscope with a grey rubber tubing lies on a wooden surface. The text "Diagnosis ?" is overlaid in white, sans-serif font on the right side of the stethoscope.

Diagnosis ?