

MICOD – 30/08/2024

Case contributor – Dr. Karan Asthana

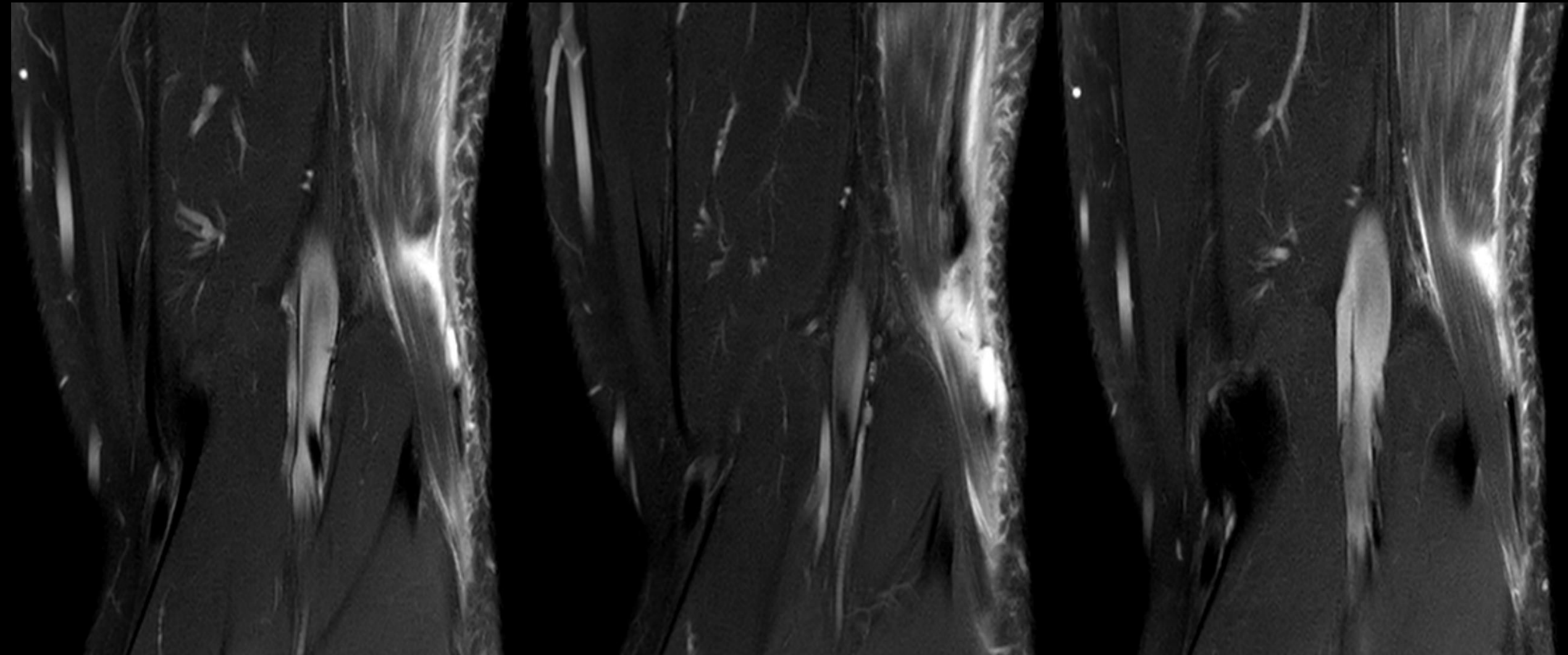
MI-COD

MSS INDIA- Case Of the Day



33-year-old gentleman with alleged history of sports injury

Sequential images



33-year-old gentleman with alleged history of sports injury

