

MICOD - 13/05/24

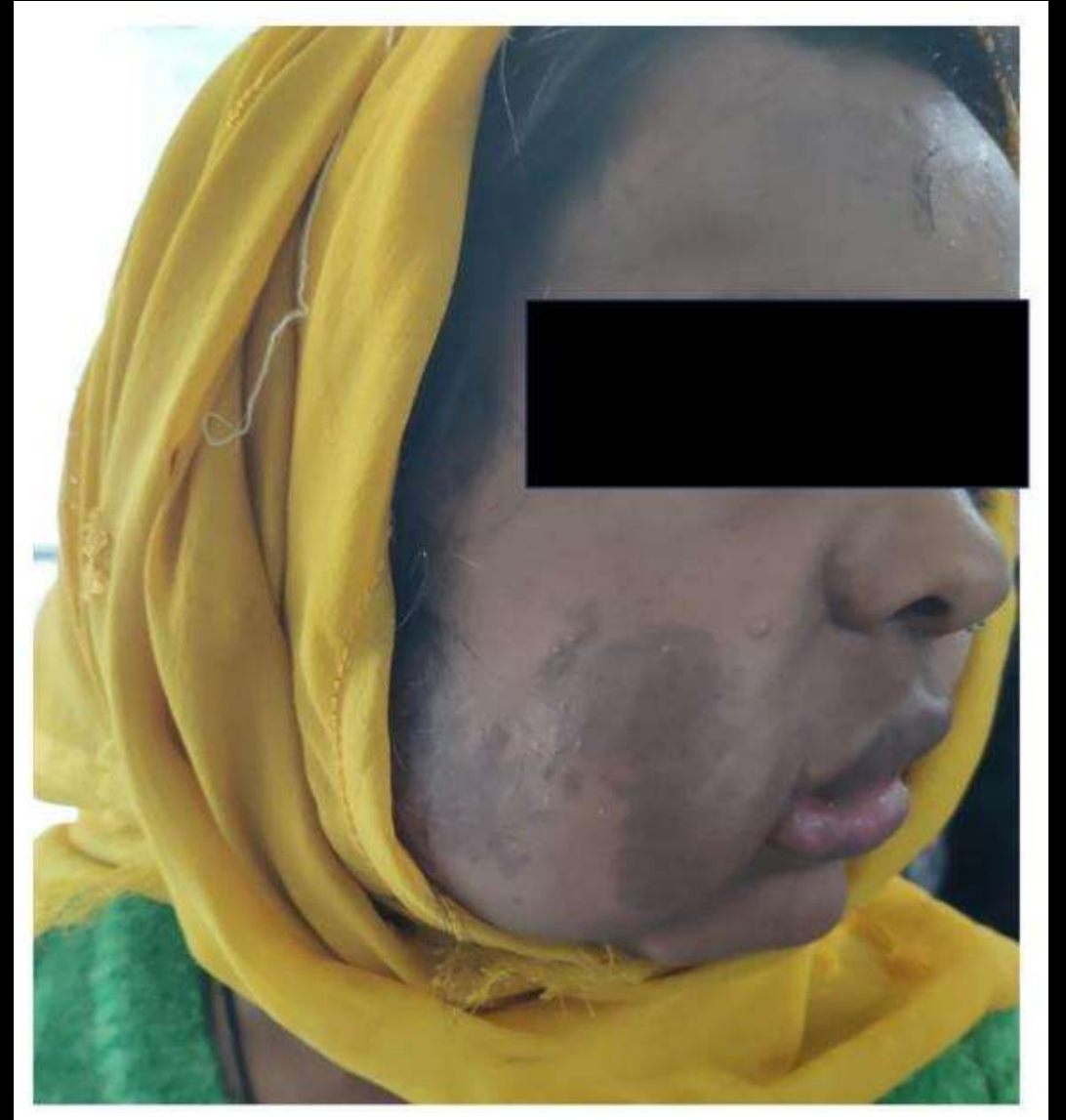Case contributor – Dr. Sonal Saran

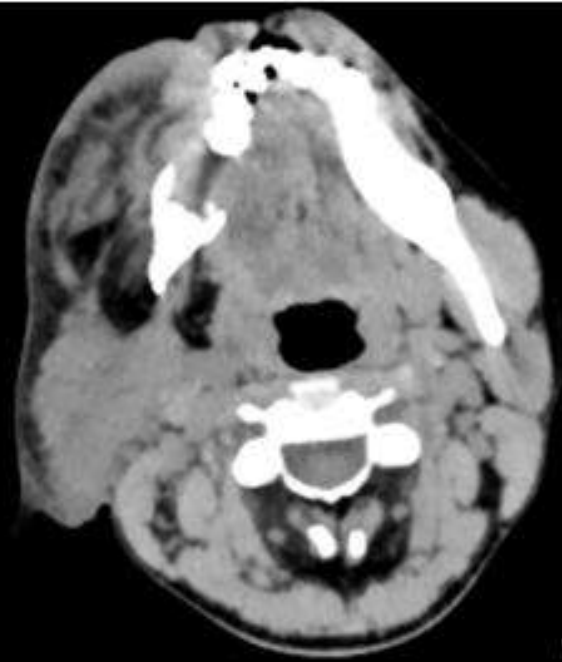
# MI-COD

MSS INDIA- Case Of the Day

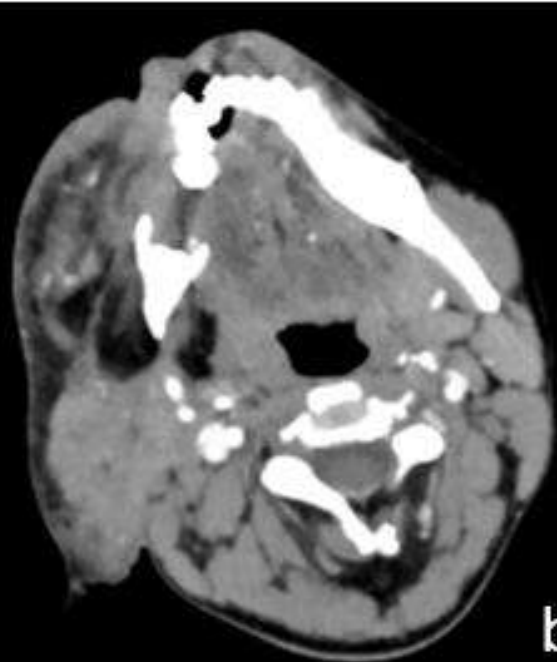


A 17-year-old female patient presented with a chief complaint of swelling of the right side of the face/cheek since birth, which was gradually increasing in size. Other complaints included pain and loosening of teeth. There was no associated fever, trauma, swelling, sinus opening, or pus discharge.

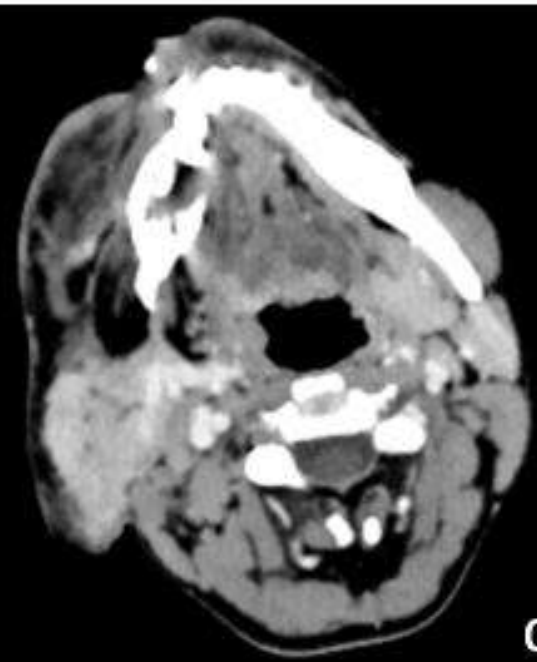




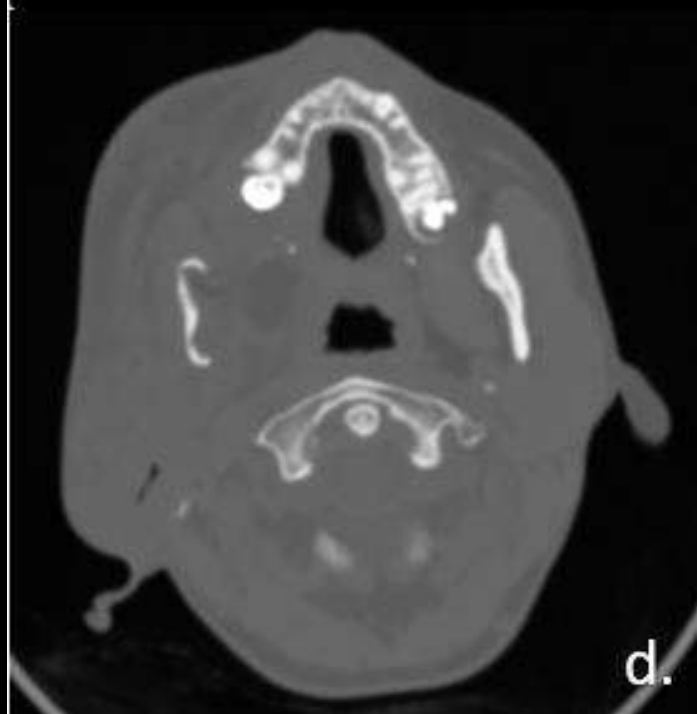a.



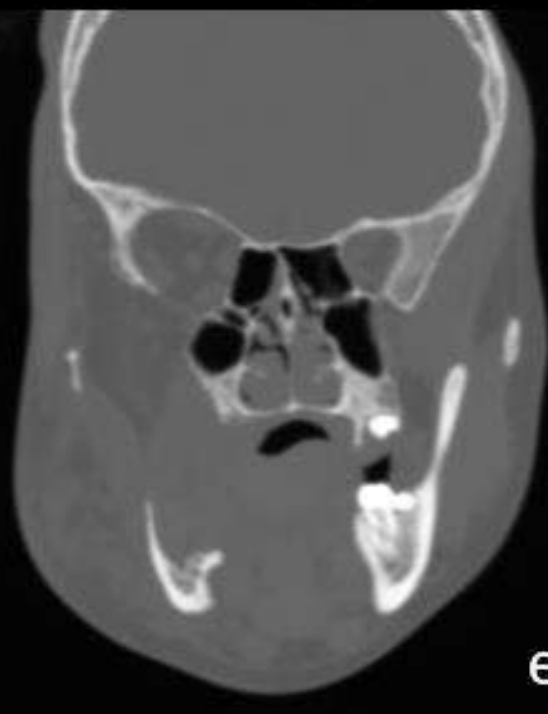b.



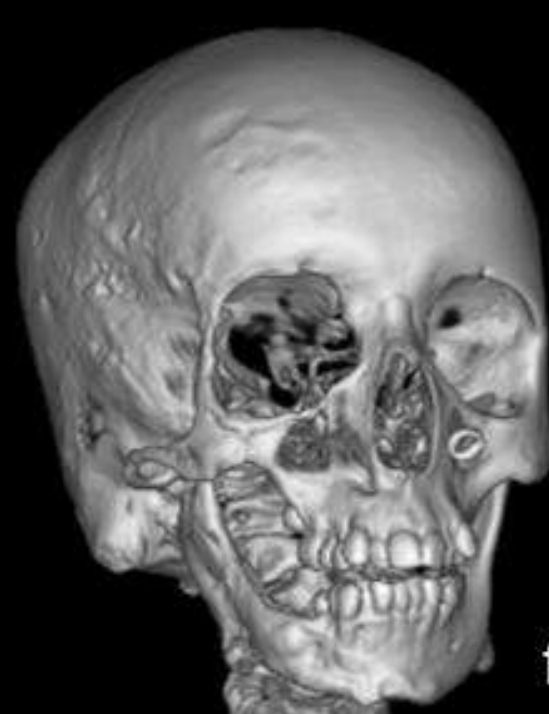c.



d.



e.



f.