

MICOD - 07/05/24

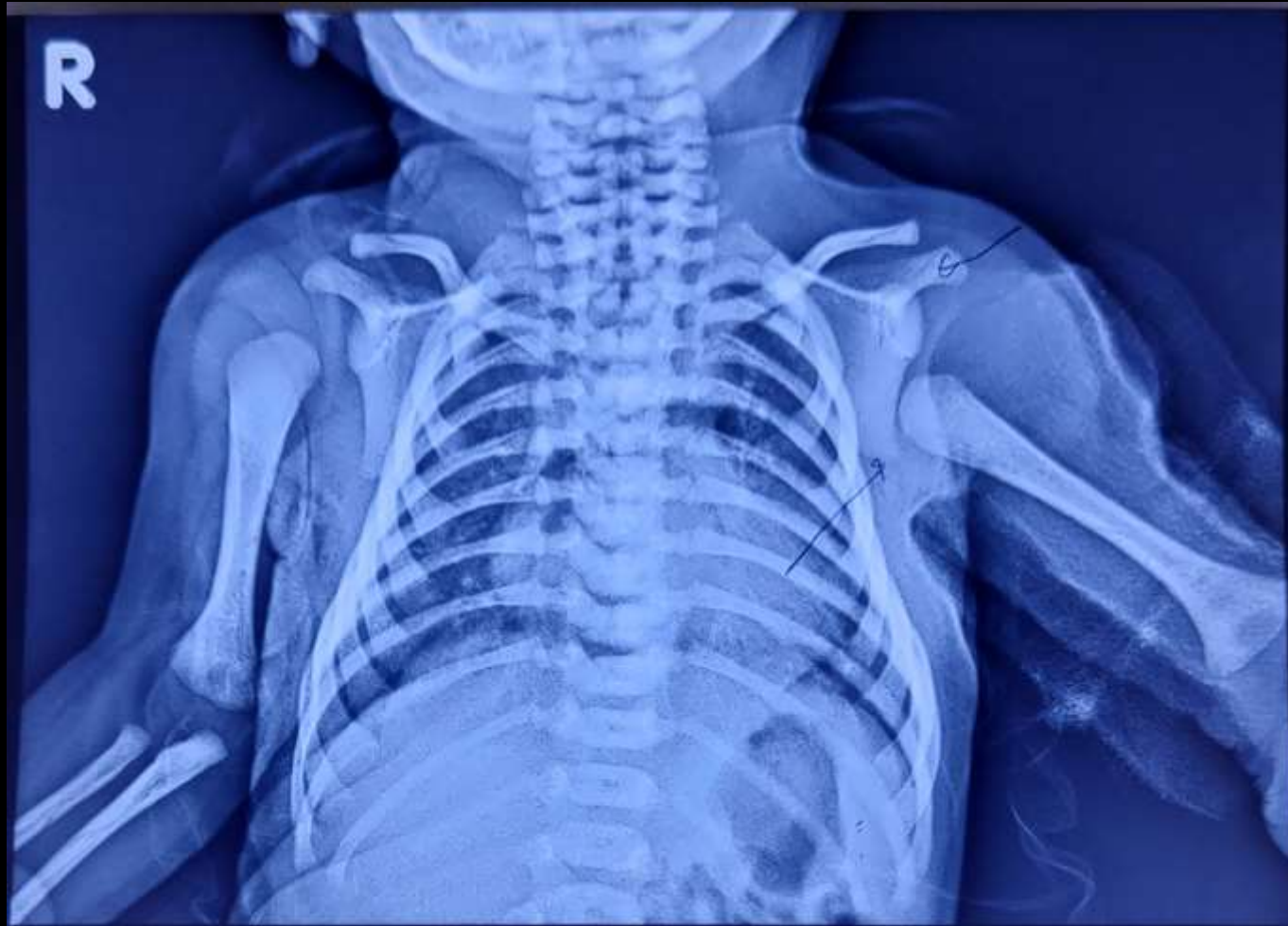Case contributor – Dr. Sonal Saran

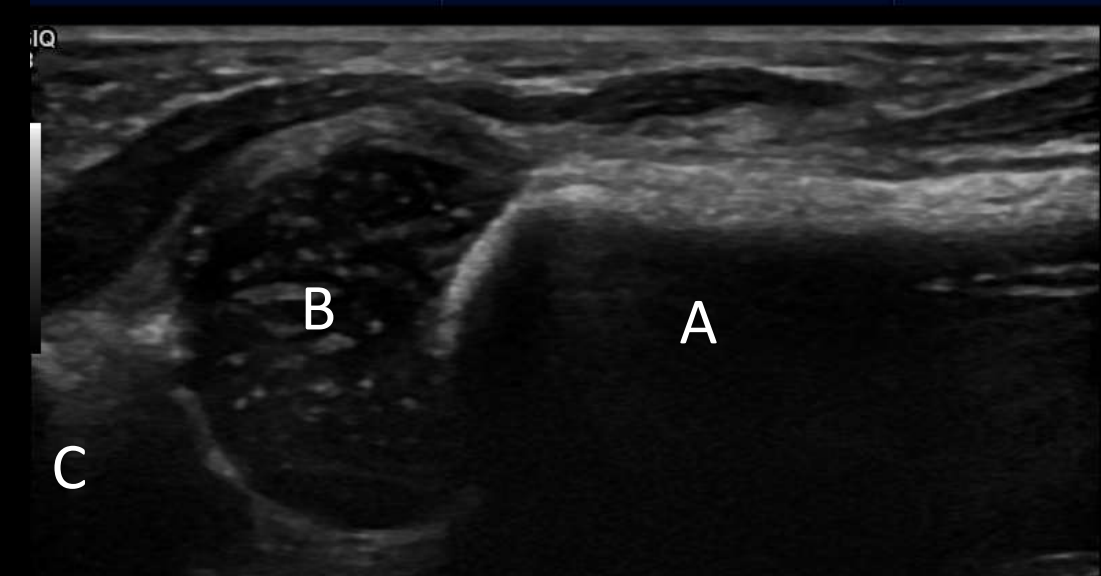
# MI-COD

MSS INDIA- Case Of the Day

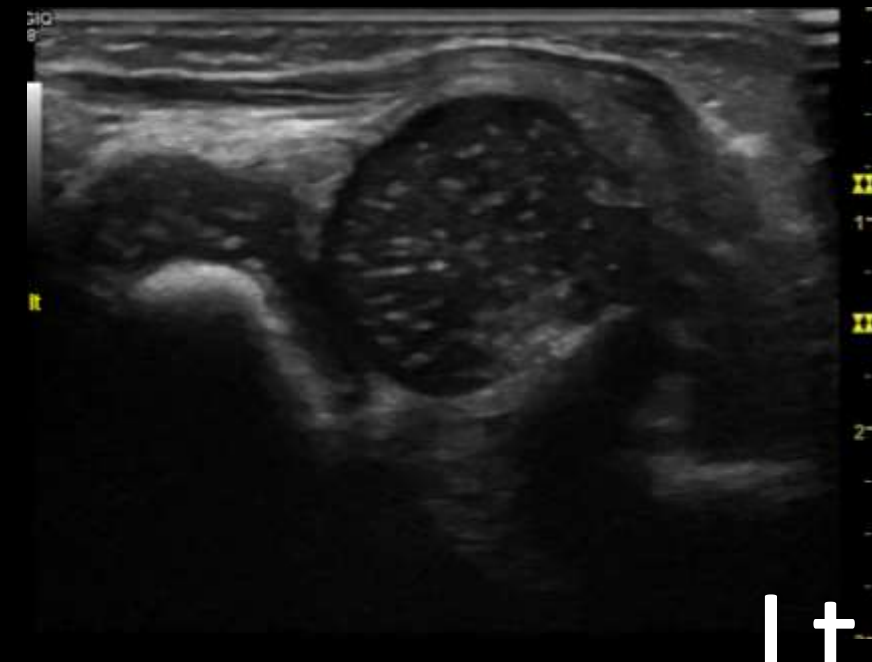


7 days old child, crying and not moving left arm





Rt



Lt

1. Name A, B and C
2. Identify the abnormality in left
3. .... Type .....