

MICOD - 06/05/24

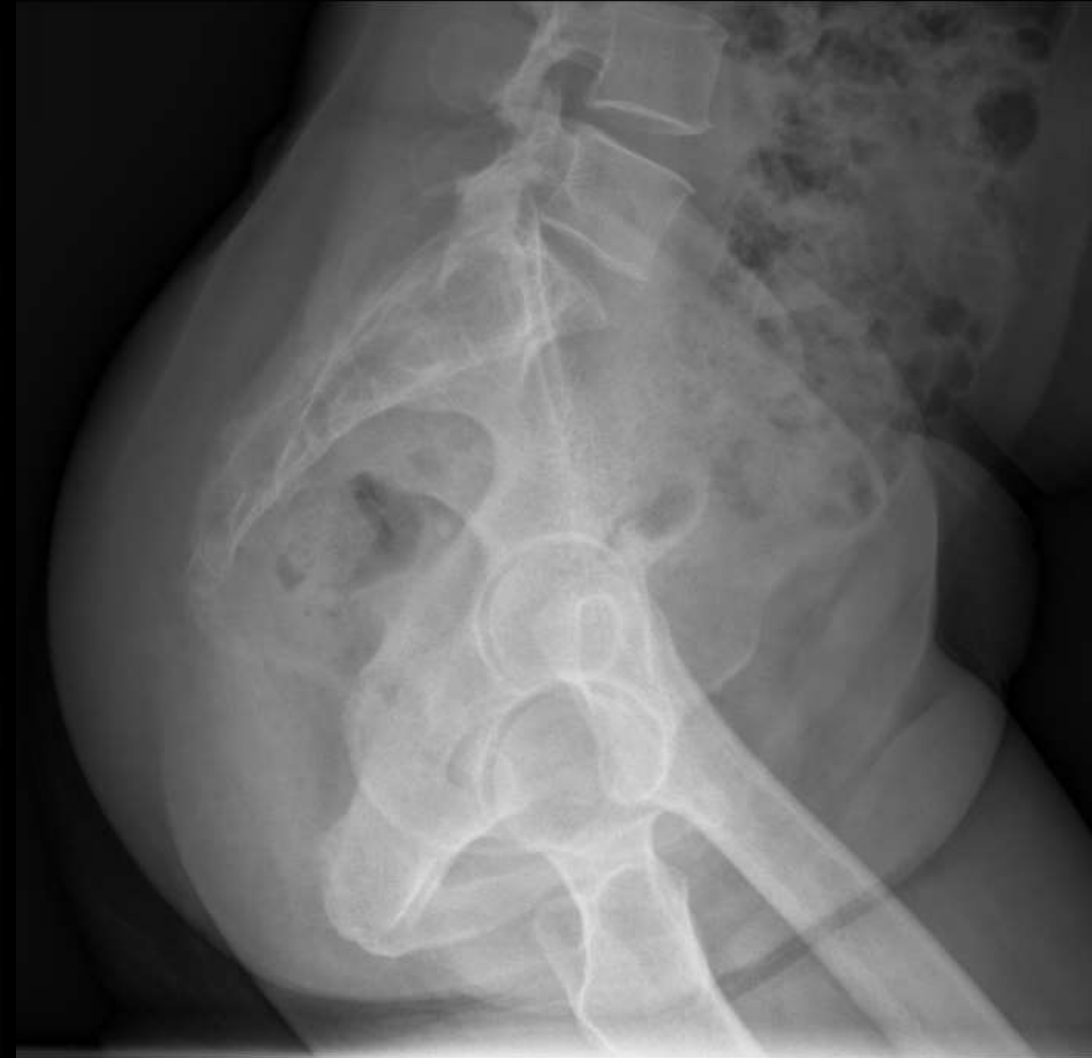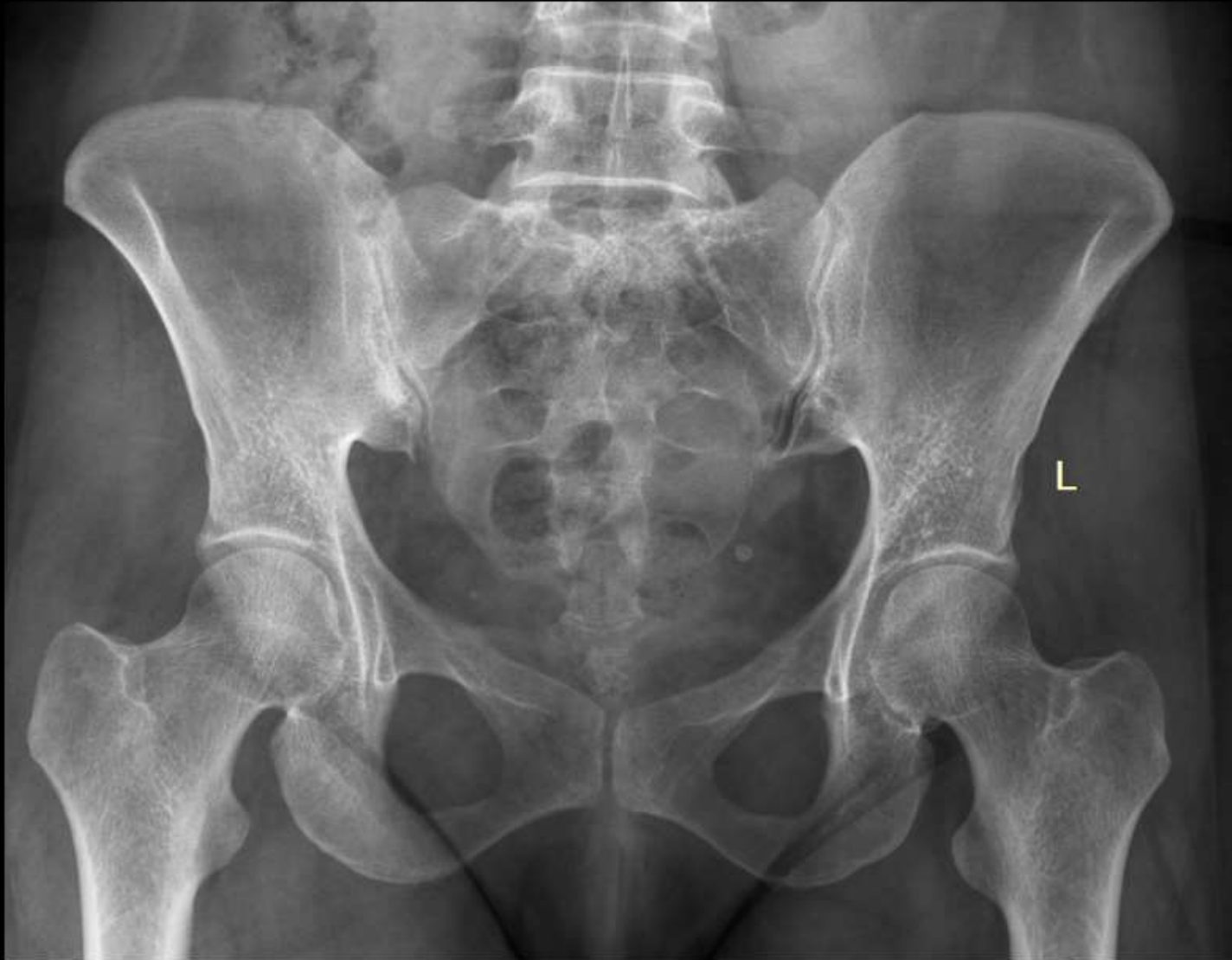Case contributor – Dr. Sonal Saran

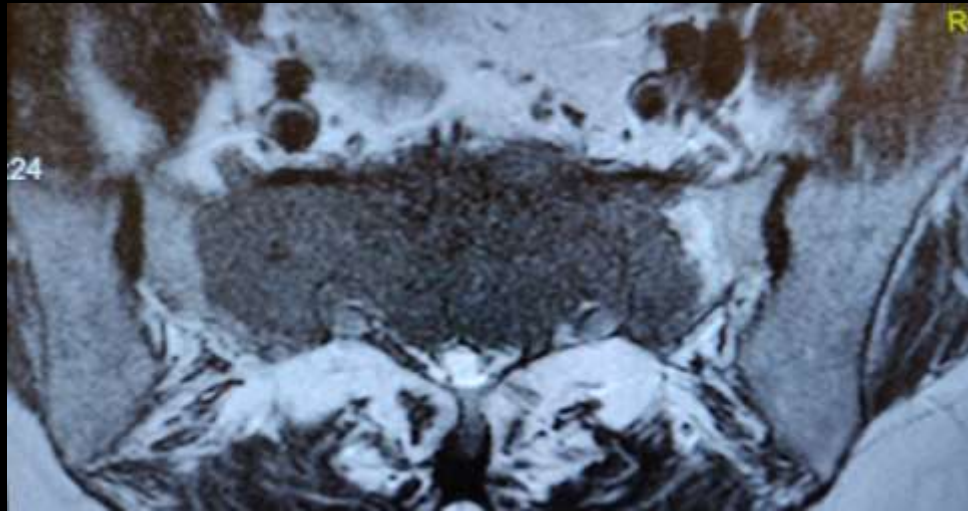
# MI-COD

MSS INDIA- Case Of the Day

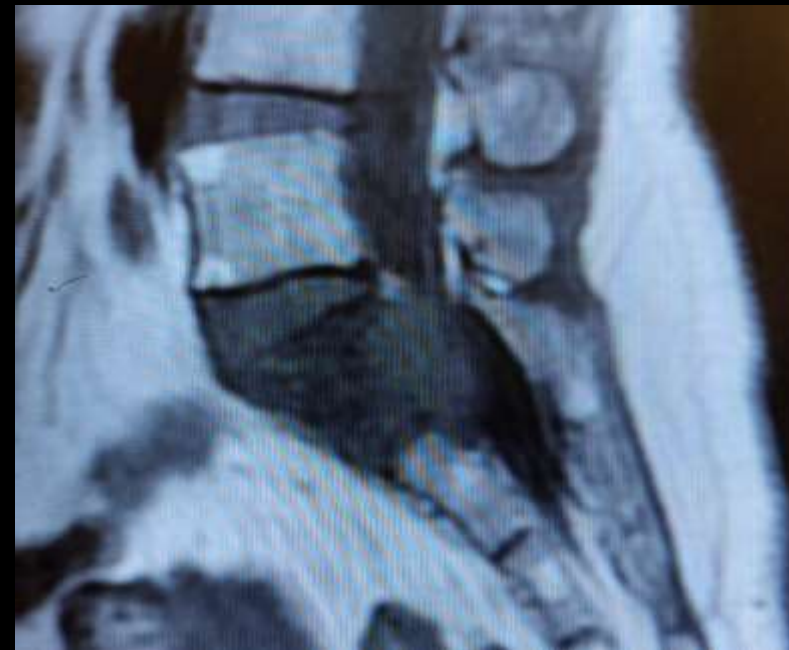

45 year old female with pain in lower back

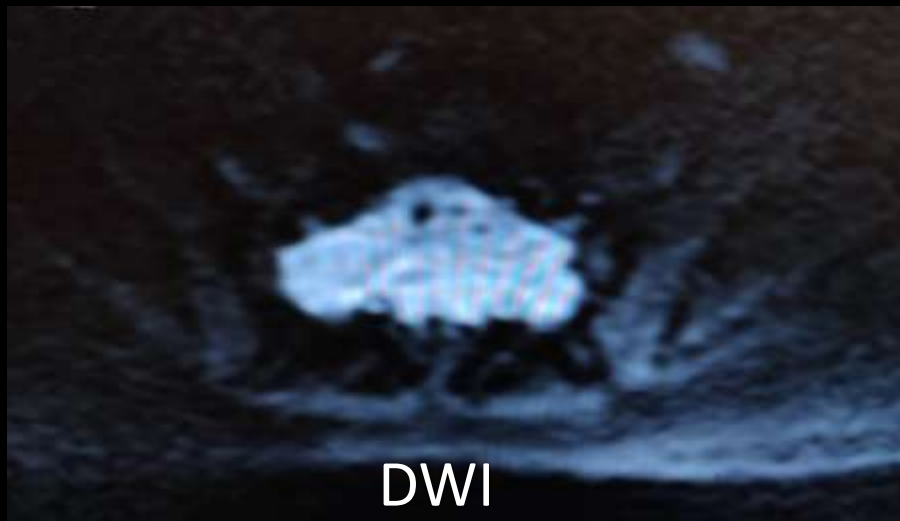



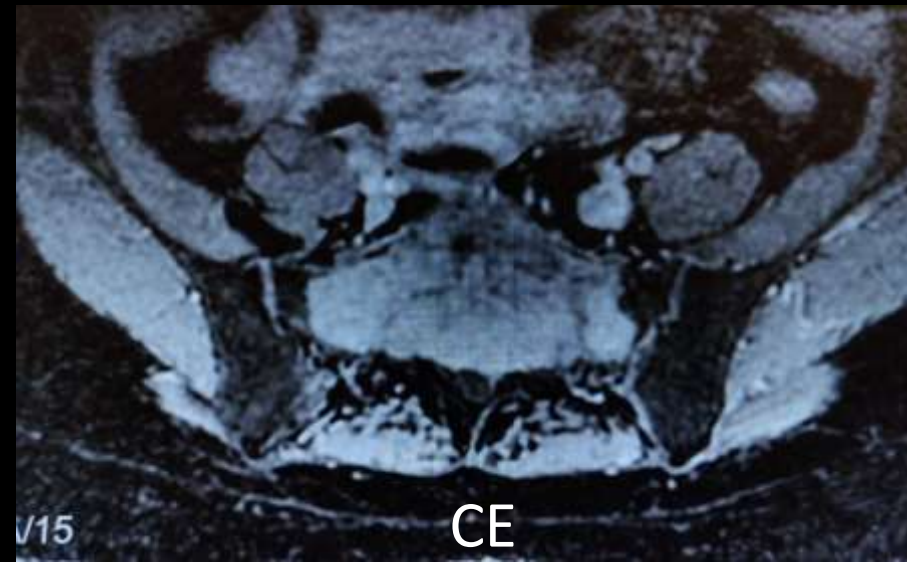
T2



T1



DWI



CE