


MICOD – 29/08/2024

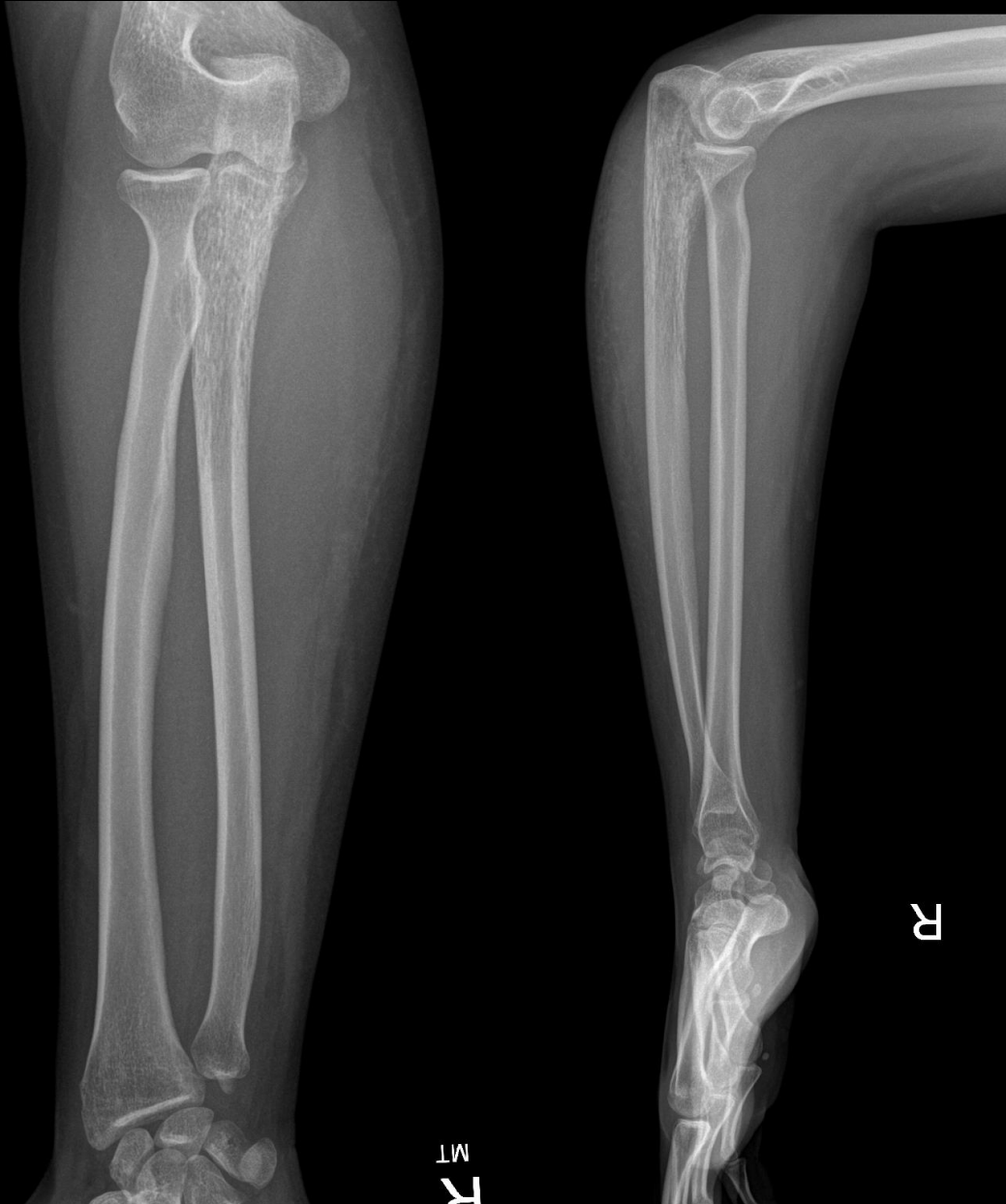Case contributor – Dr. Uma Devi Murali Appavoo Reddy

MI-COD

MSS INDIA- Case Of the Day



32-year-old, pain in right forearm for 2 years, recent onset of swelling & increased pain



Possibilities please ?

Spoiler alert
Clue
in next page

From a different patient with the same disease (online source)

