

MICOD – 27/08/2024

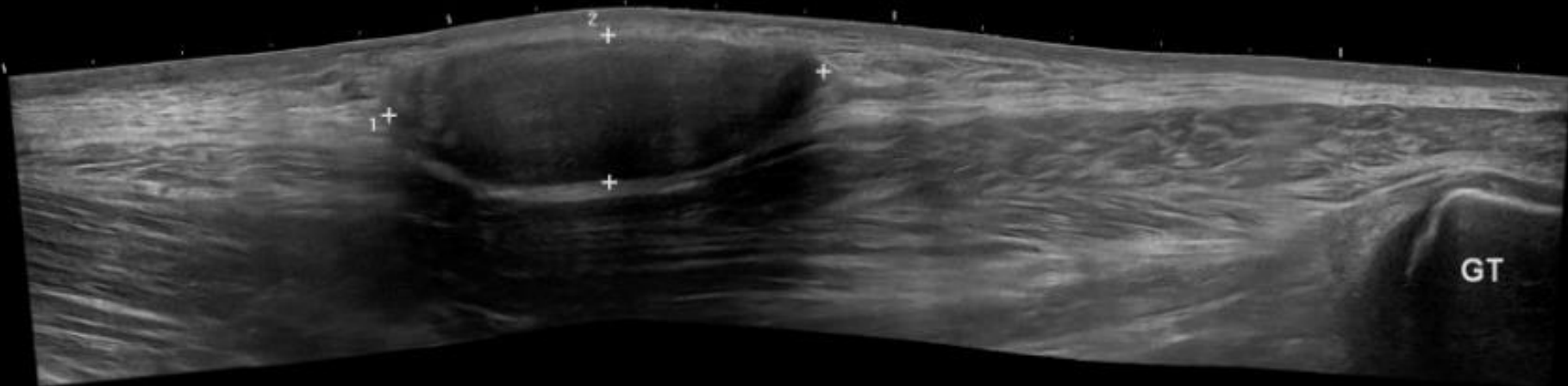
Case contributor – Dr. Raj Chari

# MI-COD

MSS INDIA- Case Of the Day



70-year-old gentleman, smoker with acute on chronic lower limb ischaemia and history of multiple procedures for atherosclerotic disease, presented with growing painless mass in the hip



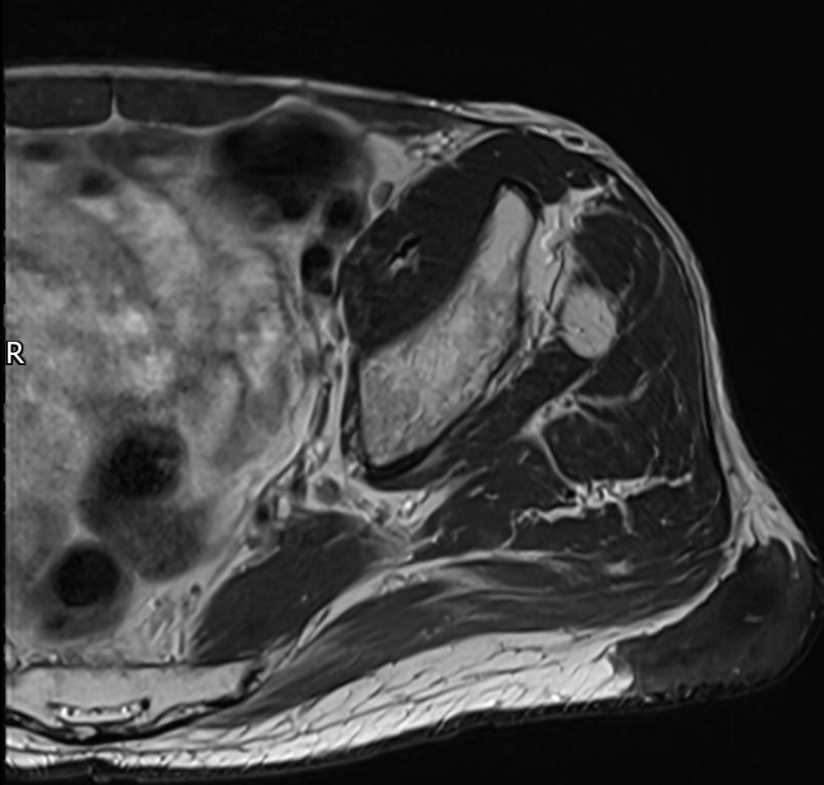
| CHI  | X    |
|------|------|
| Frq  | 10.0 |
| Gn   | 63   |
| S+/A | 3/0  |
| Map  | C/0  |
| D    | 3.5  |
| Zm   | 0    |
| DR   | 69   |
| AO%  | 100  |

Se: 1  
18.82 mm  
Im: 303 mm

LEFT

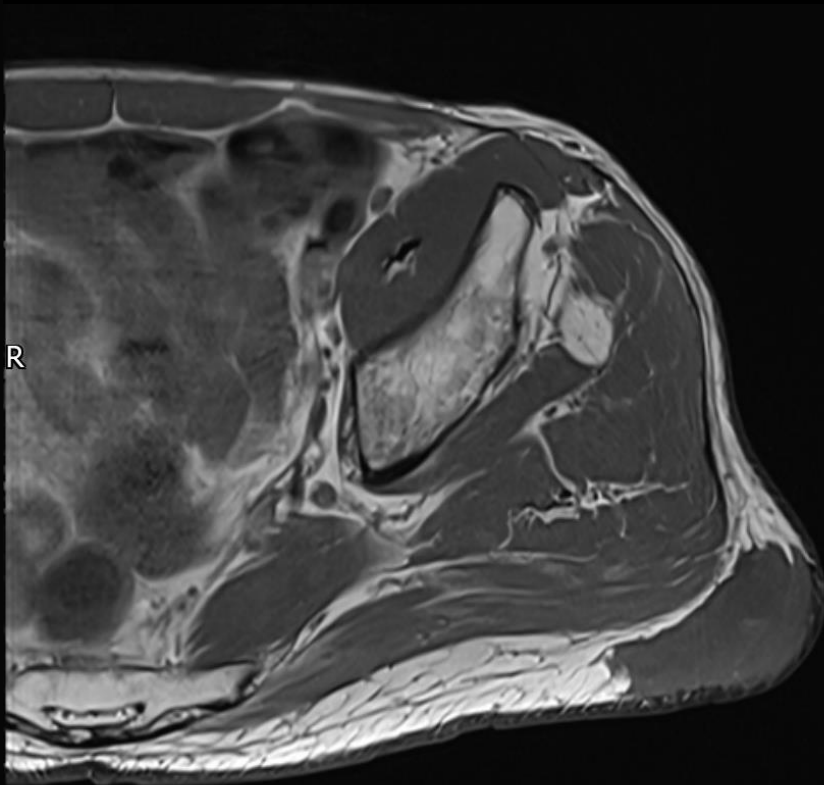
Ultrasound Image

70-year-old gentleman, smoker with acute on chronic lower limb ischaemia and history of multiple procedures for atherosclerotic disease, presented with growing painless mass in the hip



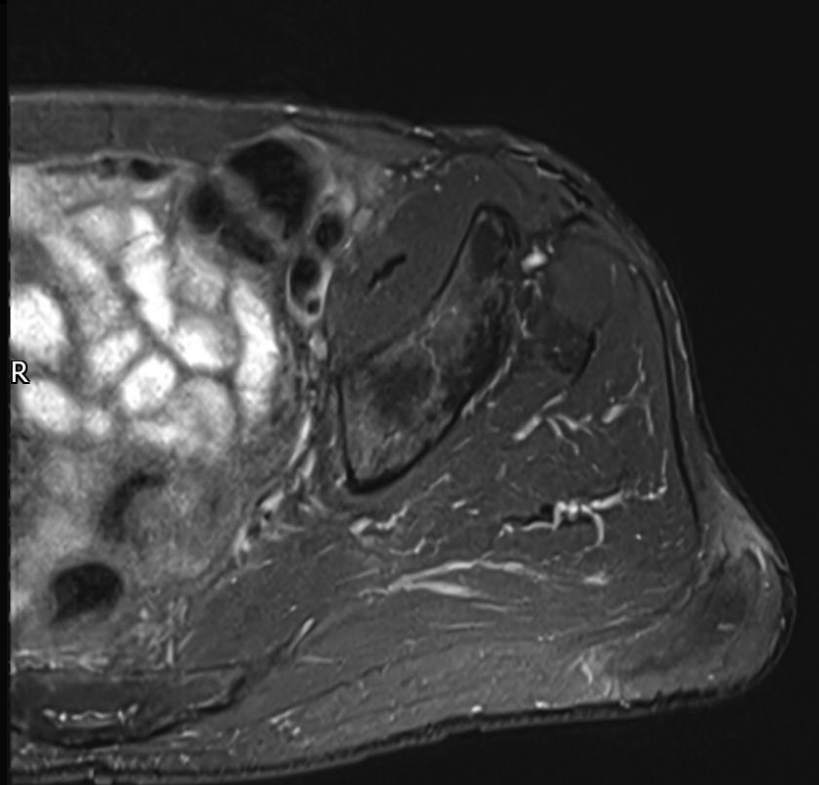
Se: 16 Im: 9

P



Se: 15 Im: 9

P



Se: 14 Im: 9

P

*Axial T2, T1, STIR MR images*

70-year-old gentleman, smoker with acute on chronic lower limb ischaemia and history of multiple procedures for atherosclerotic disease, presented with growing painless mass in the hip

What is going on?

How do we biopsy if necessary?

*Is this a bit of a desi ghee?*

*Is this a bit of a tumorlike brie?*

*Perhaps due to vascular spree?*

*Or has he fallen off a tree?*