

MICOD – 22/08/2024

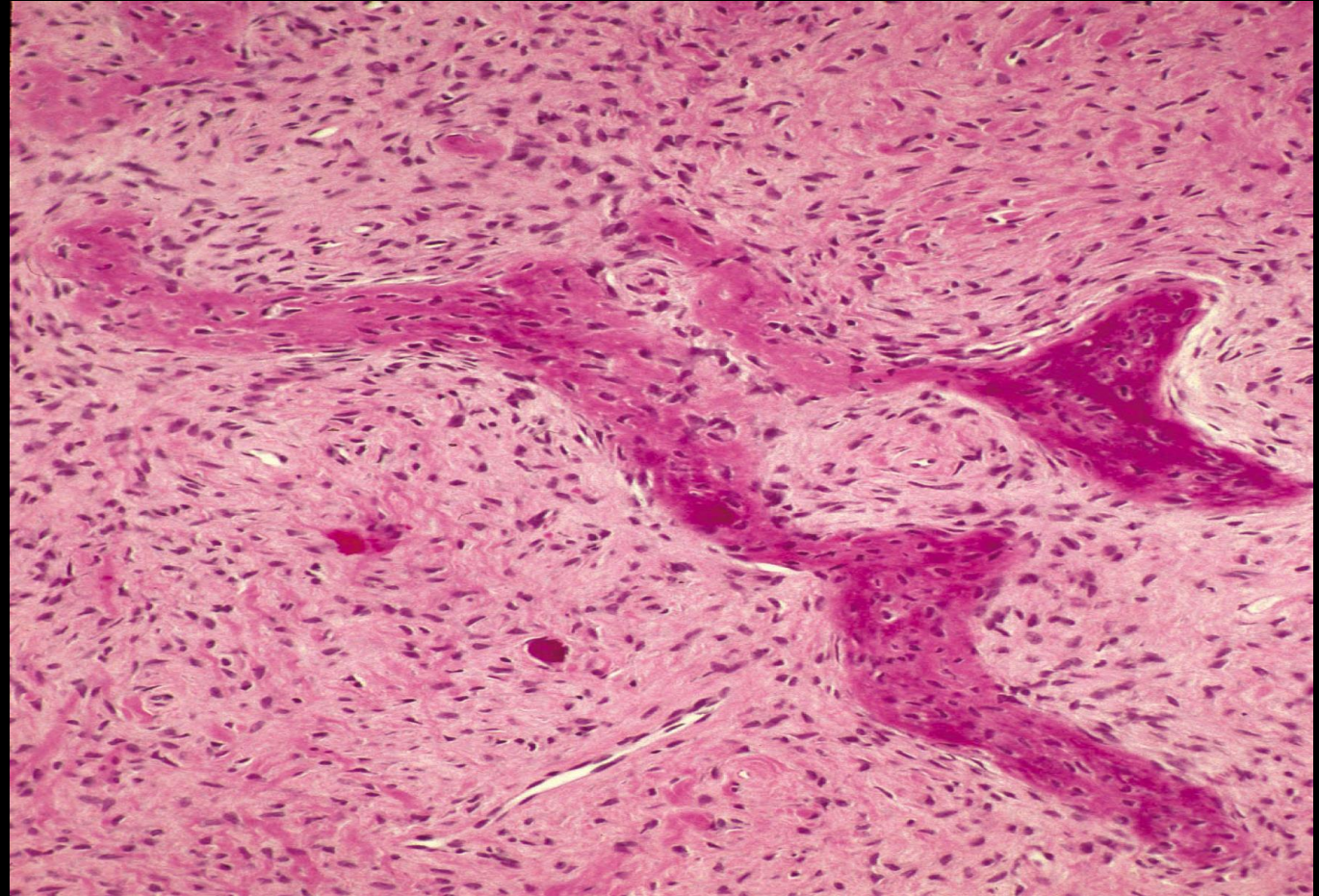
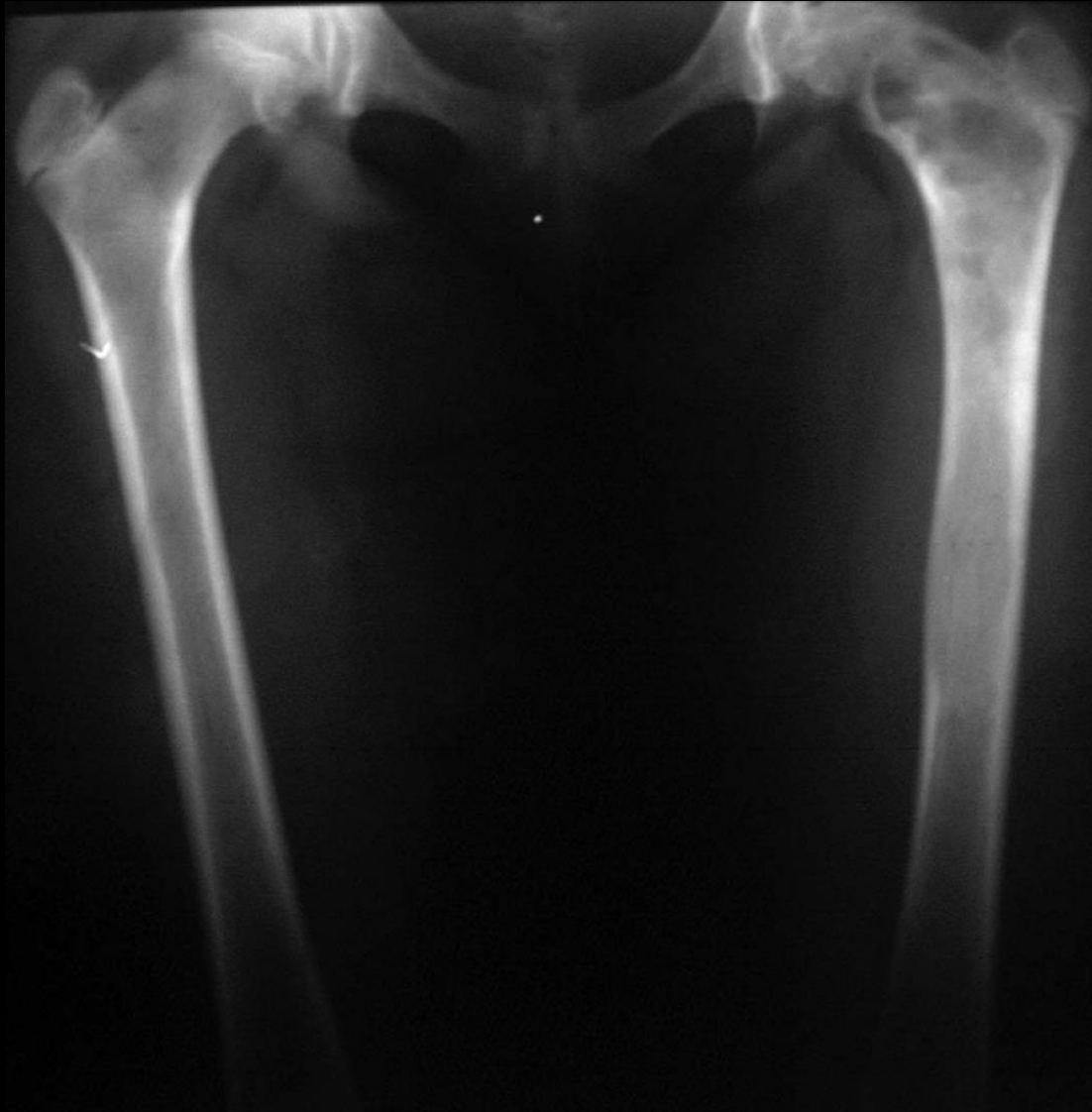Case contributor – Dr. Nirmala Jambhekar

# MI-COD

MSS INDIA- Case Of the Day



# 11-year-old girl child with recent history of left hip pain



Findings & diagnosis?