

MICOD – 21/08/2024

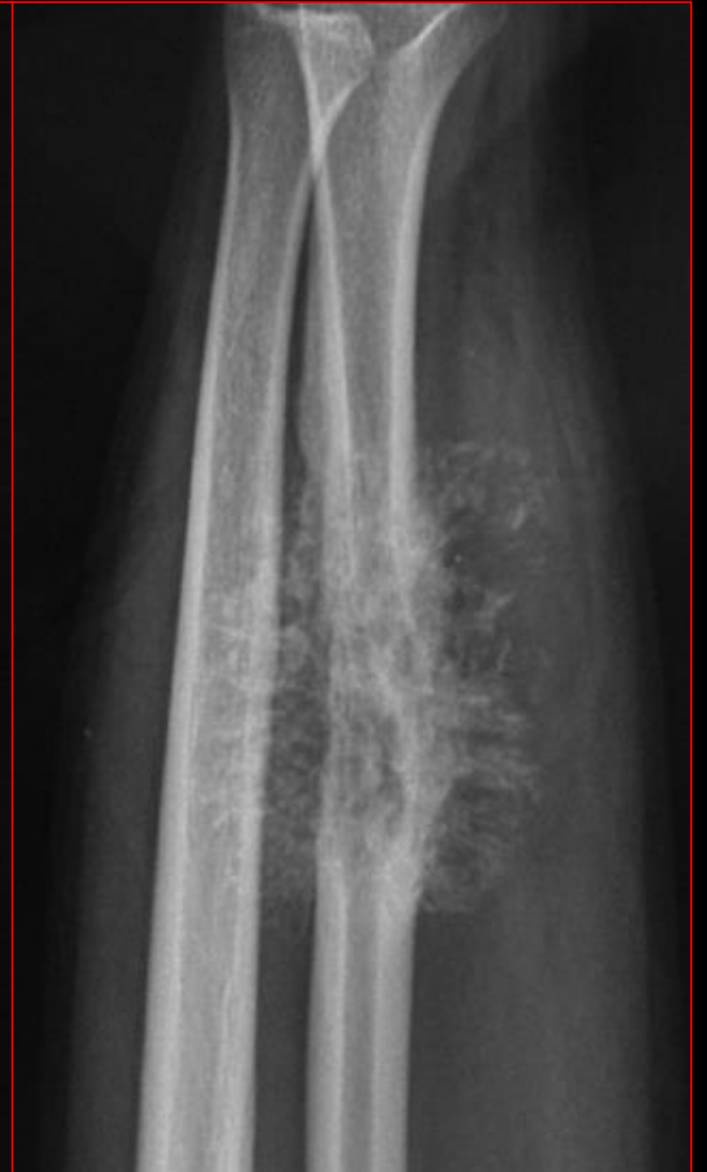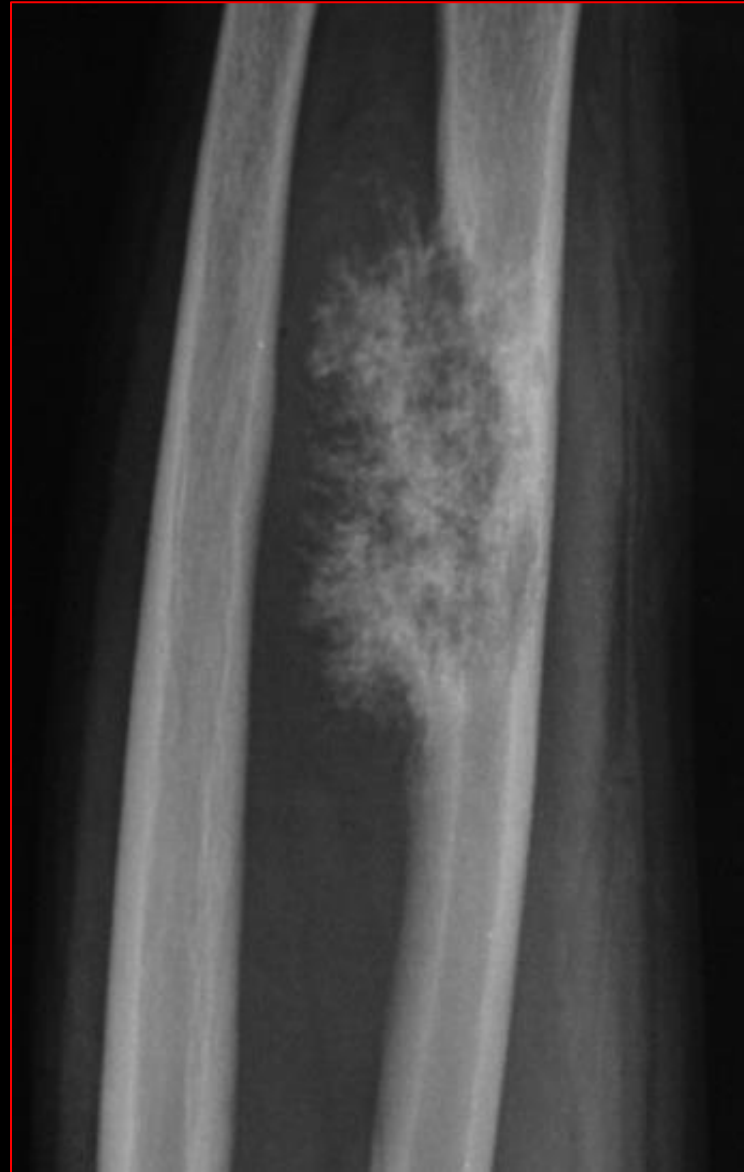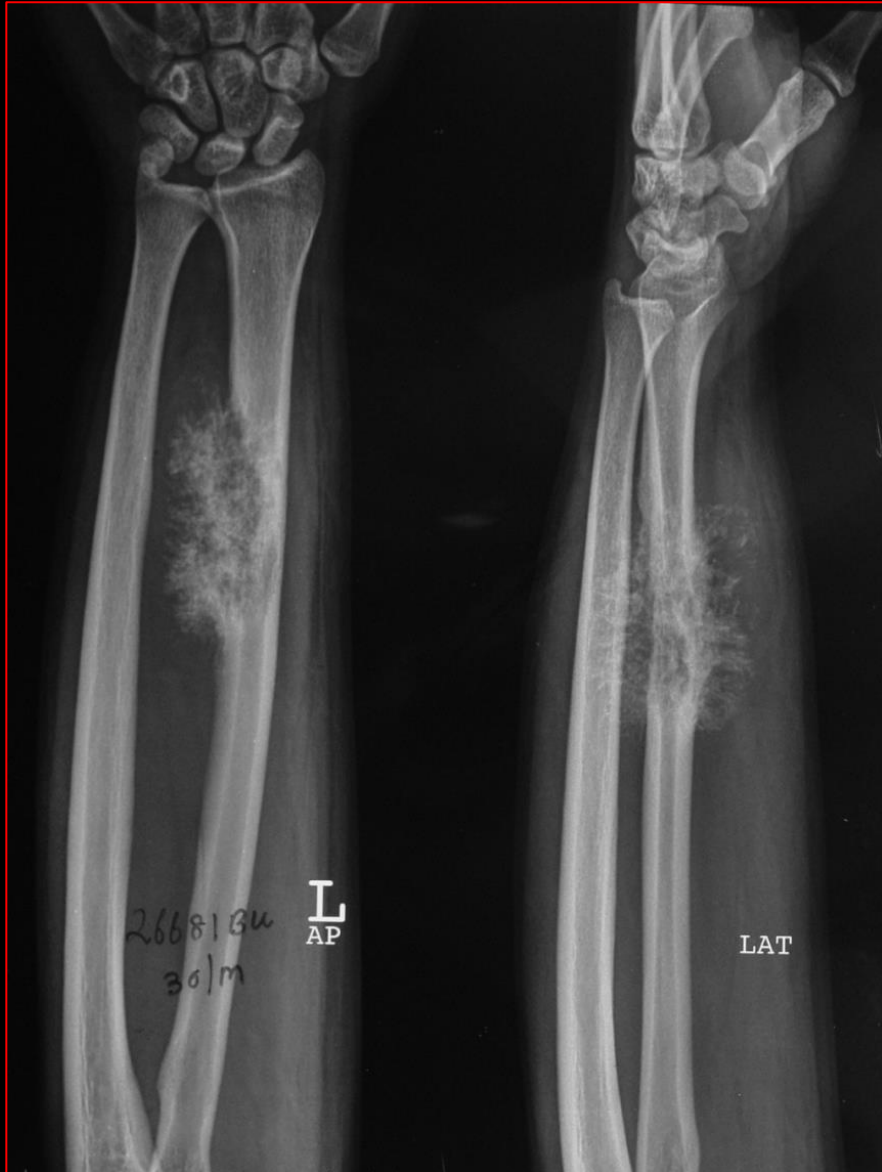Case contributor – Dr. Nirmala Jambhekar

# MI-COD

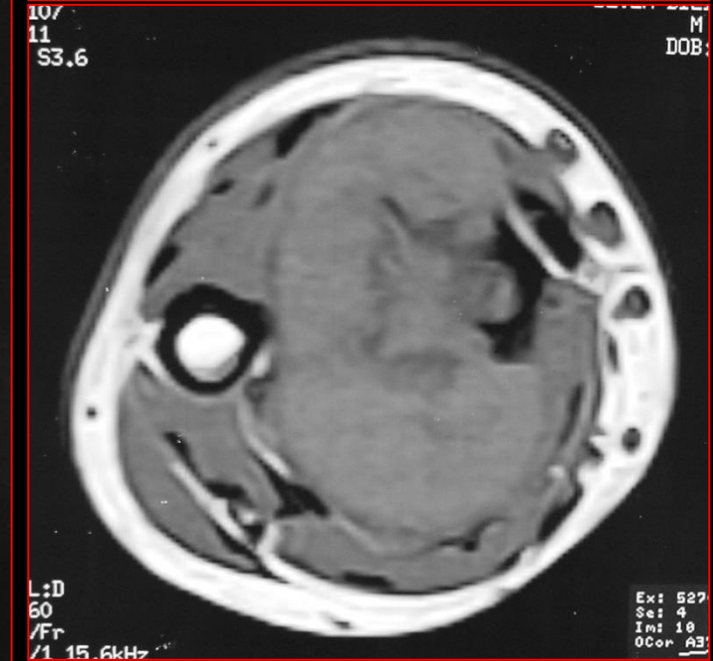
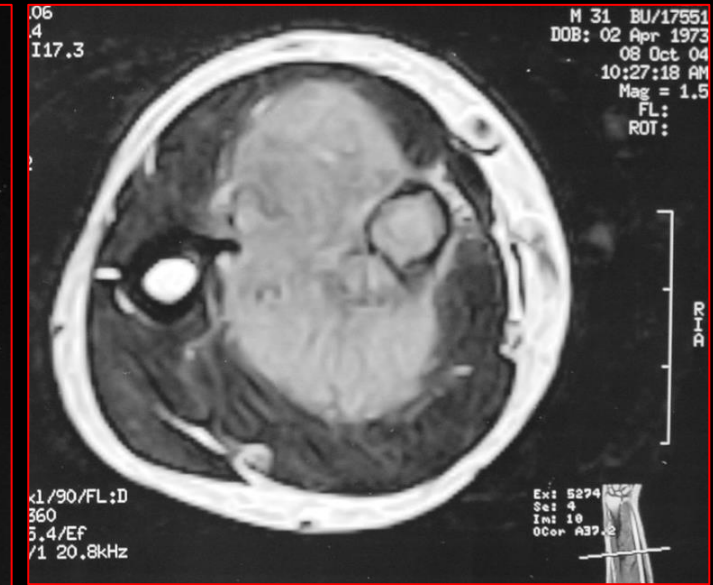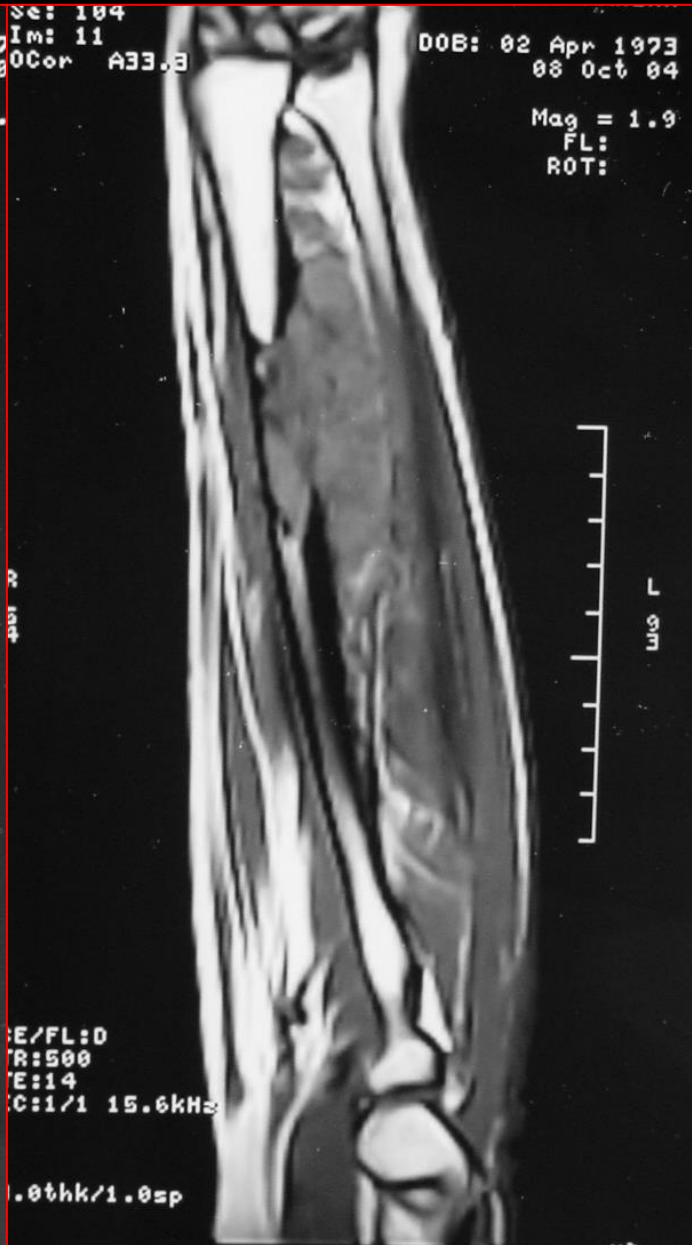
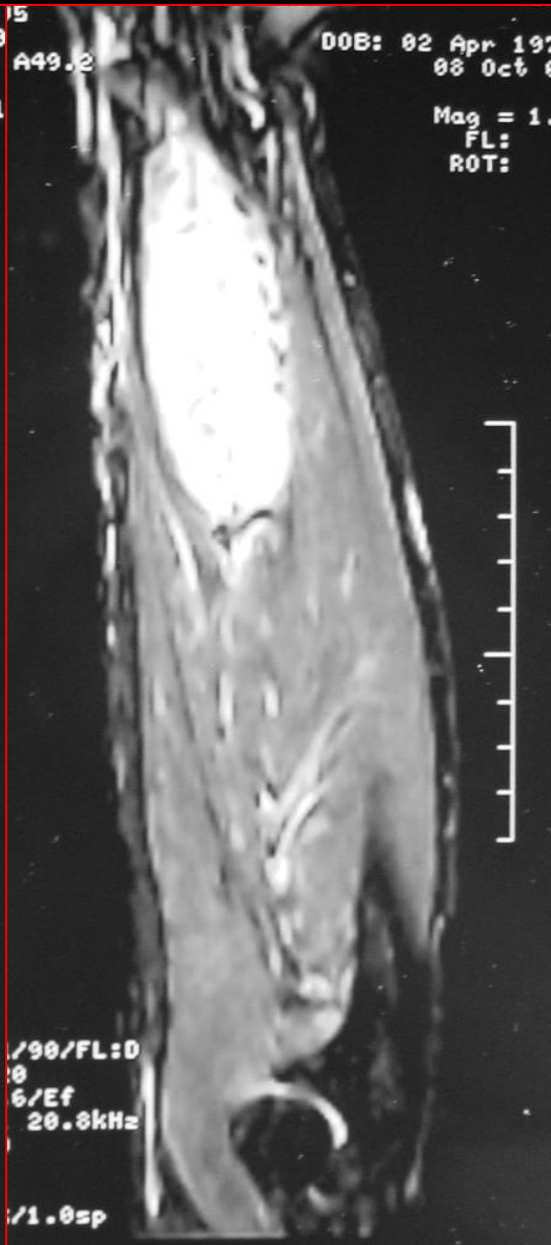
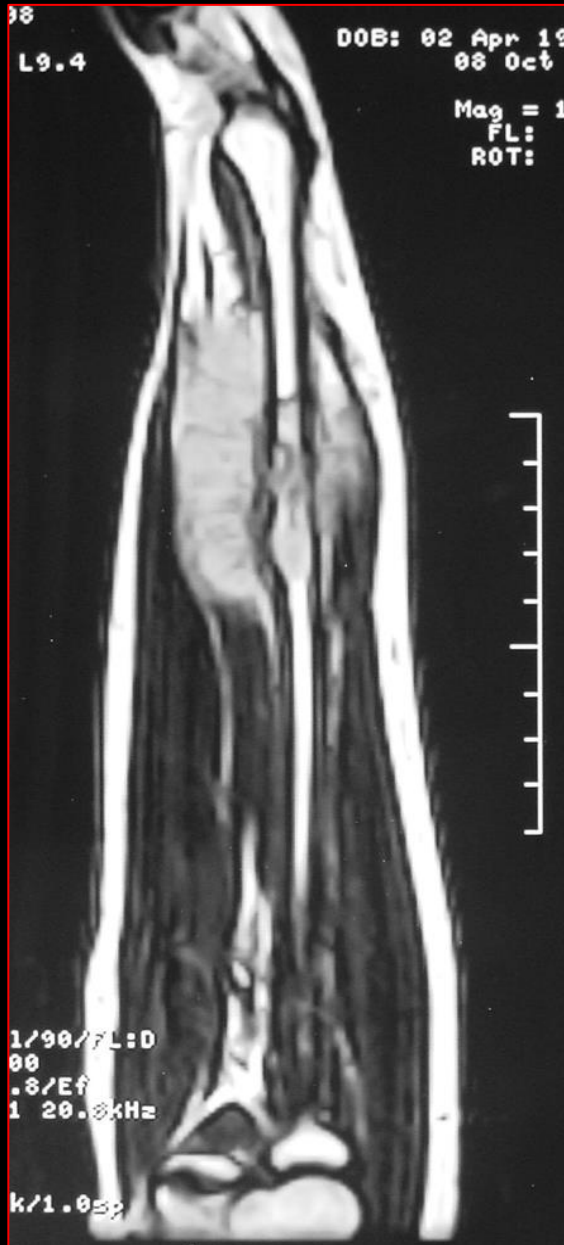MSS INDIA- Case Of the Day



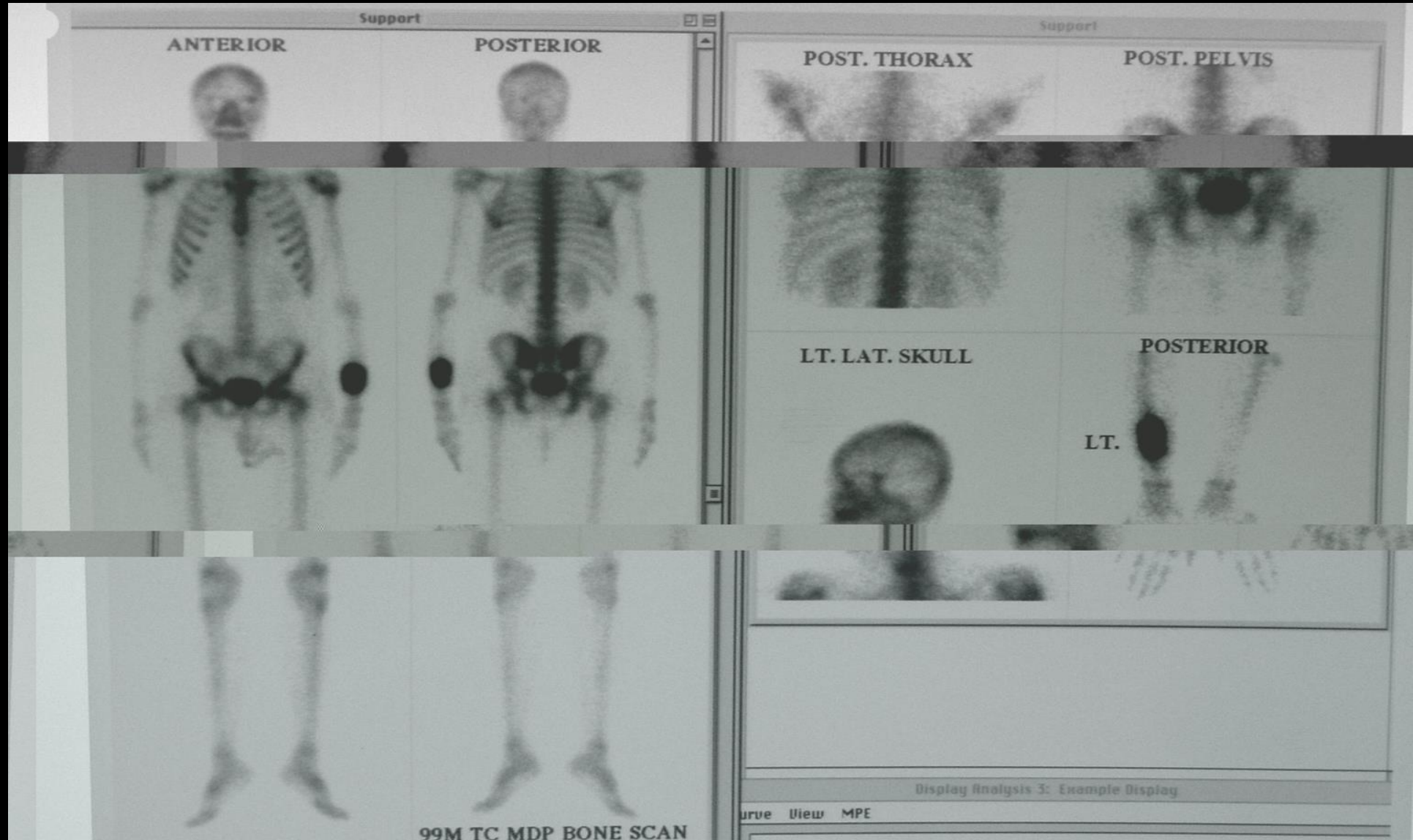
# 35-year-old gentleman with swelling since 4 – 6 months



# 35-year-old gentleman with swelling since 4 – 6 months



# 35-year-old gentleman with swelling since 4 – 6 months



35-year-old gentleman with swelling since 4 – 6 months

