


MICOD –14/08/2024

Case contributor – Dr. Harun Gupta

# MI-COD

MSS INDIA- Case Of the Day

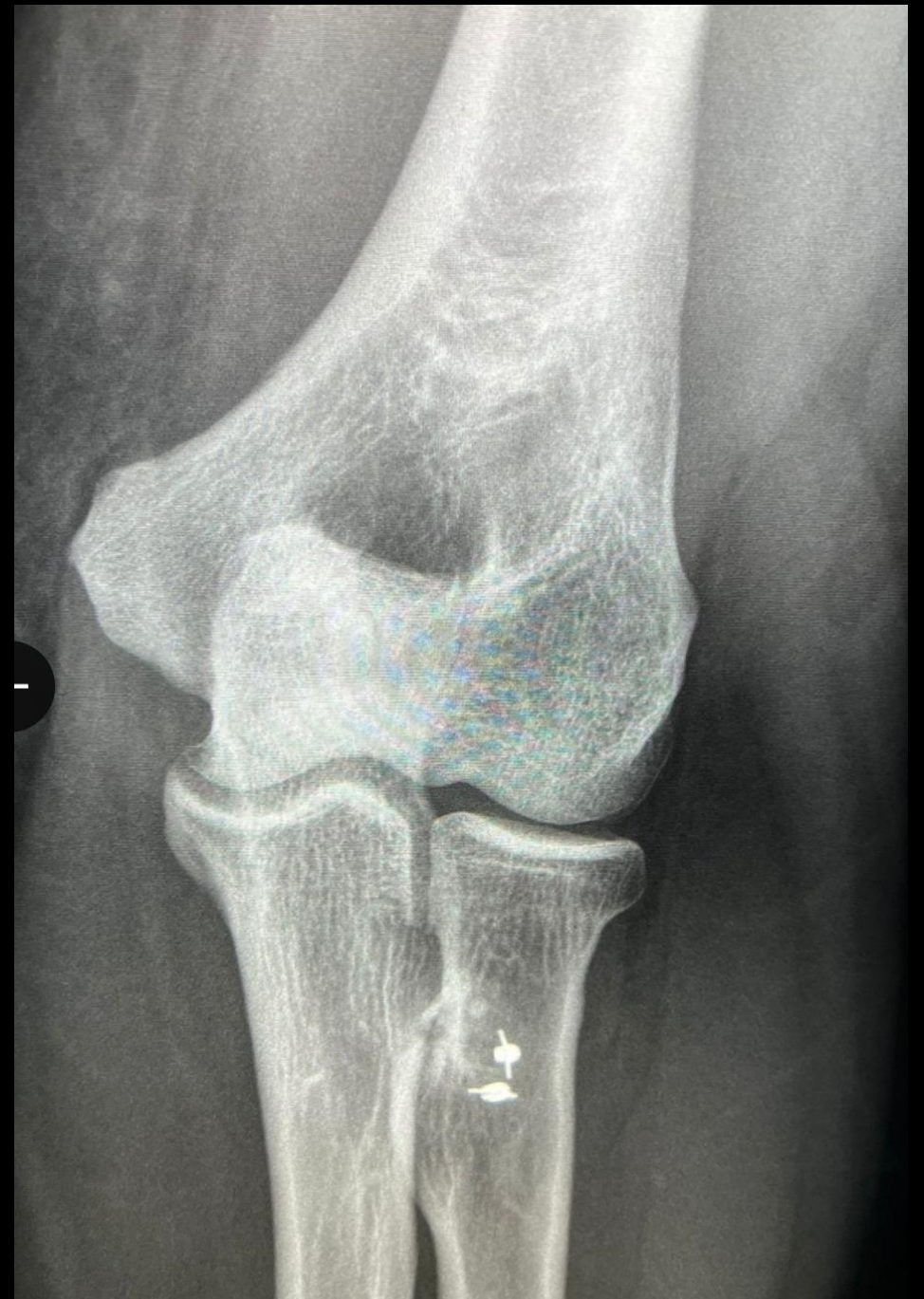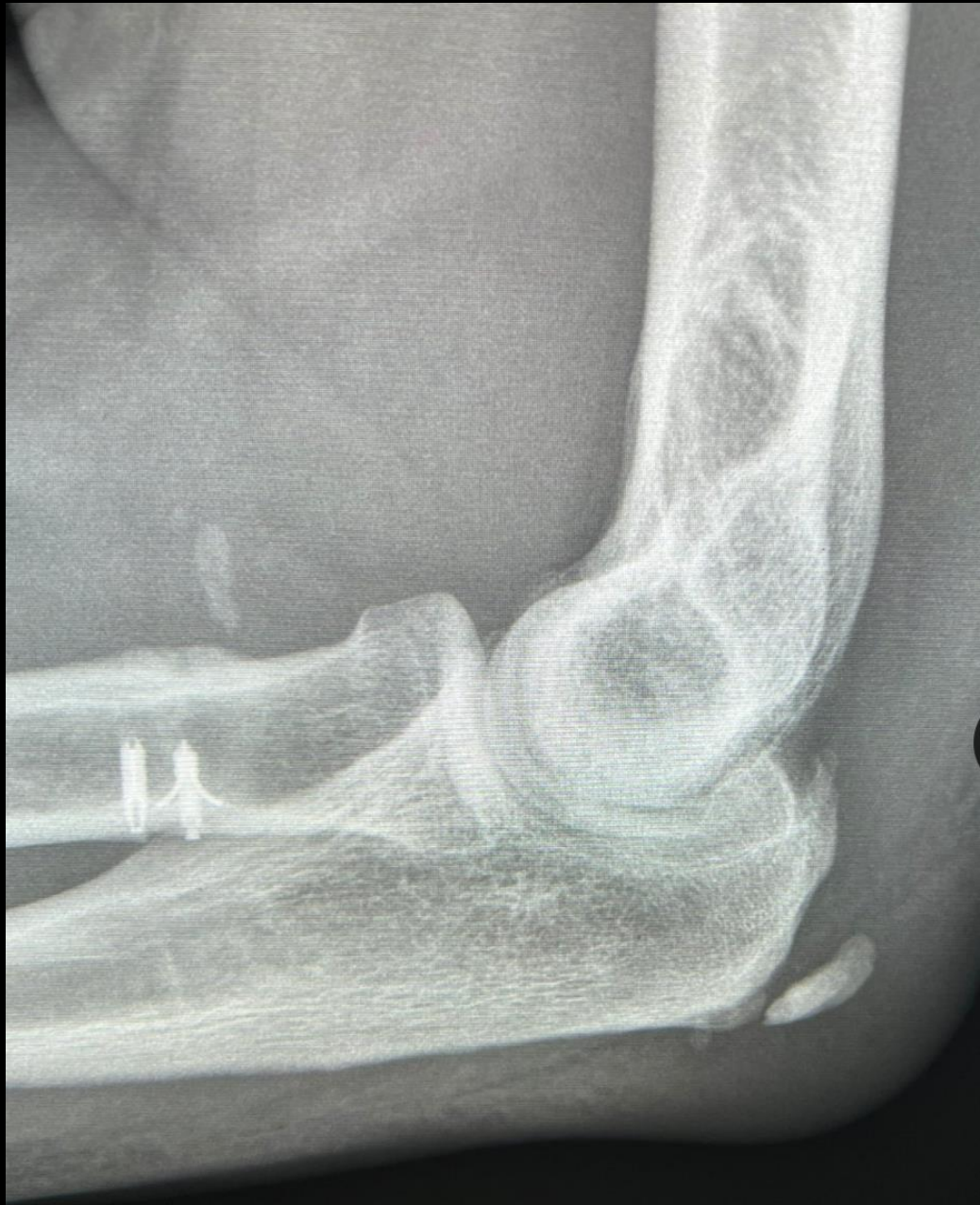


35 yr M

Power lifter

Previous elbow surgery

Now has acute posterior elbow pain !





What surgery was  
done??

What is the cause  
of present  
symptoms??