


MICOD –12/08/2024

Case contributor – Dr . Ankit Shah

# MI-COD

MSS INDIA- Case Of the Day

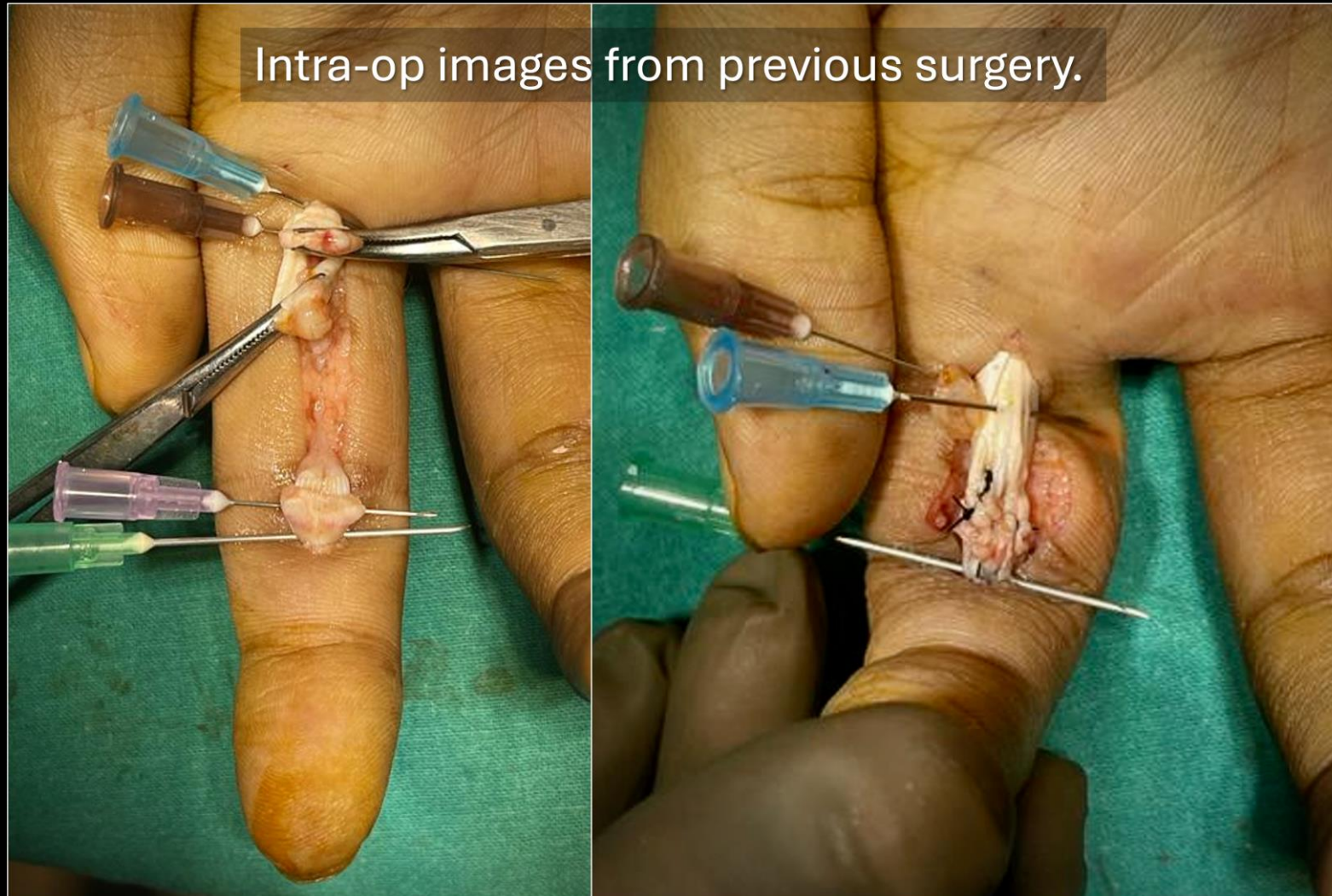


23 yr/M with **restricted flexion** of the index finger.  
The patient has been **operated for a penetrating inju**



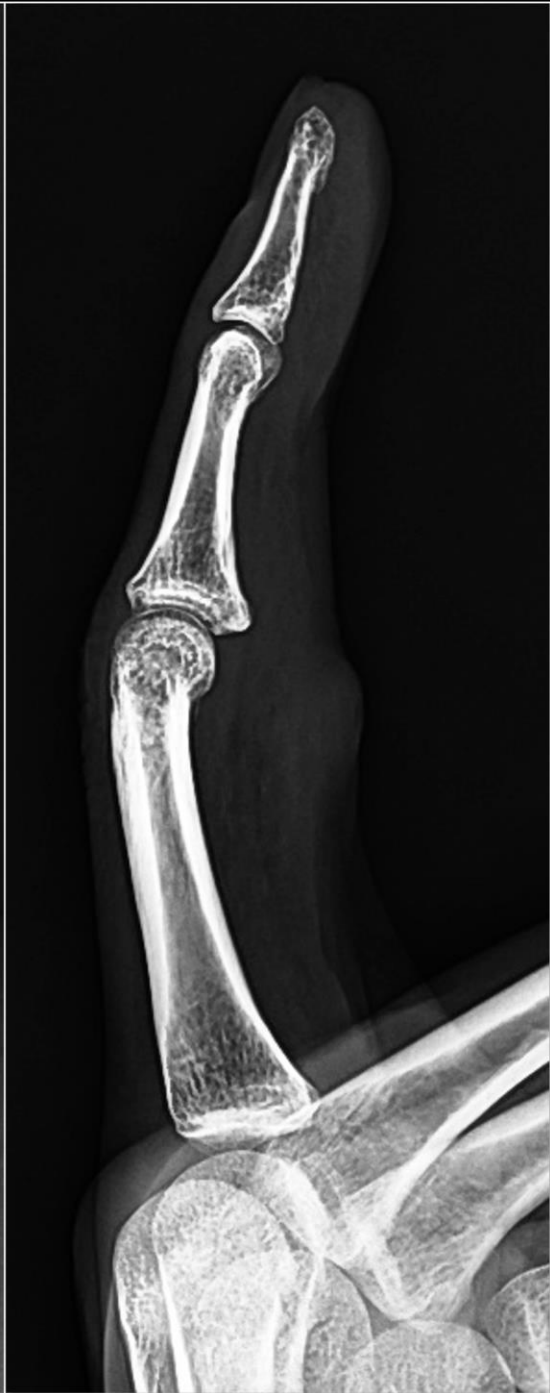
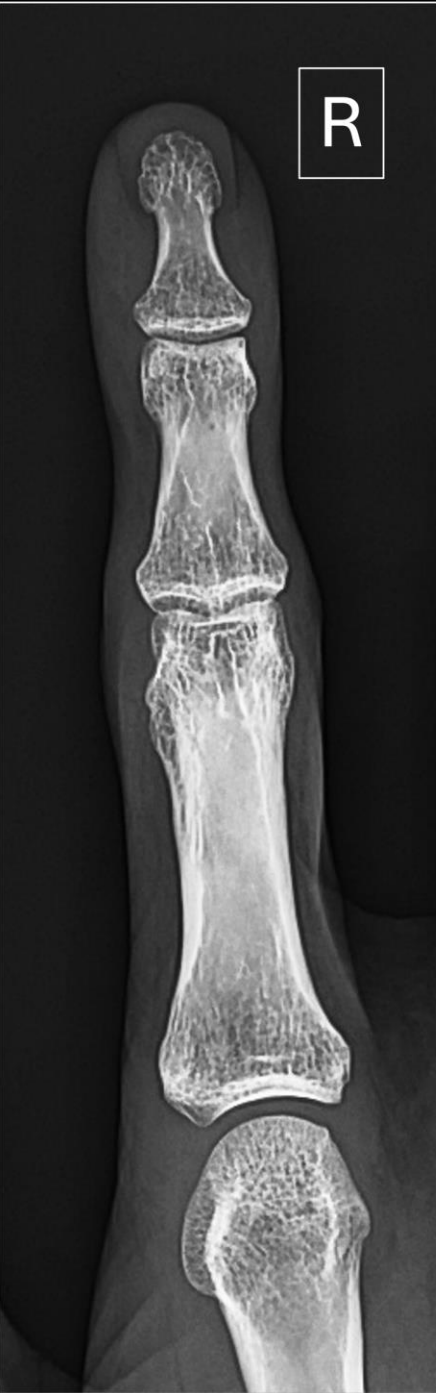
Intra-op pictures from the previous surgery (provided Surgical notes were not available for correlation.

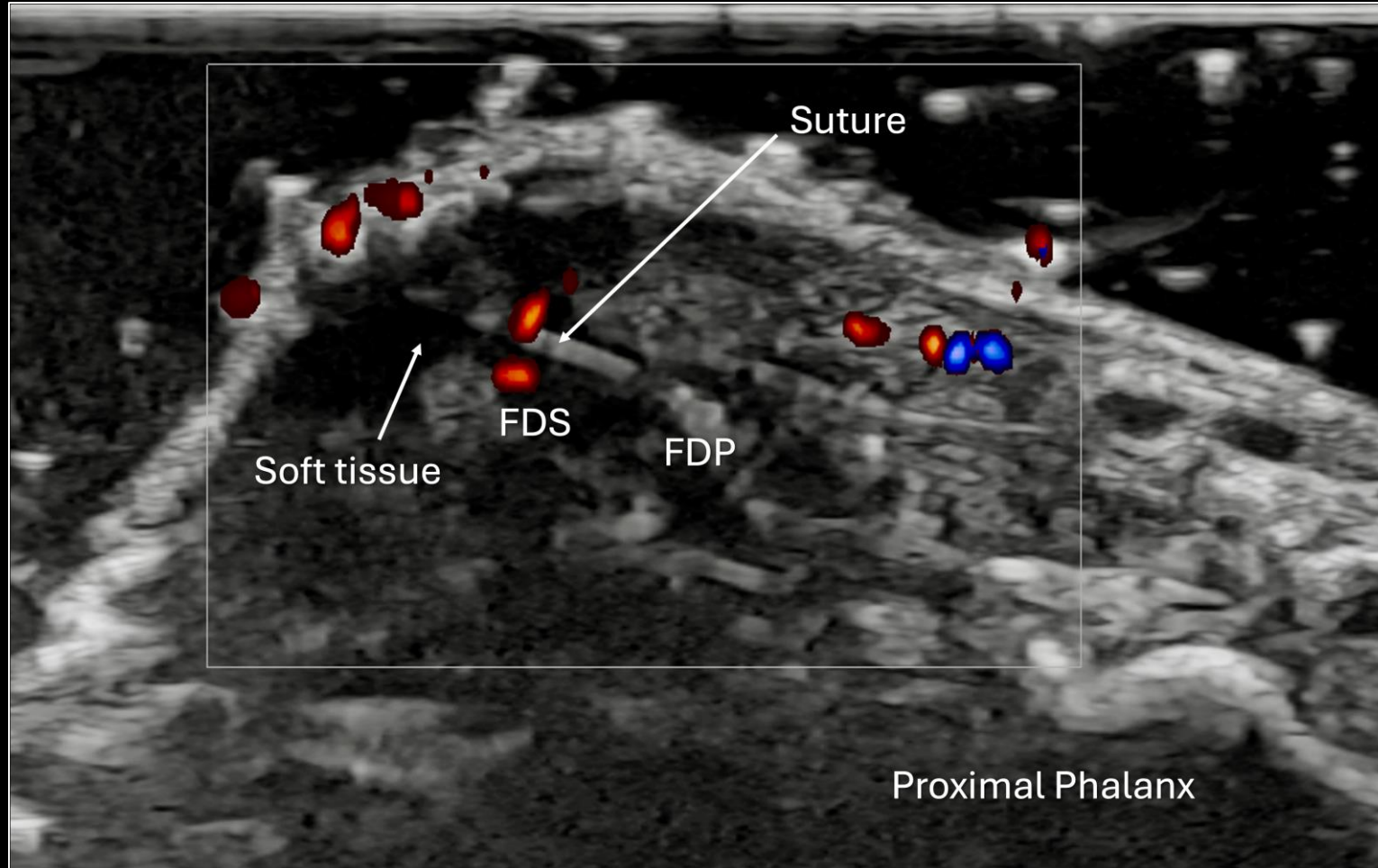


## Indications for ultrasound:

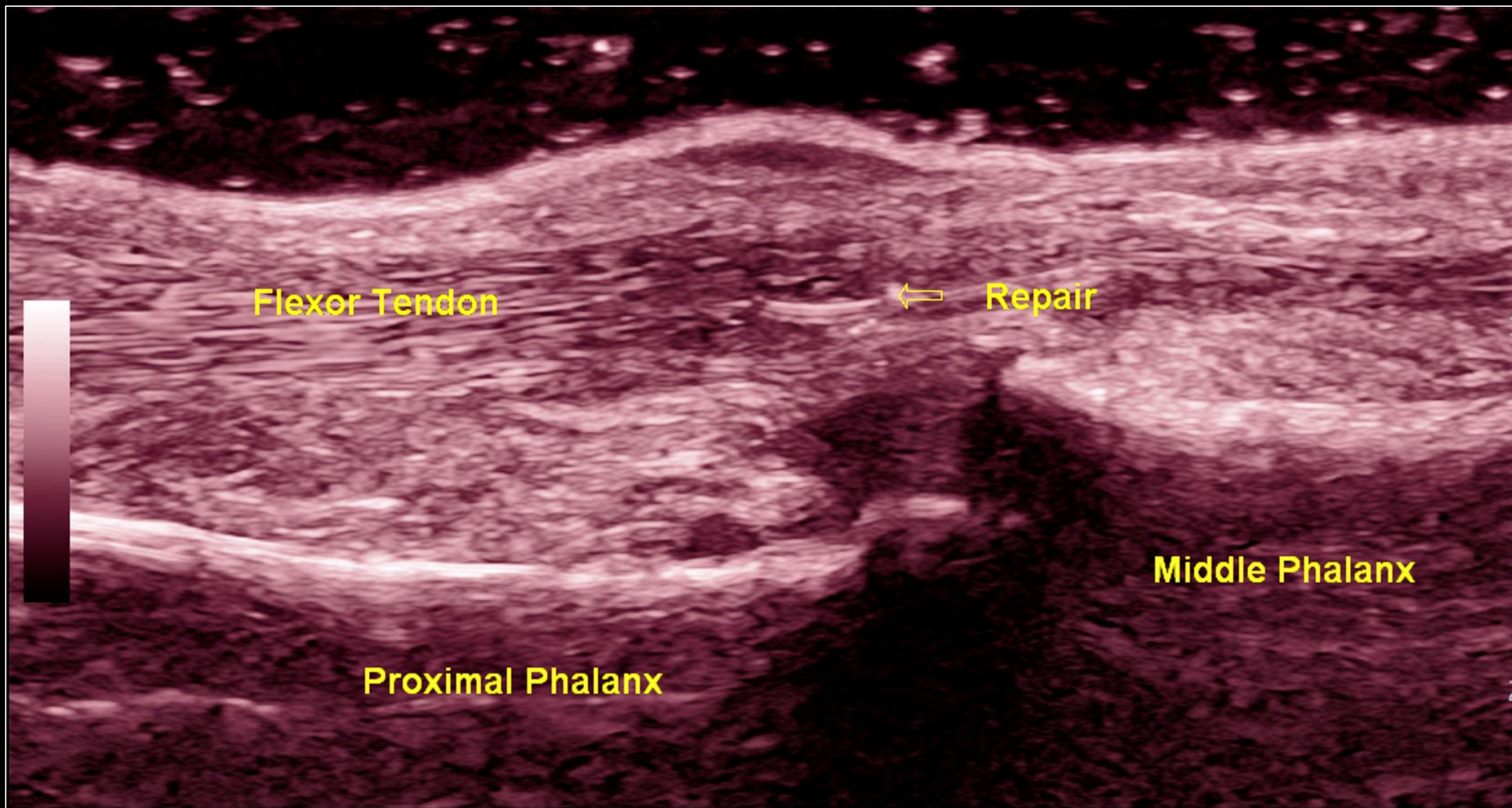
- a) Assess the status of repaired tendons.
- b) Look for peritendinous adhesions.
- c) Determine the possible cause of restricted flexion.



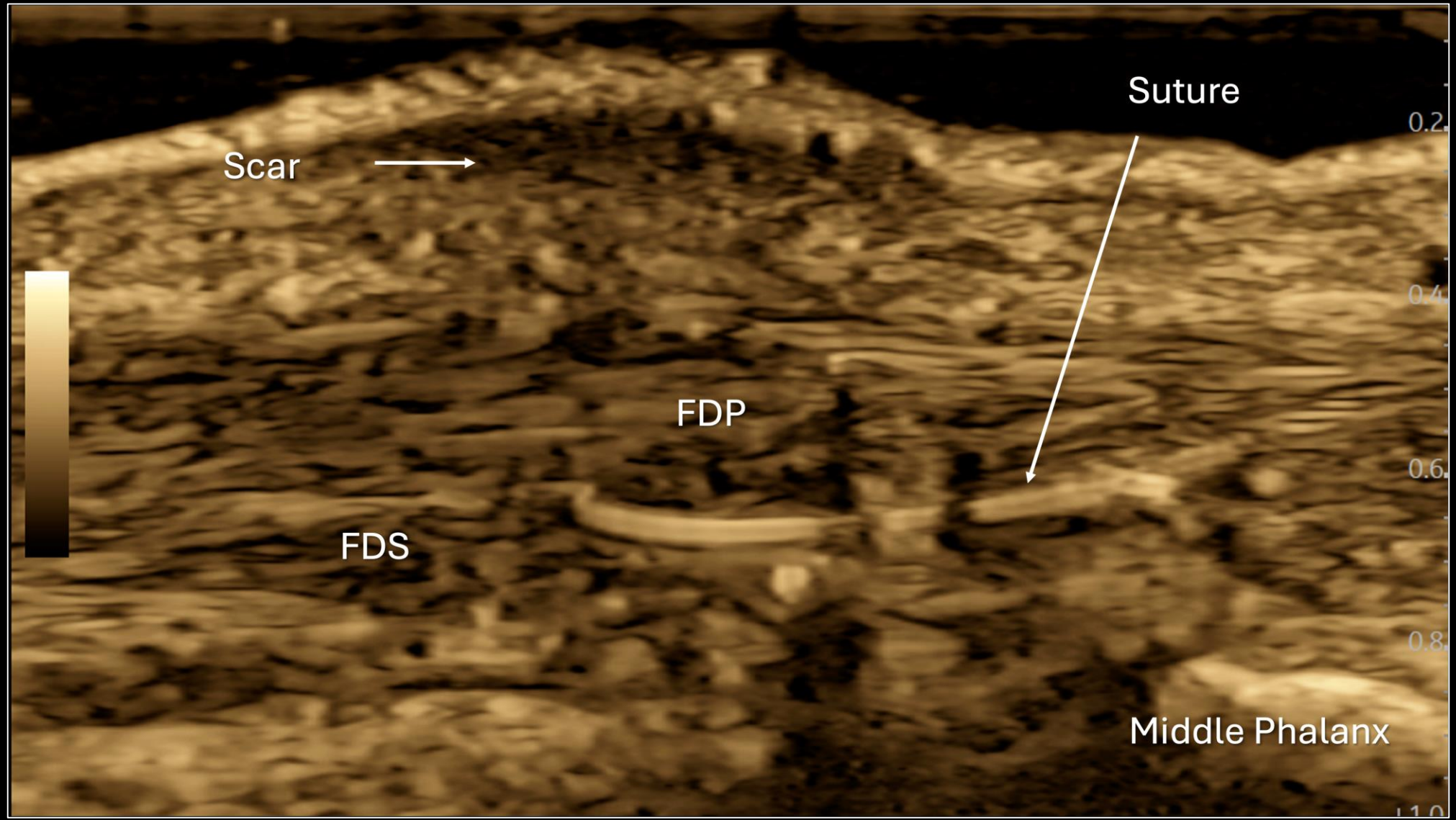
Axial image at the site of palpable nodule.



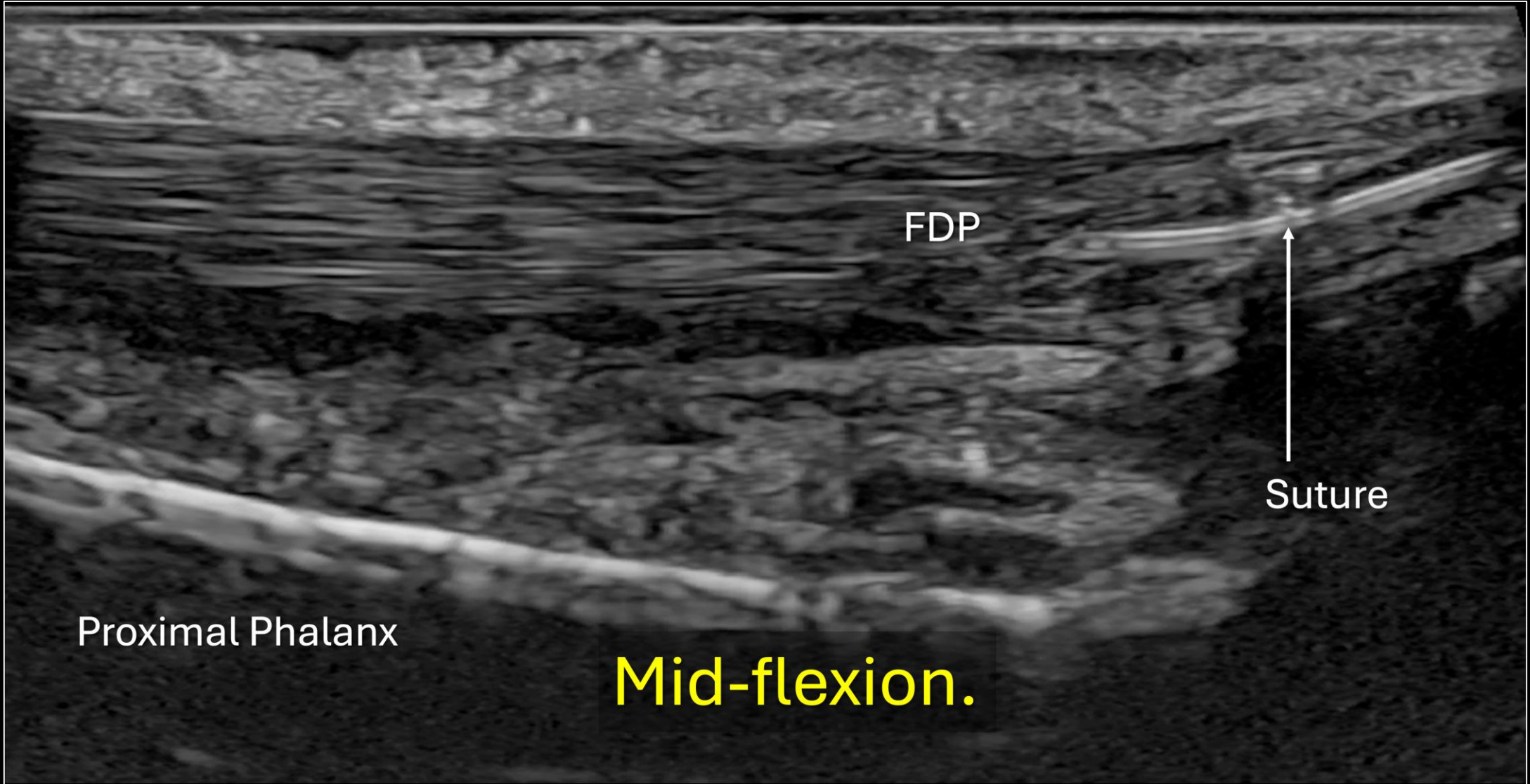










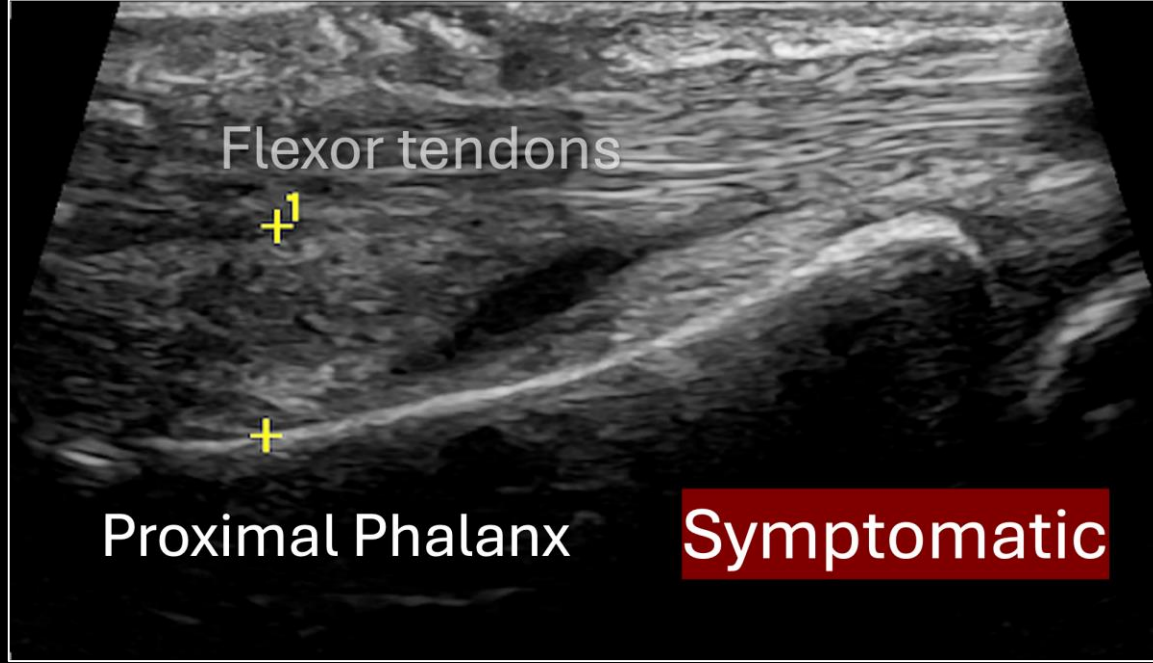


FDP

Suture

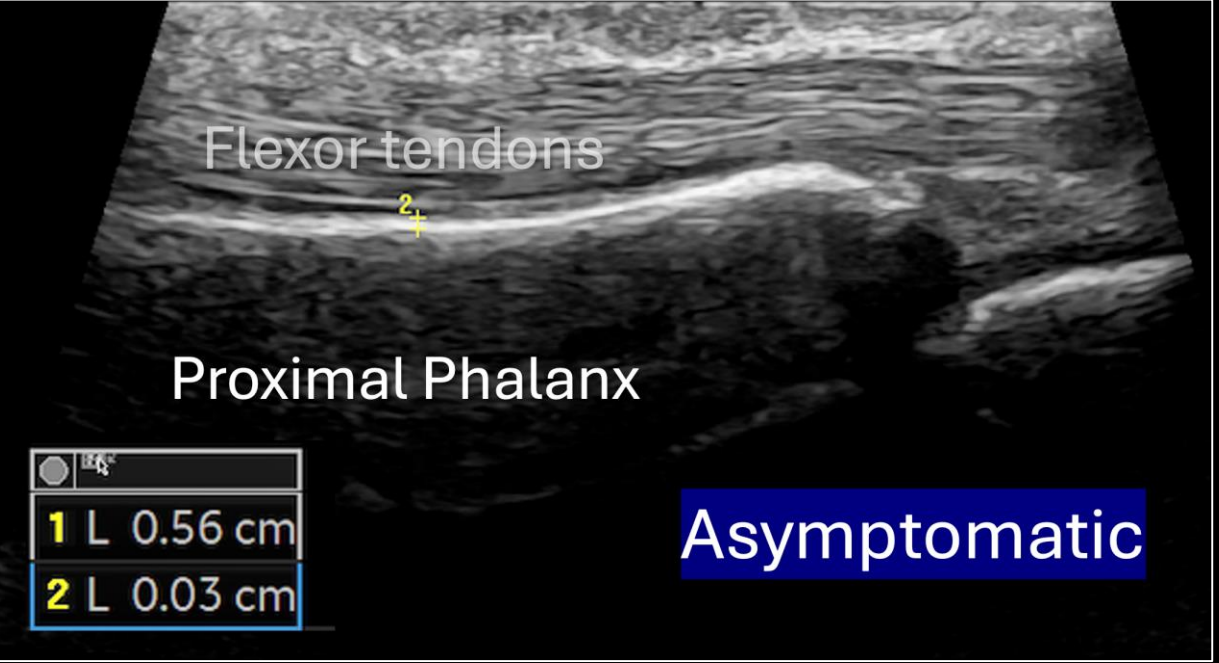
Proximal Phalanx

Mid-flexion.



**Symptomatic**

1	L	0.56 cm
2	L	0.03 cm



**Asymptomatic**



What is the most likely cause of restricted flexion?

A. Peritendinous adhesions.

B. Flexor tenosynovitis.

C. A2 pulley injury.

D. Retear of the flexor digitorum superficialis tendon.