

MICOD – 09.08.2024

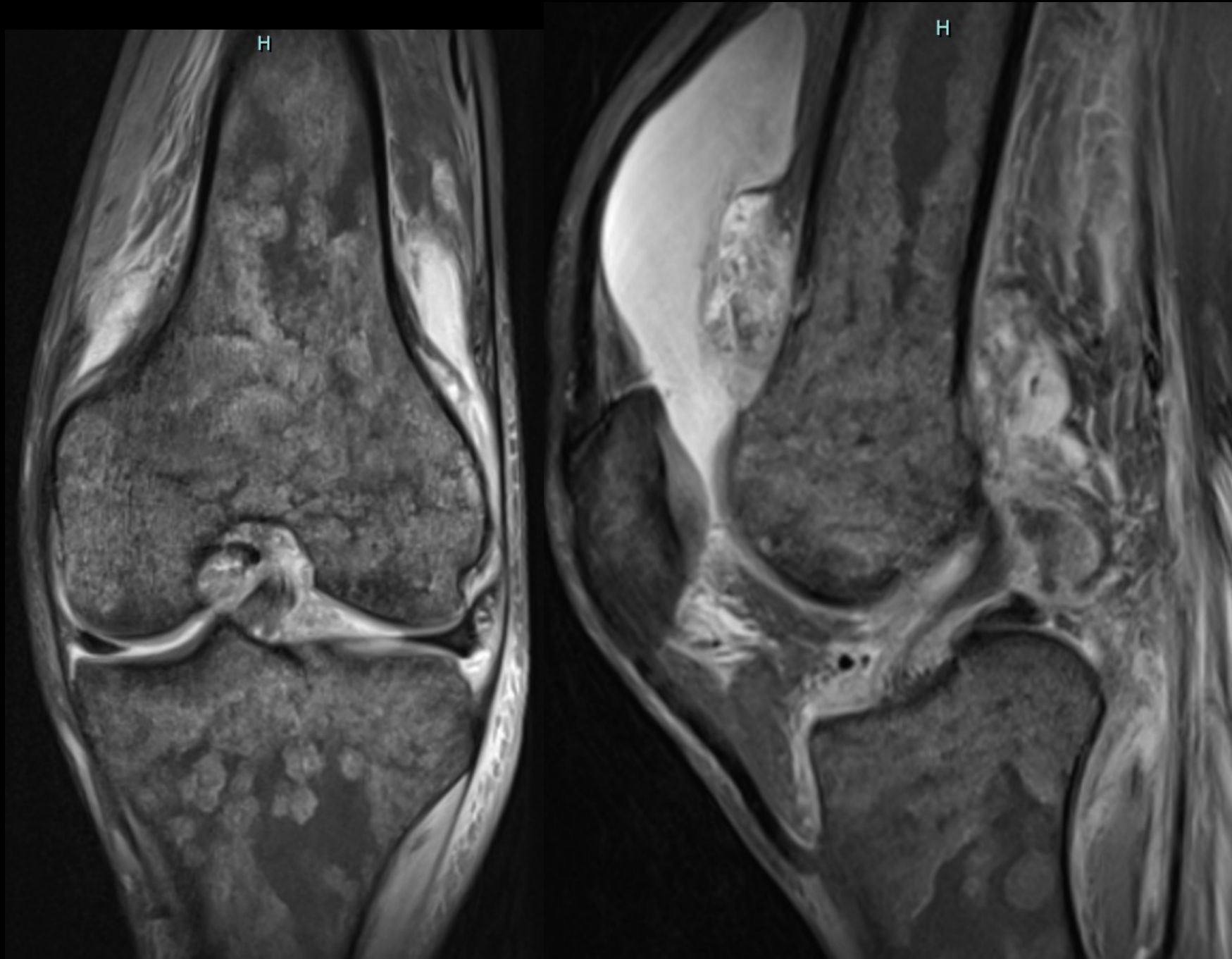
Case contributor – Dr. Darshana Sanghvi

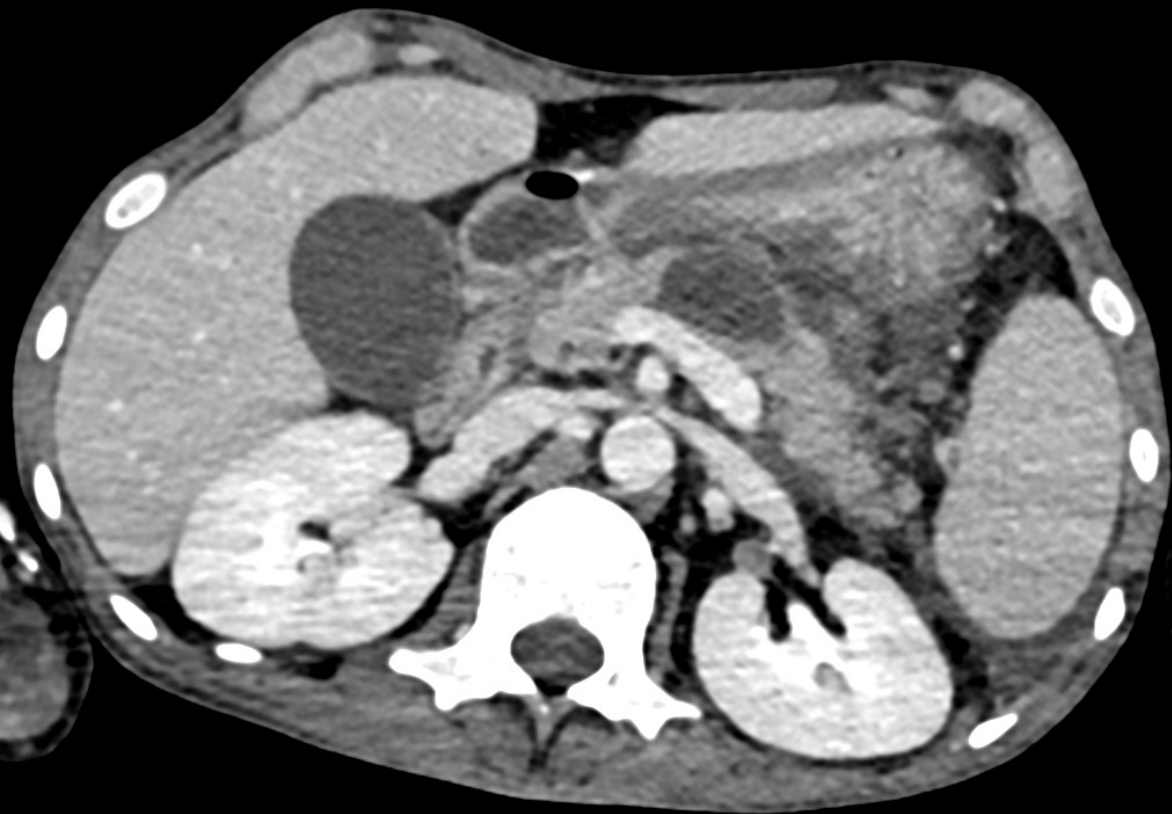MI-COD

MSS INDIA- Case Of the Day



30/M with joint & abdominal pain





L R

