

MICOD – 05/08/2024

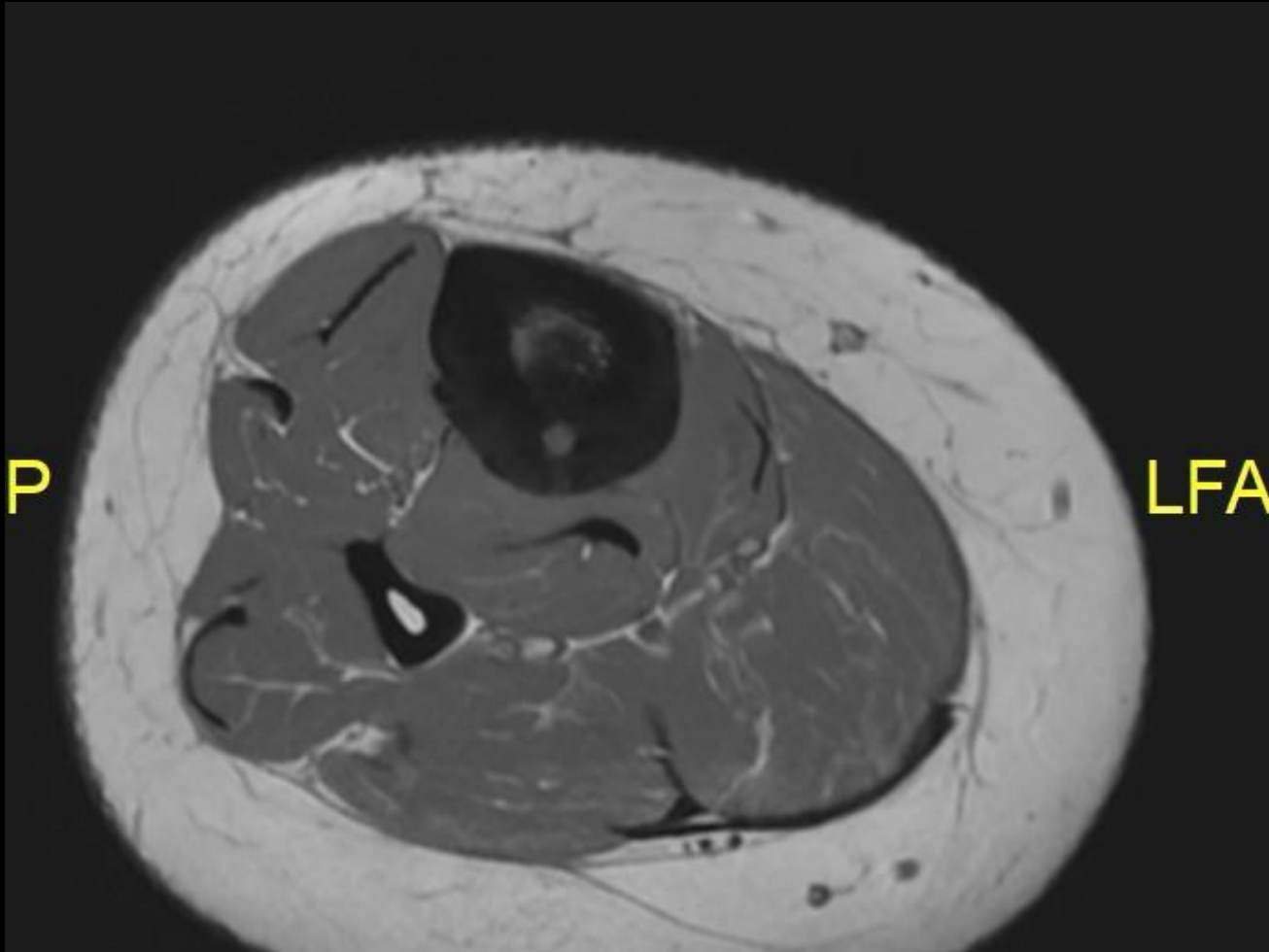
Case contributor – Dr. Rajesh Botchu

MI-COD

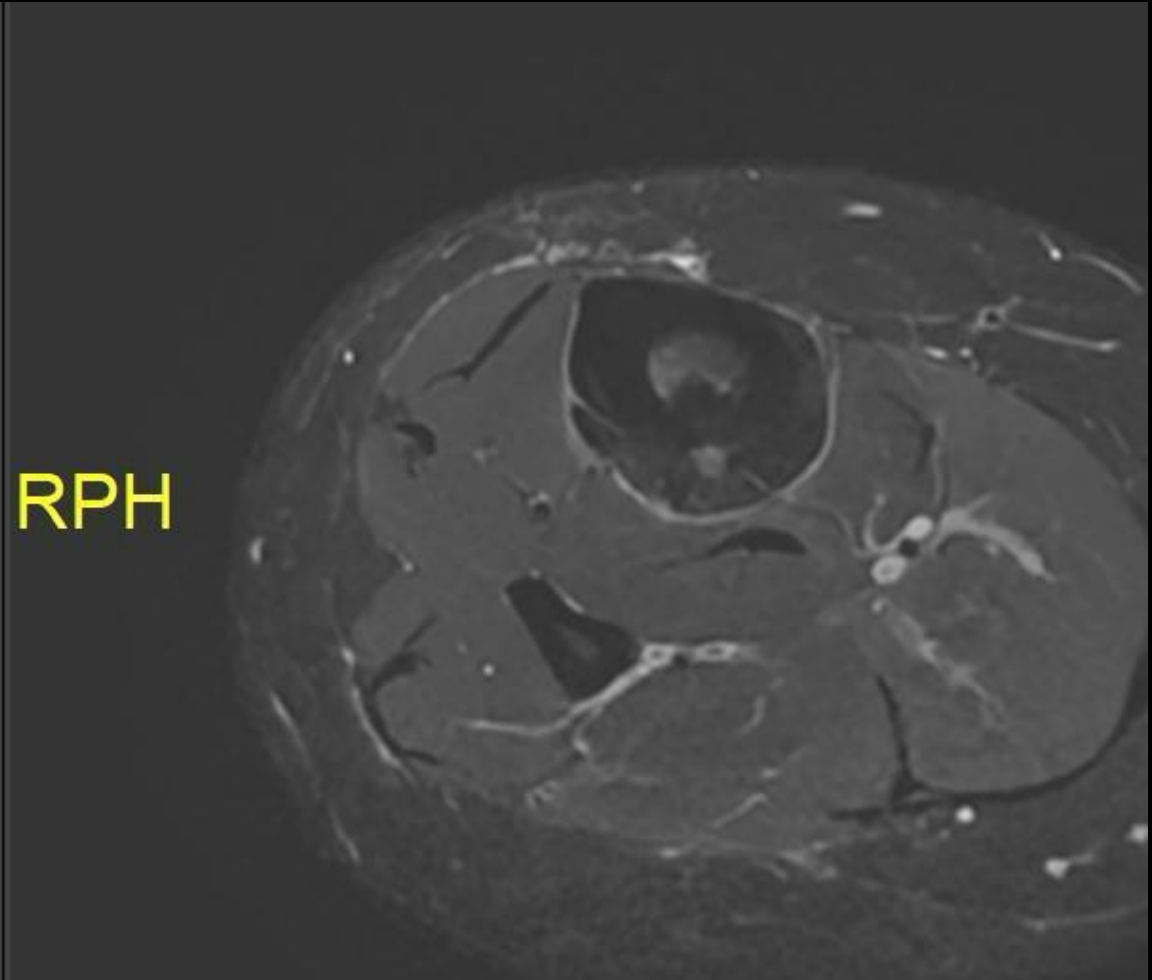
MSS INDIA- Case Of the Day



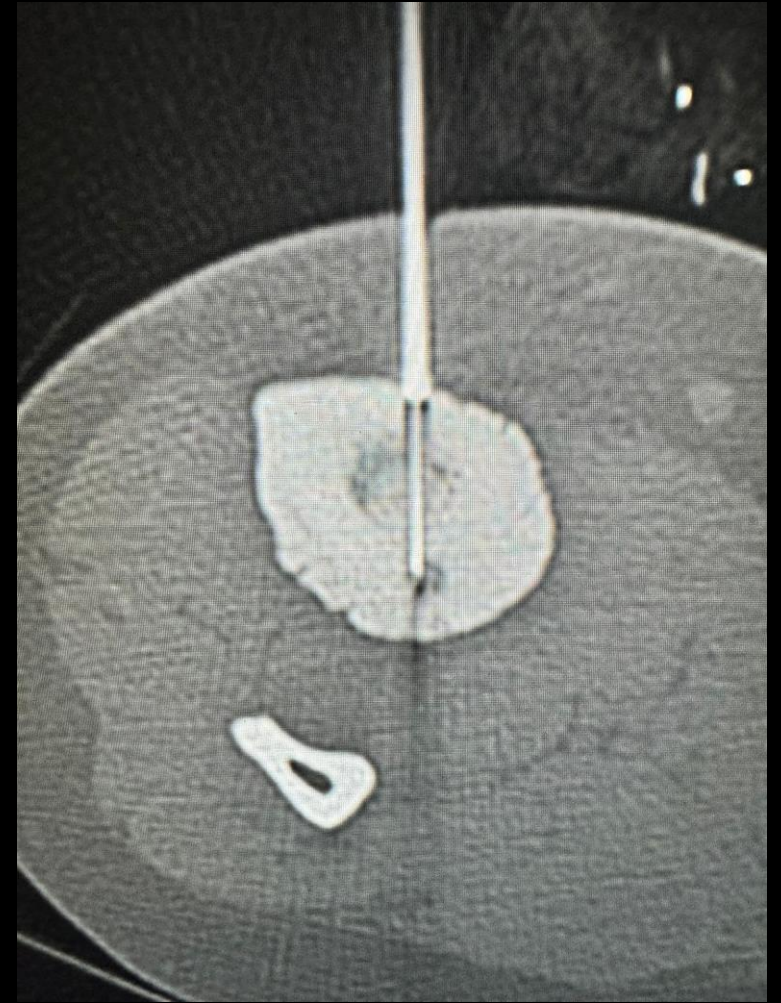
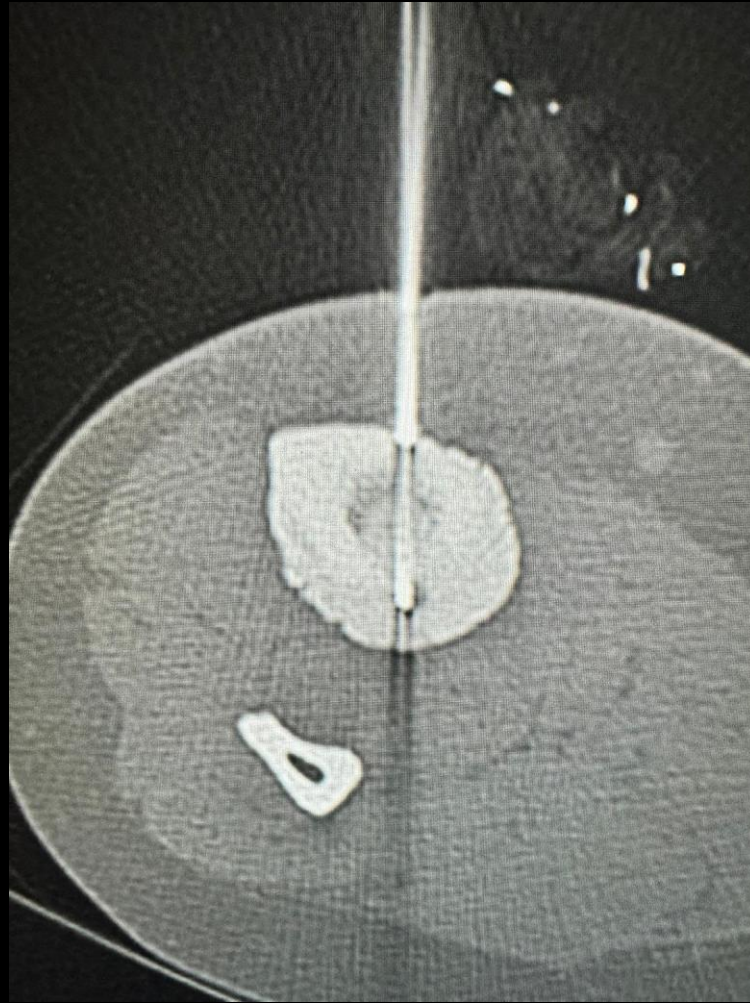
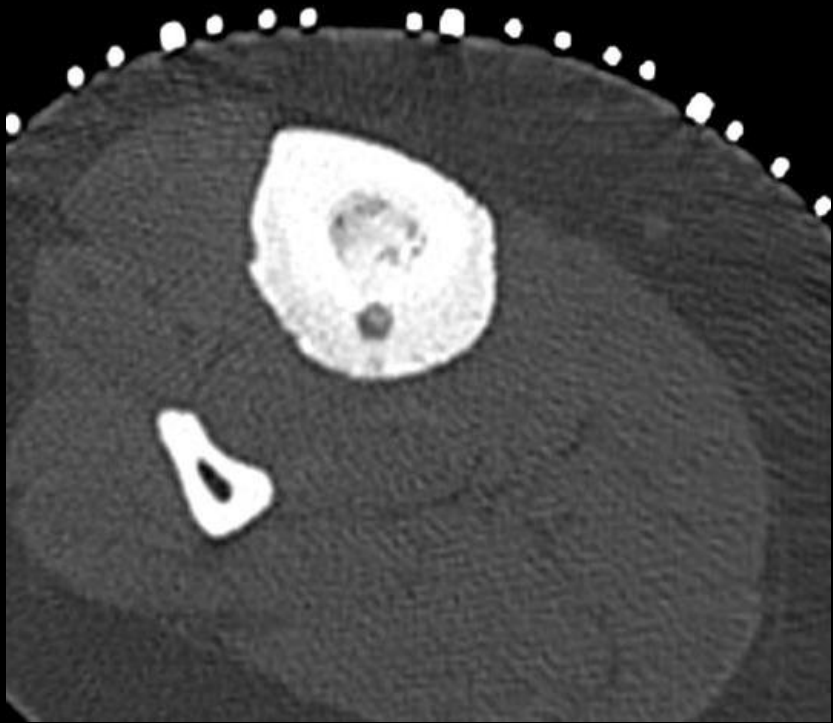
Osteoid osteoma and RFA next



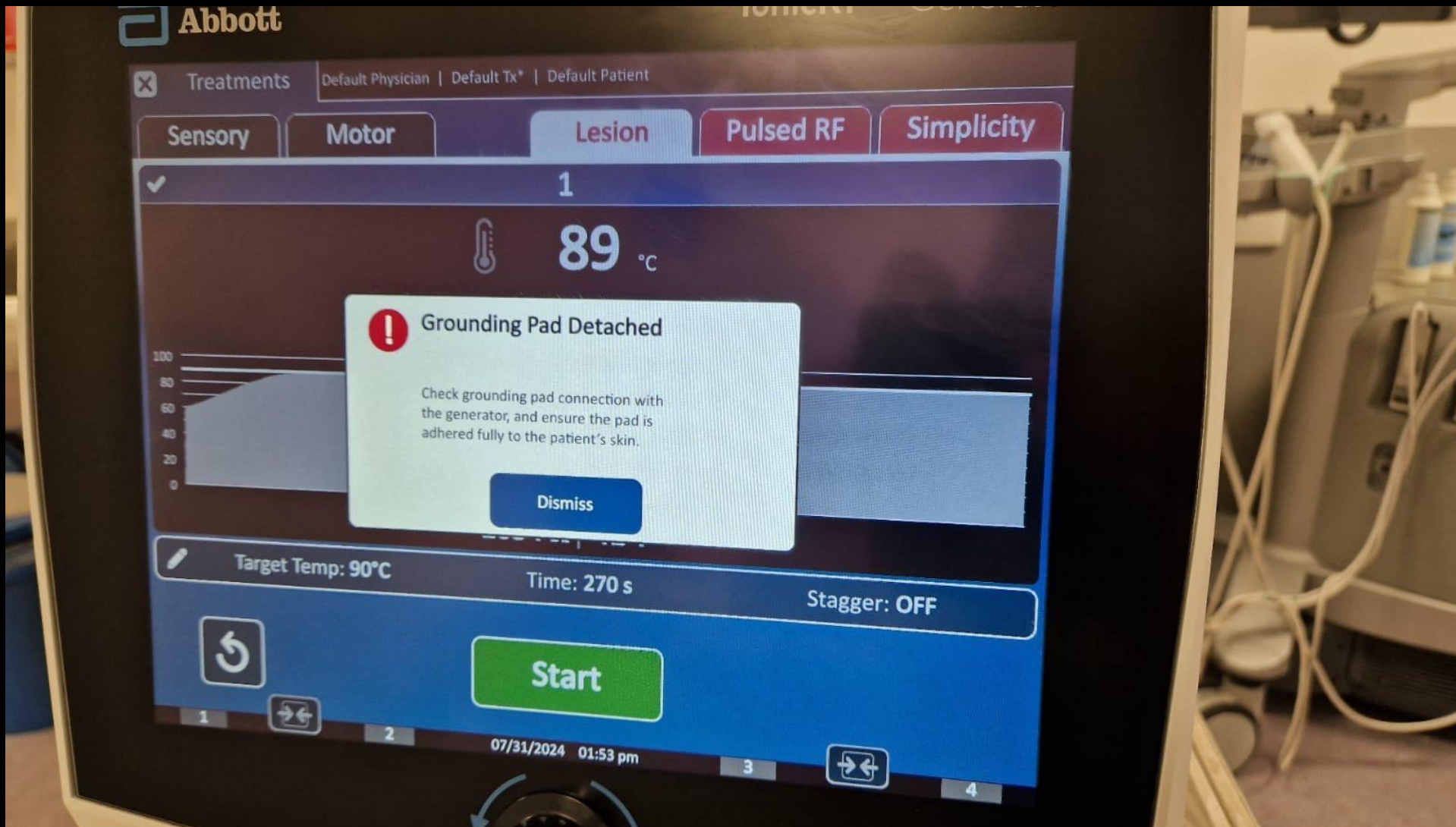
LFA RPH



During the procedure



Repeated error messages pop out in spite changing the device multiple times



What next?