


MICOD – 02/08/2024

Case contributor – Dr. Rajesh Botchu

MI-COD

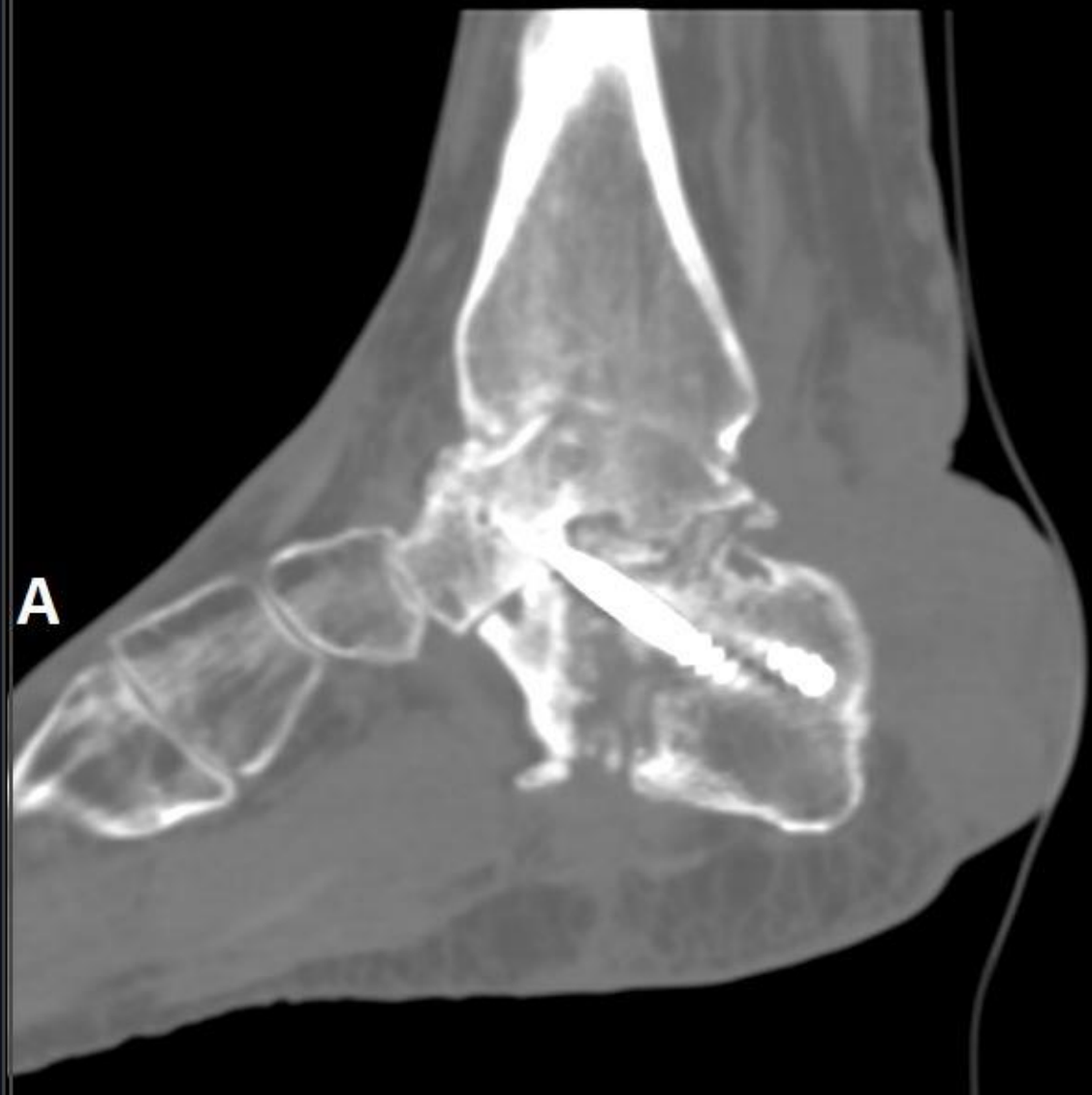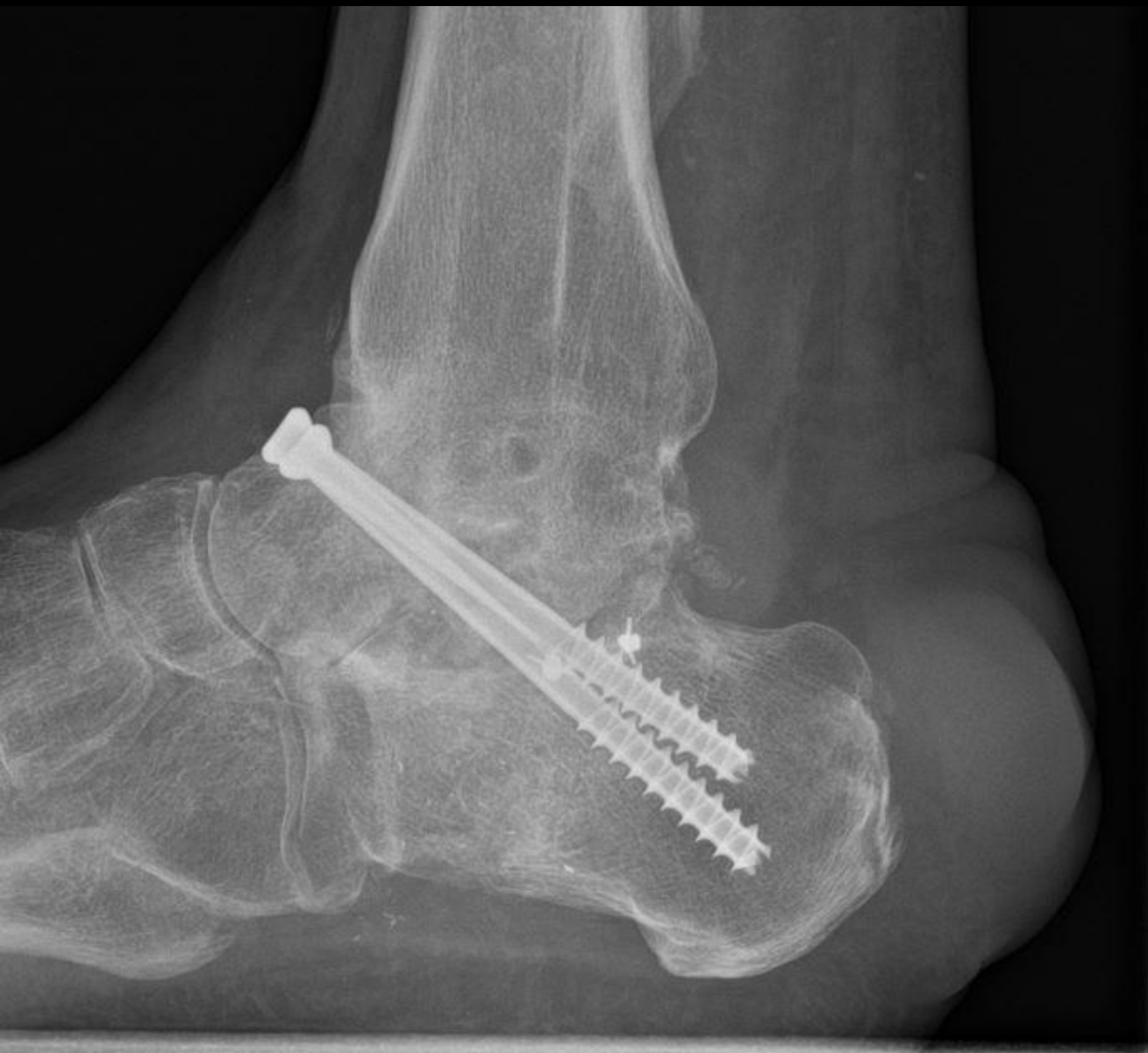MSS INDIA- Case Of the Day

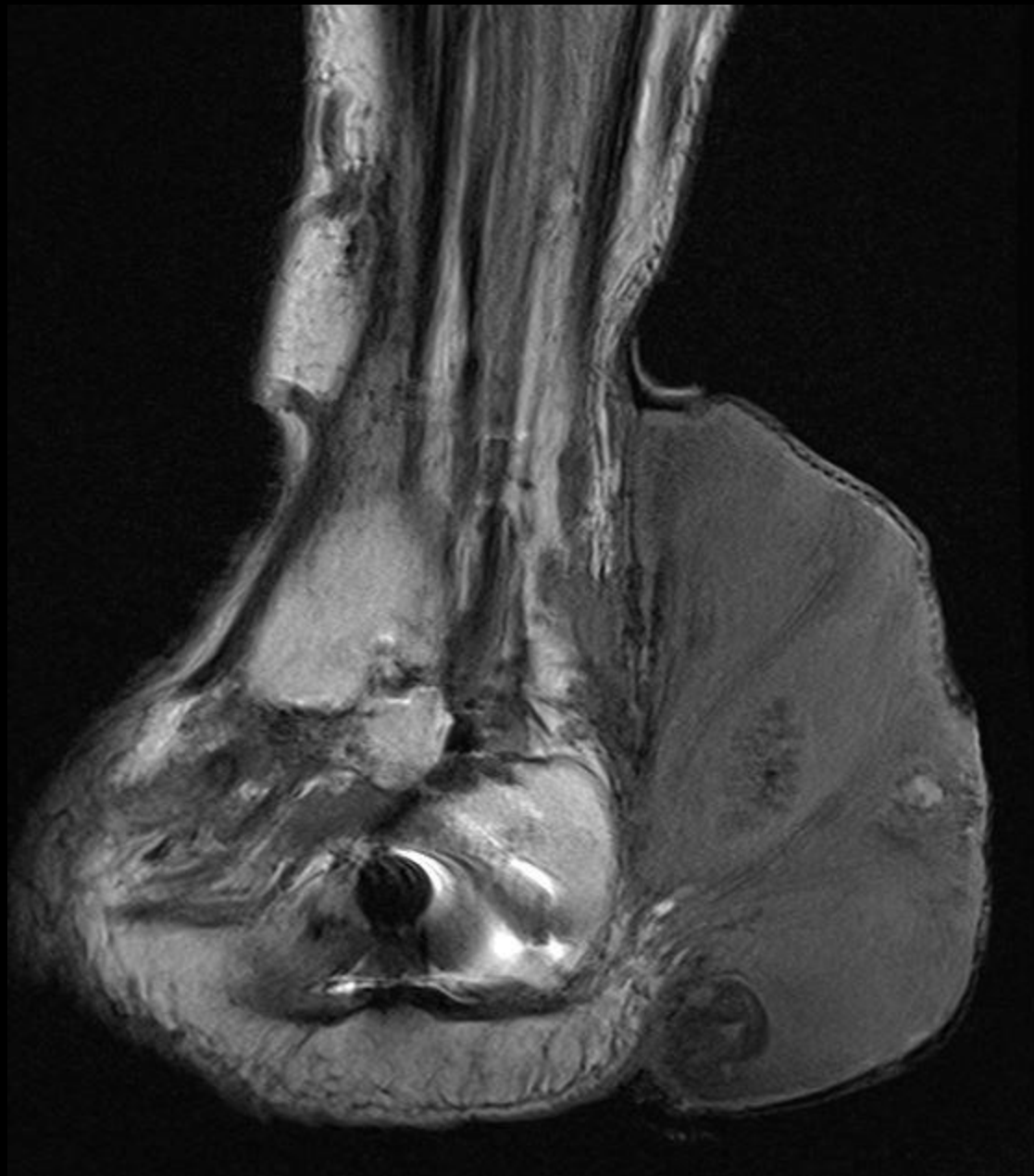




➤ Swelling at posterior aspect of ankle







PR AL

