


MICOD – 01/08/2024

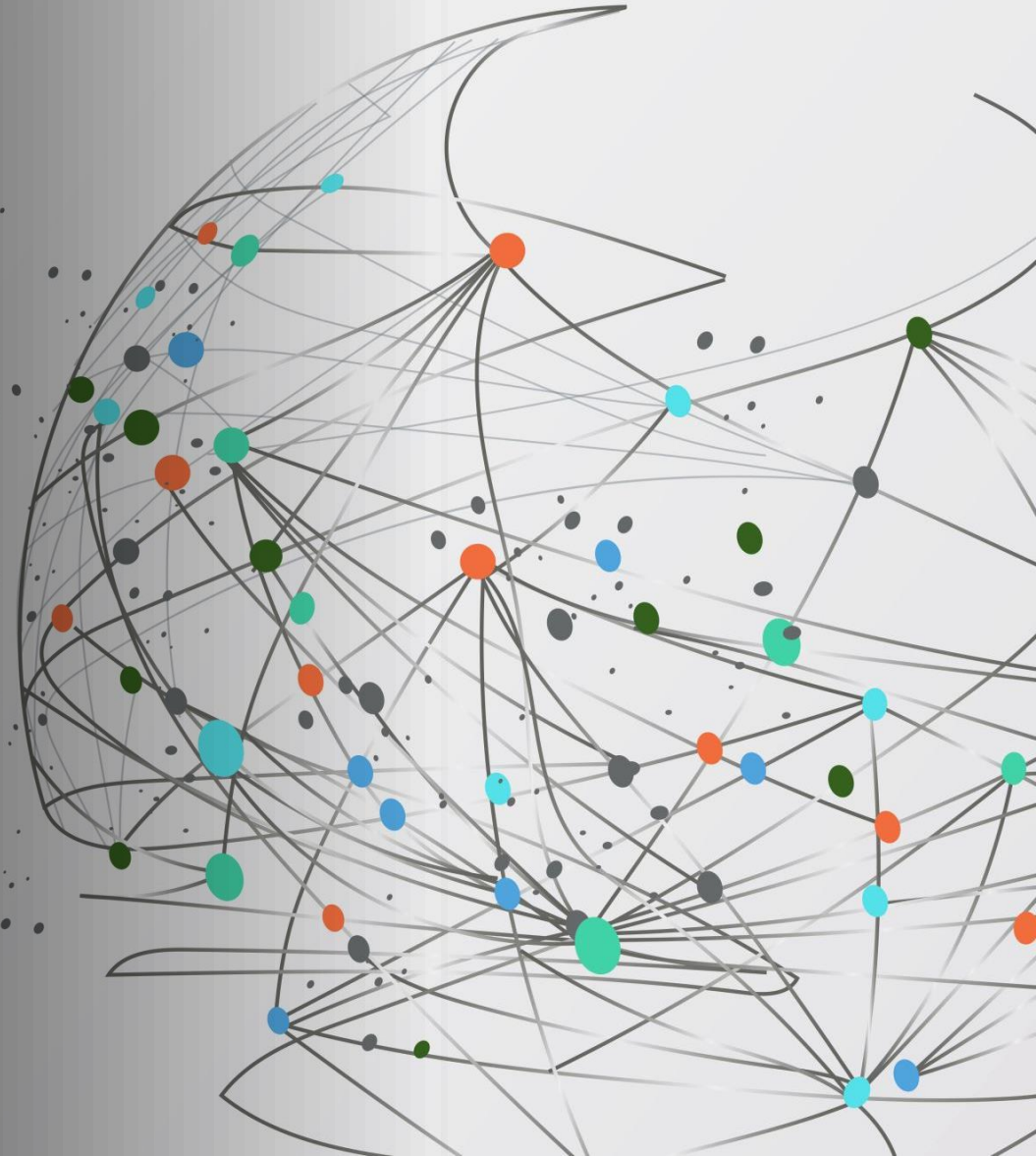Case contributor – Dr. Rajesh Botchu

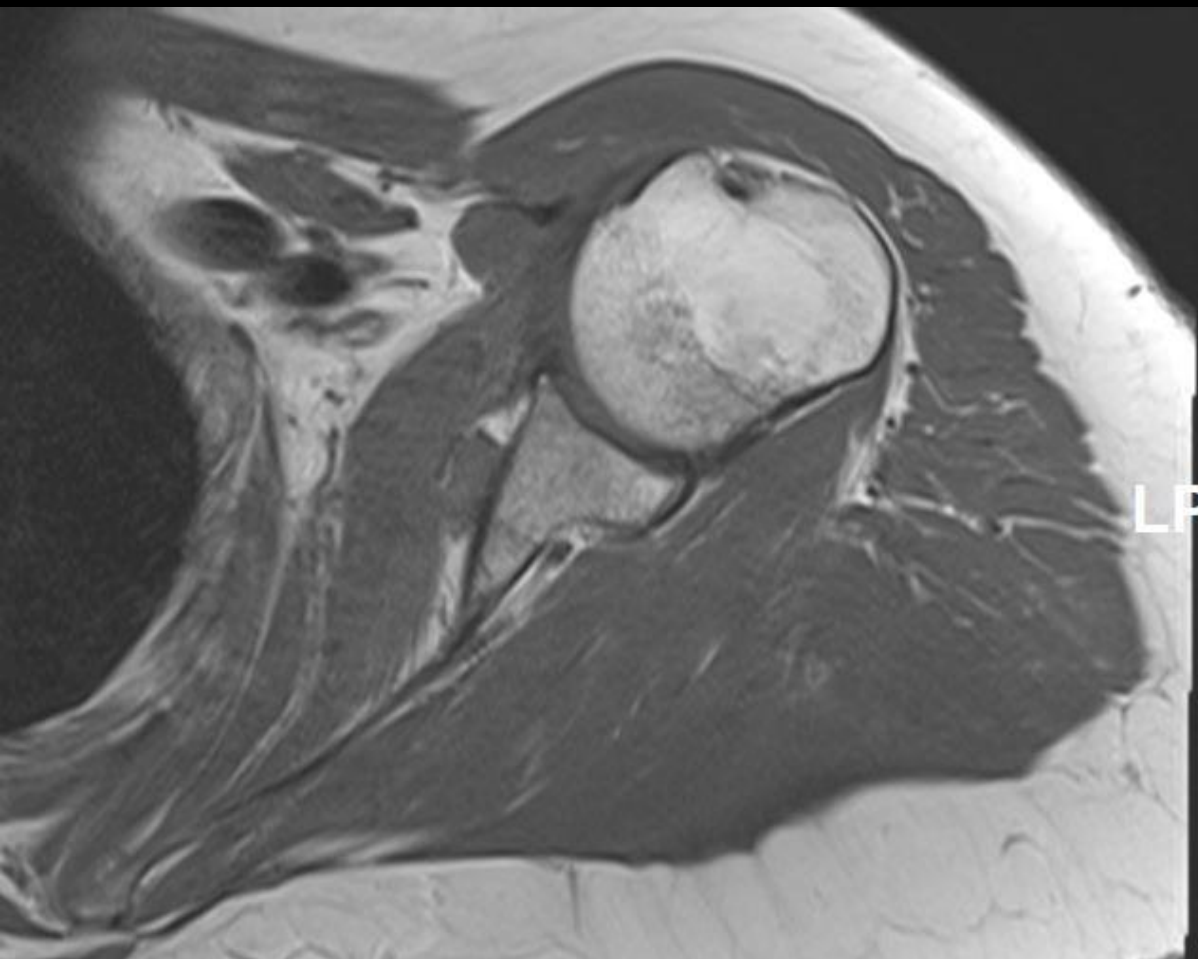
MI-COD

MSS INDIA- Case Of the Day



- 
- Patient presented with multiple fractures.
What are the differentials?
How would you biopsy it?





LP RA

