

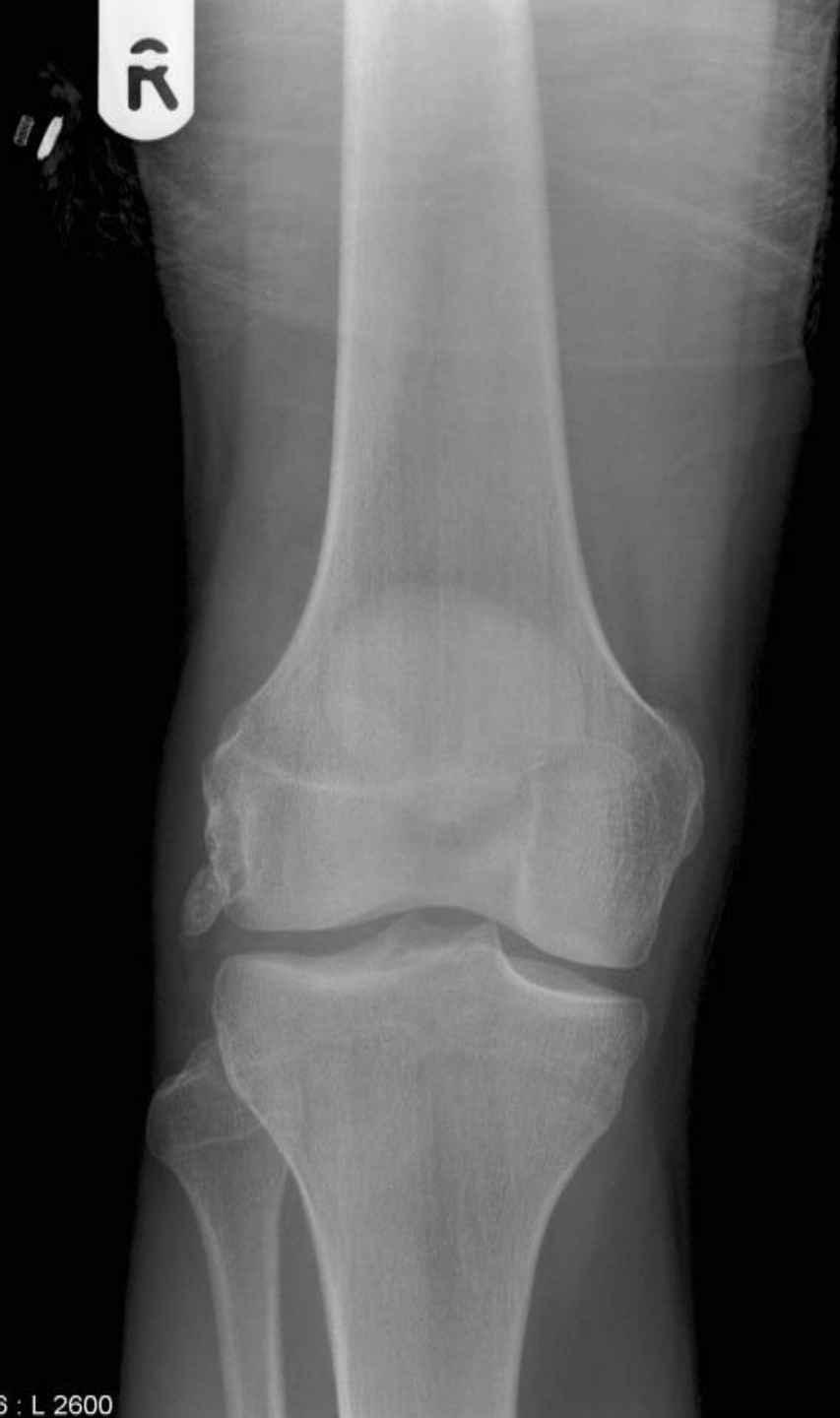
MICOD – 31/07/2024

Case contributor – Dr. Vijay Papineni

MI-COD

MSS INDIA- Case Of the Day

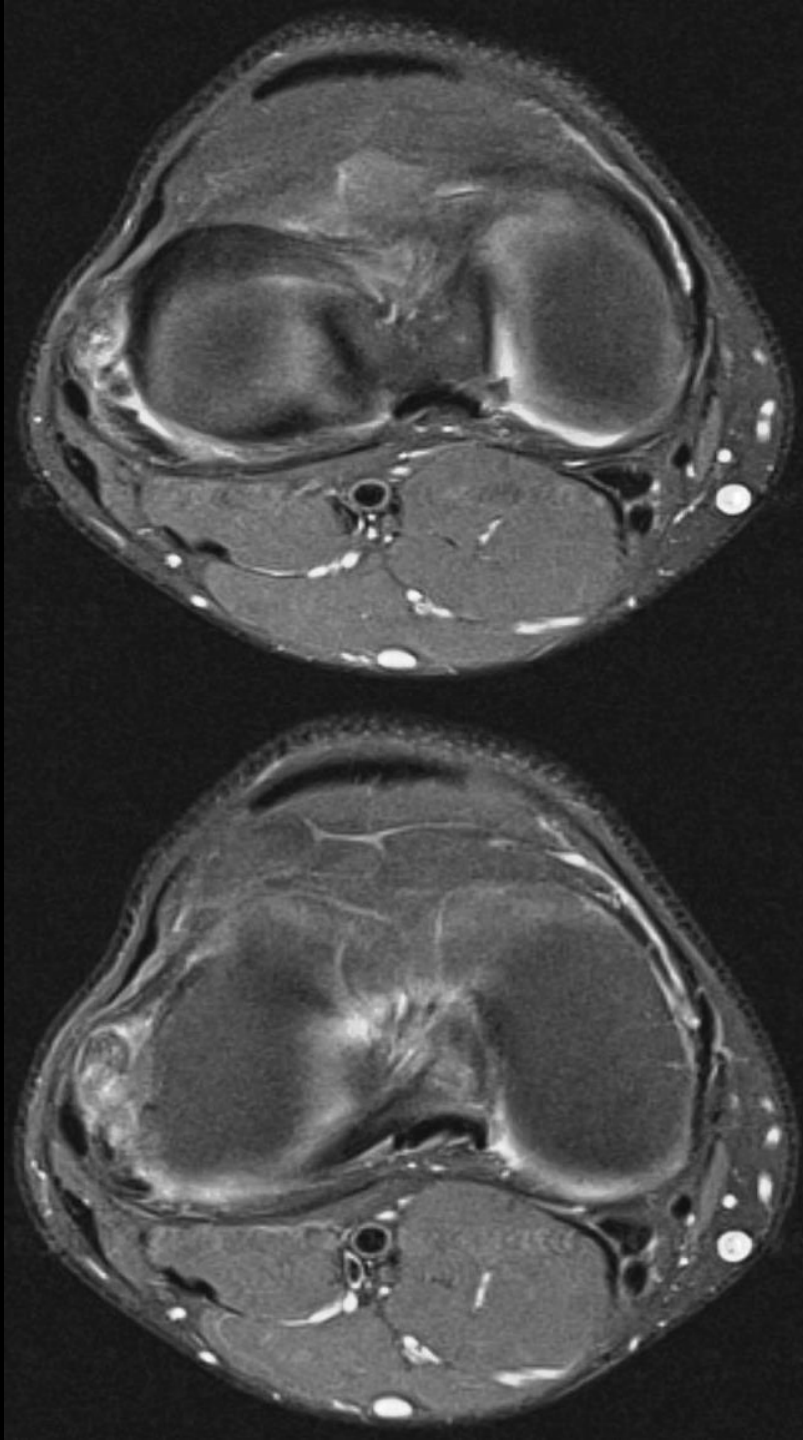
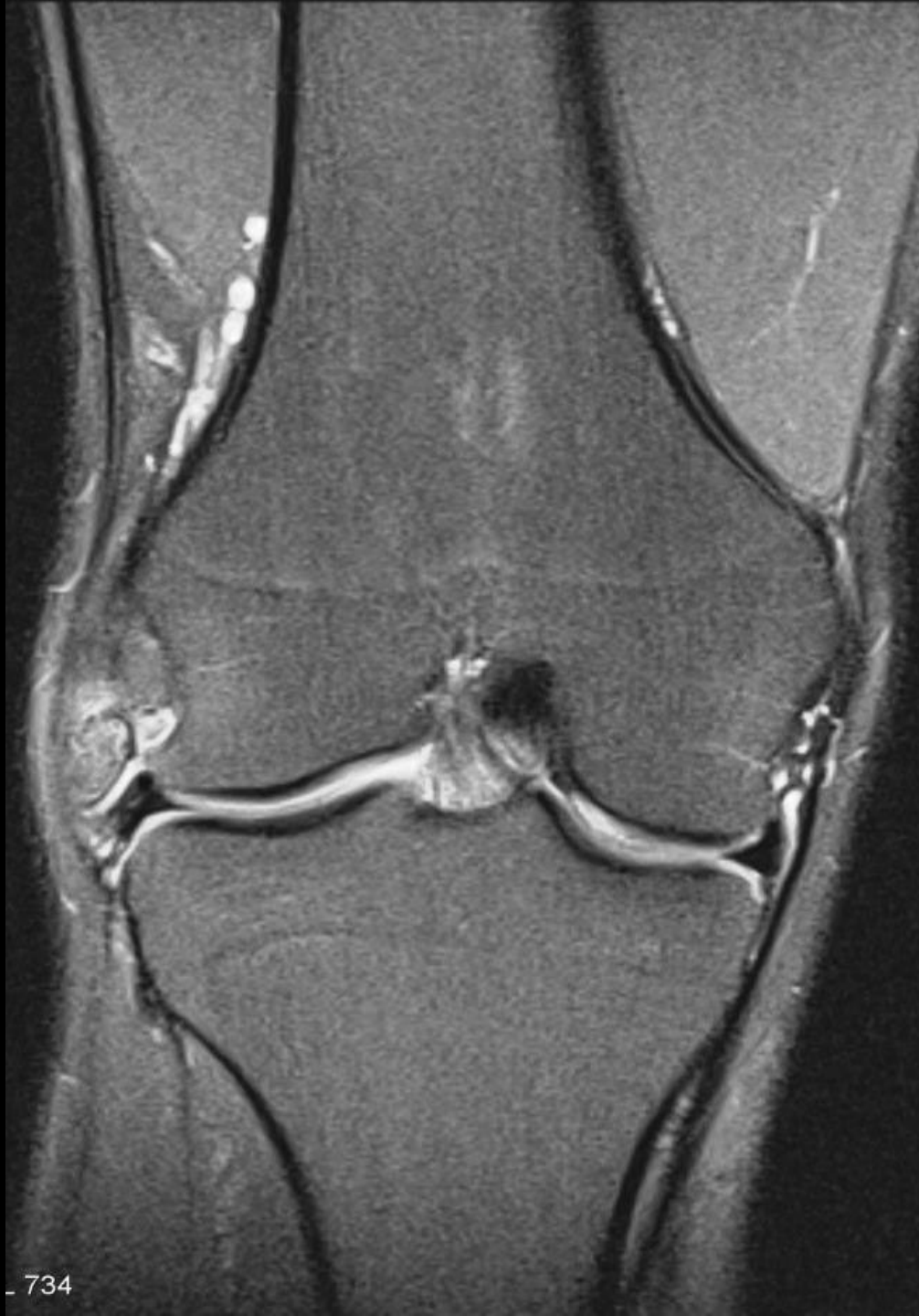



19-year-old gentleman presented with an acute onset of right knee pain after sustaining a twisting injury to this joint and simultaneous right ankle inversion injury whilst undertaking a recreational sporting activity.

Prior to this single episode of trauma sustained whilst running he described symptoms of pseudo-locking and clicking of 6-month duration.

The patient had, 7 years prior to presentation, undergone arthroscopy of the right knee for division of synovial plica in the medial compartment of the knee joint.



*Findings
&
possibilities?*