

MICOD – 24/07/2024

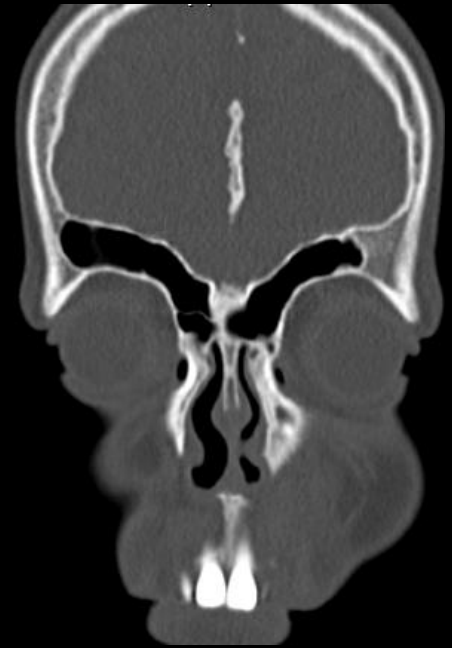
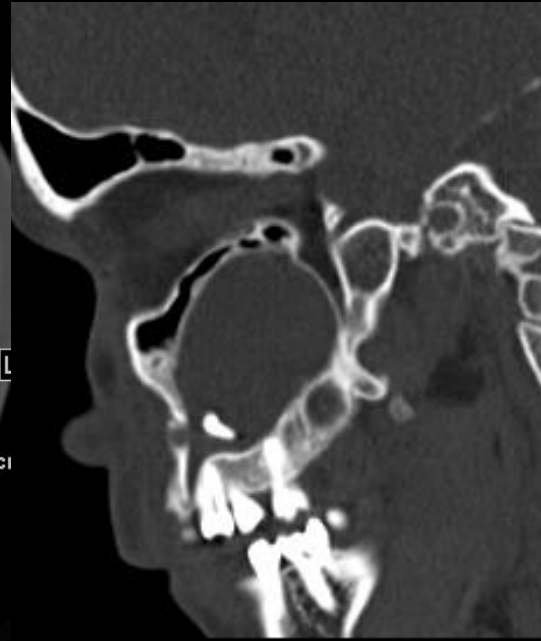
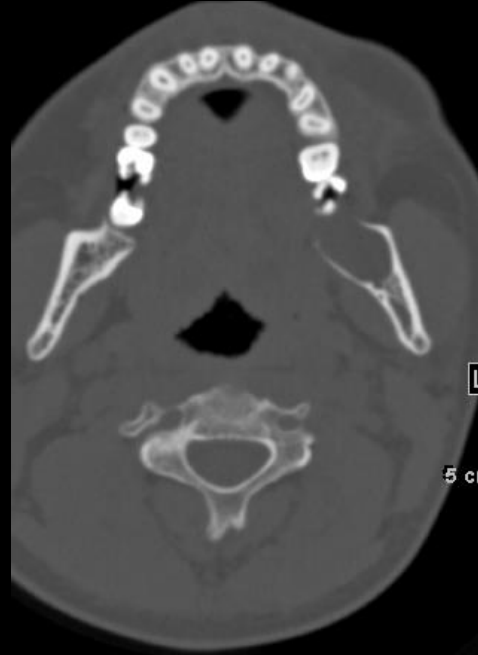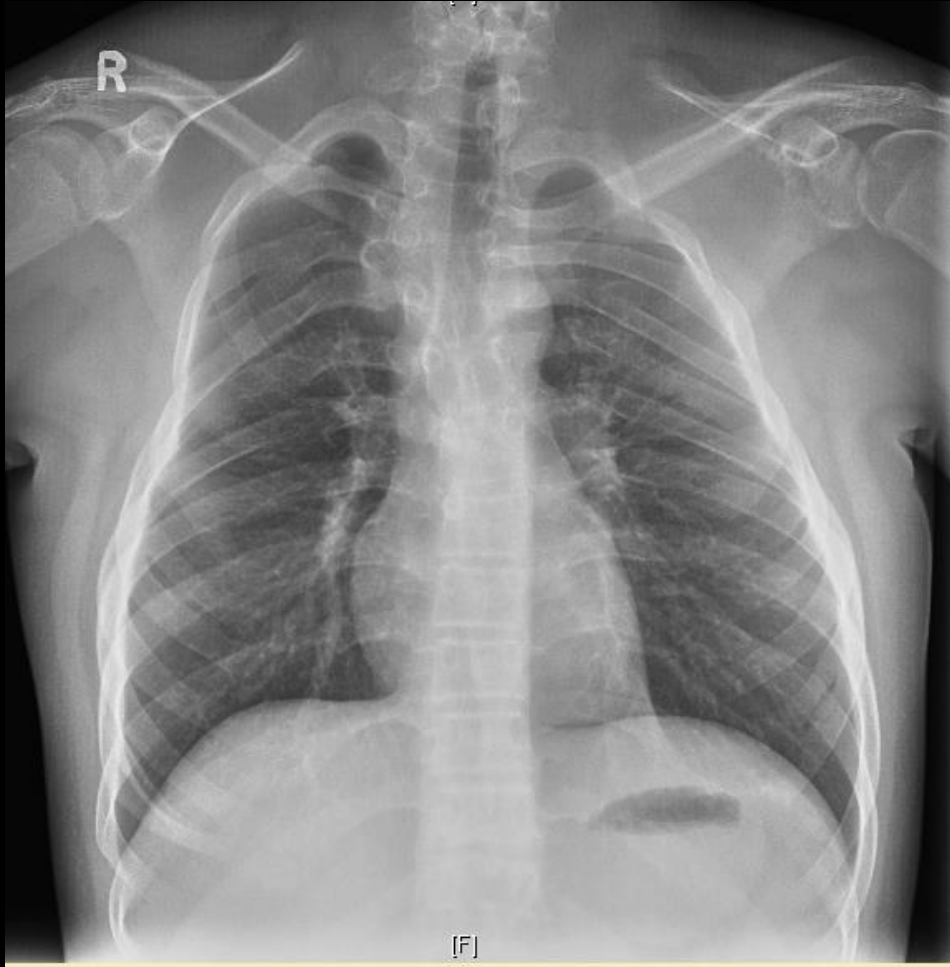
Case contributor – Dr. Praveen Kumar Chinniah

MI-COD

MSS INDIA- Case Of the Day



Findings and diagnosis?



*Images by courtesy of Dr Aparna Irodi,
CMC Vellore*