


MICOD – 23/07/2024

Case contributor – Dr. Nirmala Jambhekar

# MI-COD

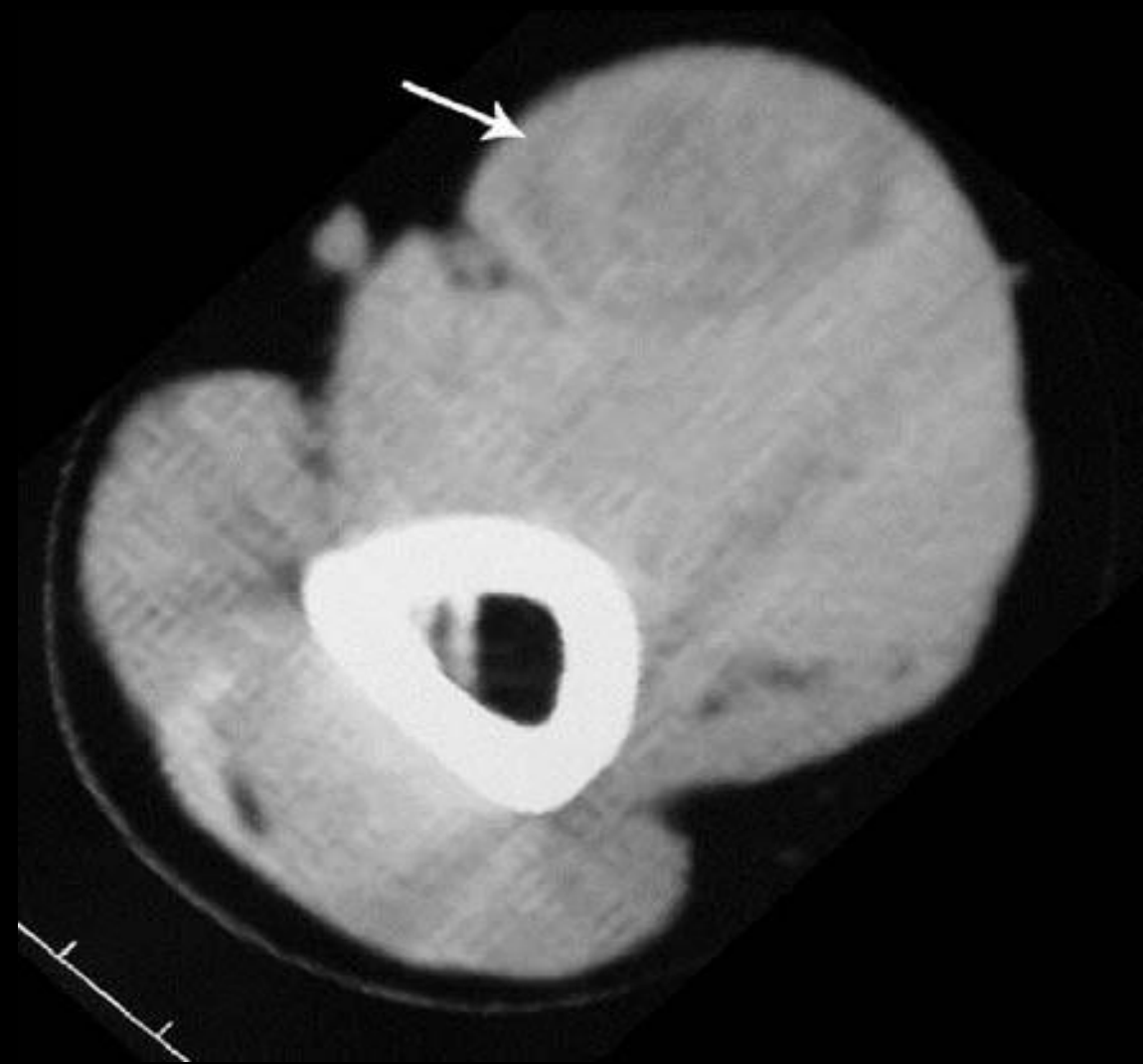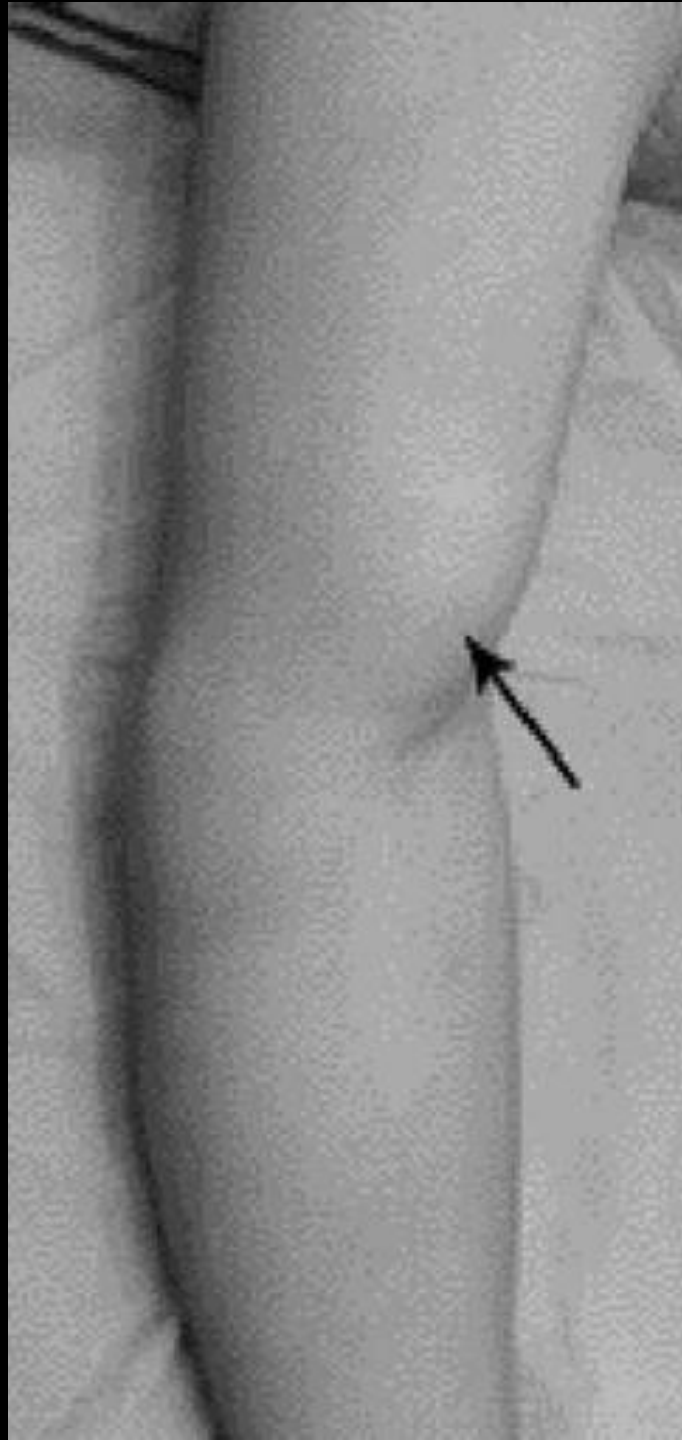
MSS INDIA- Case Of the Day



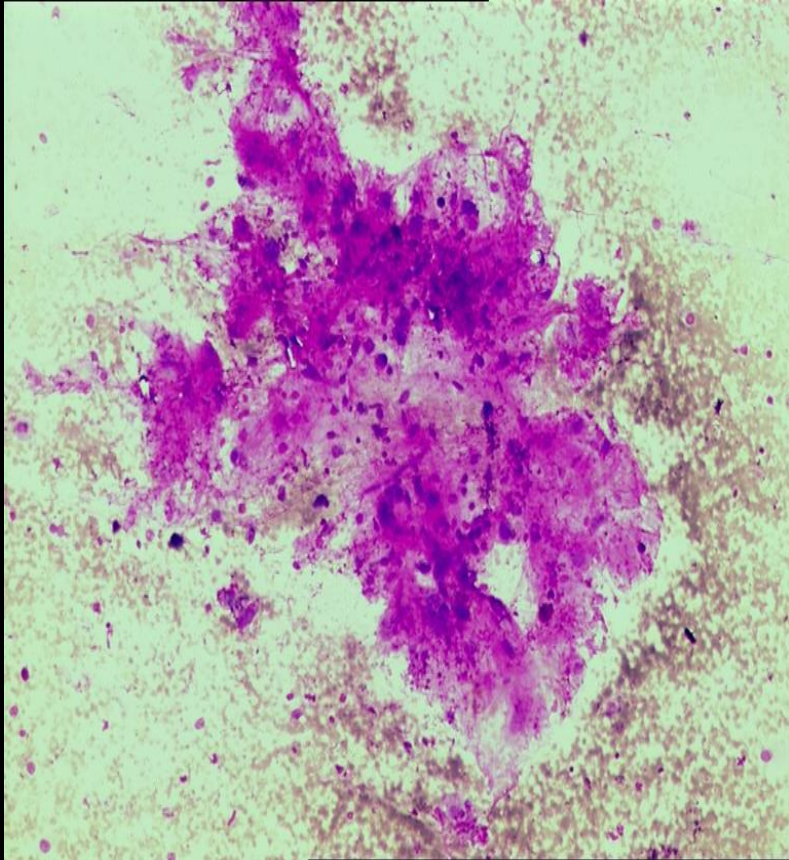
*27-year-old gentleman with swelling over the left arm which first appeared 4 years earlier while lifting a heavy weight*

*Swelling was small and had remained static in size for the initial 2 years*

*Swelling was increasing during past 2 years and had become painful*



*FNAC reported elsewhere as  
soft-tissue sarcoma with  
Myxoid stroma*



*FNAC reviewed at TMH  
s/o possibly a sarcoma*

