

MICOD – 22/07/2024

Case contributor – Dr. Harmeet Kaur

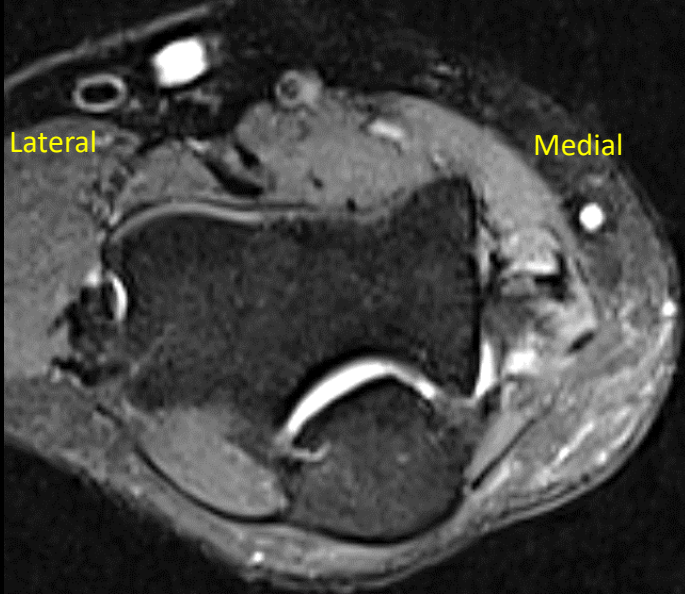
MI-COD

MSS INDIA- Case Of the Day

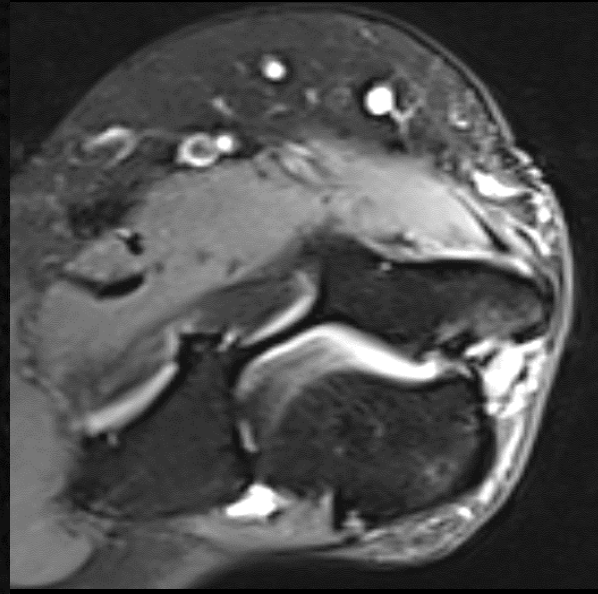


38-year-old lady with pain over the medial aspect of the right elbow joint.
No h/o trauma/Surgery in the past.

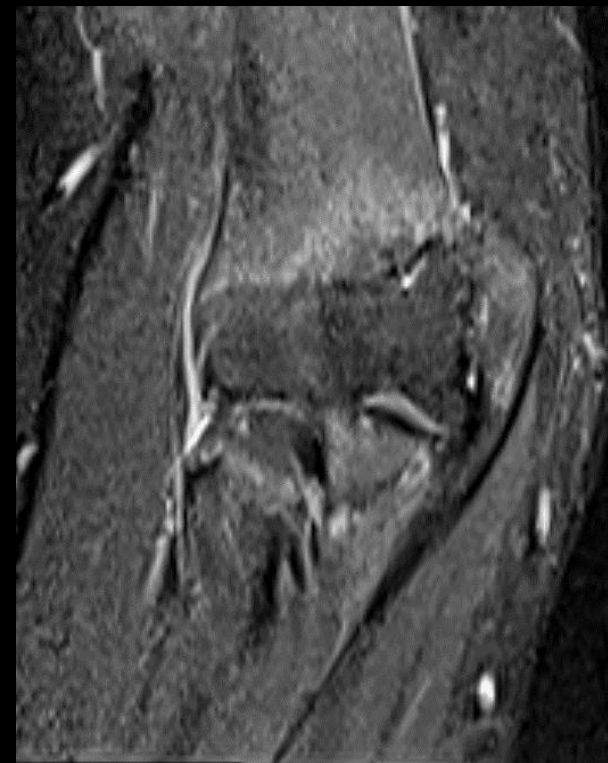Plain MRI



STIR (Axial)



PDFS (Axial)



STIR Coronal

