


MICOD – 16-07-2024

Case contributor – Dr. Gaurav Vashisht

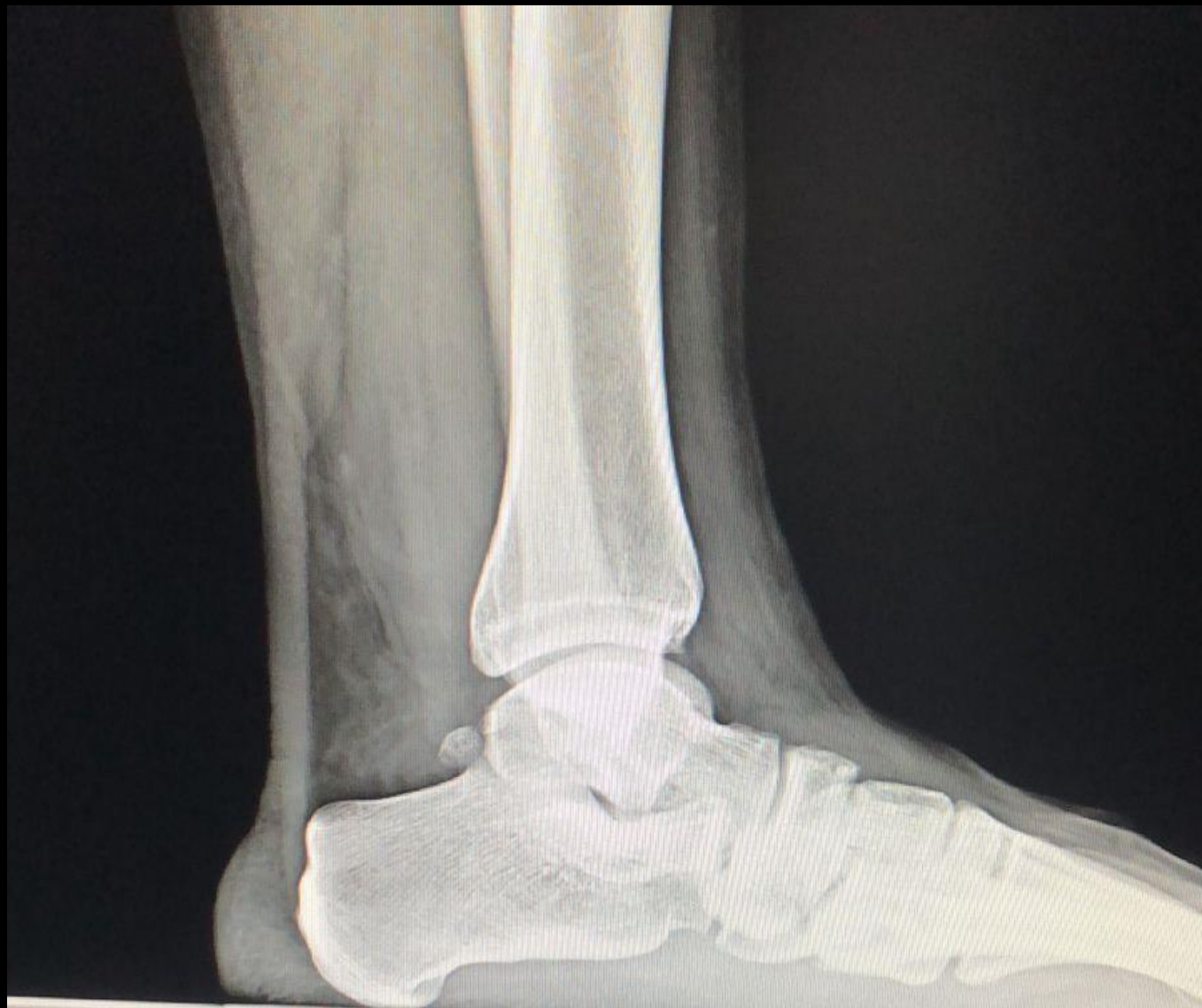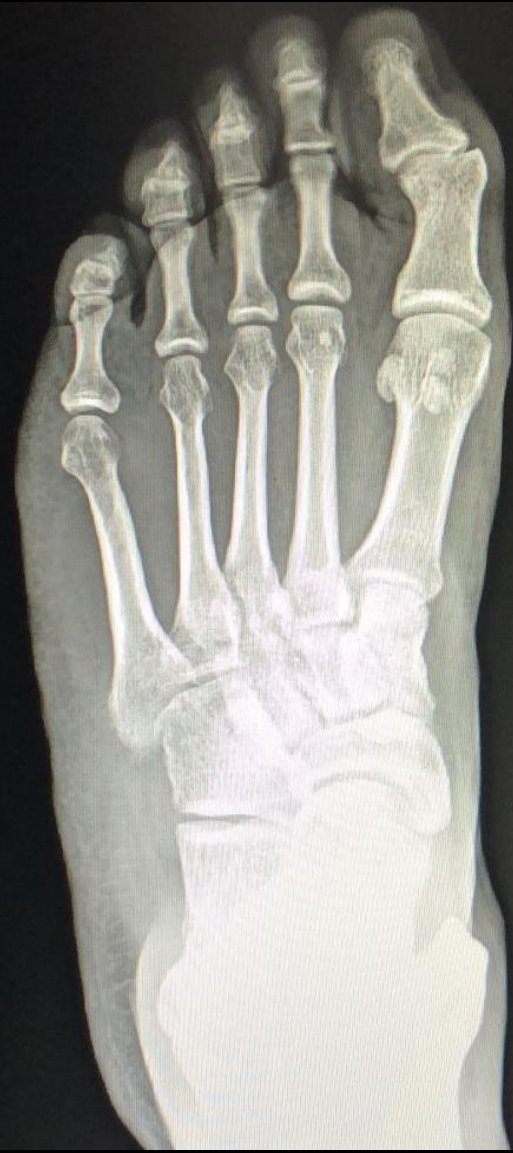MI-COD

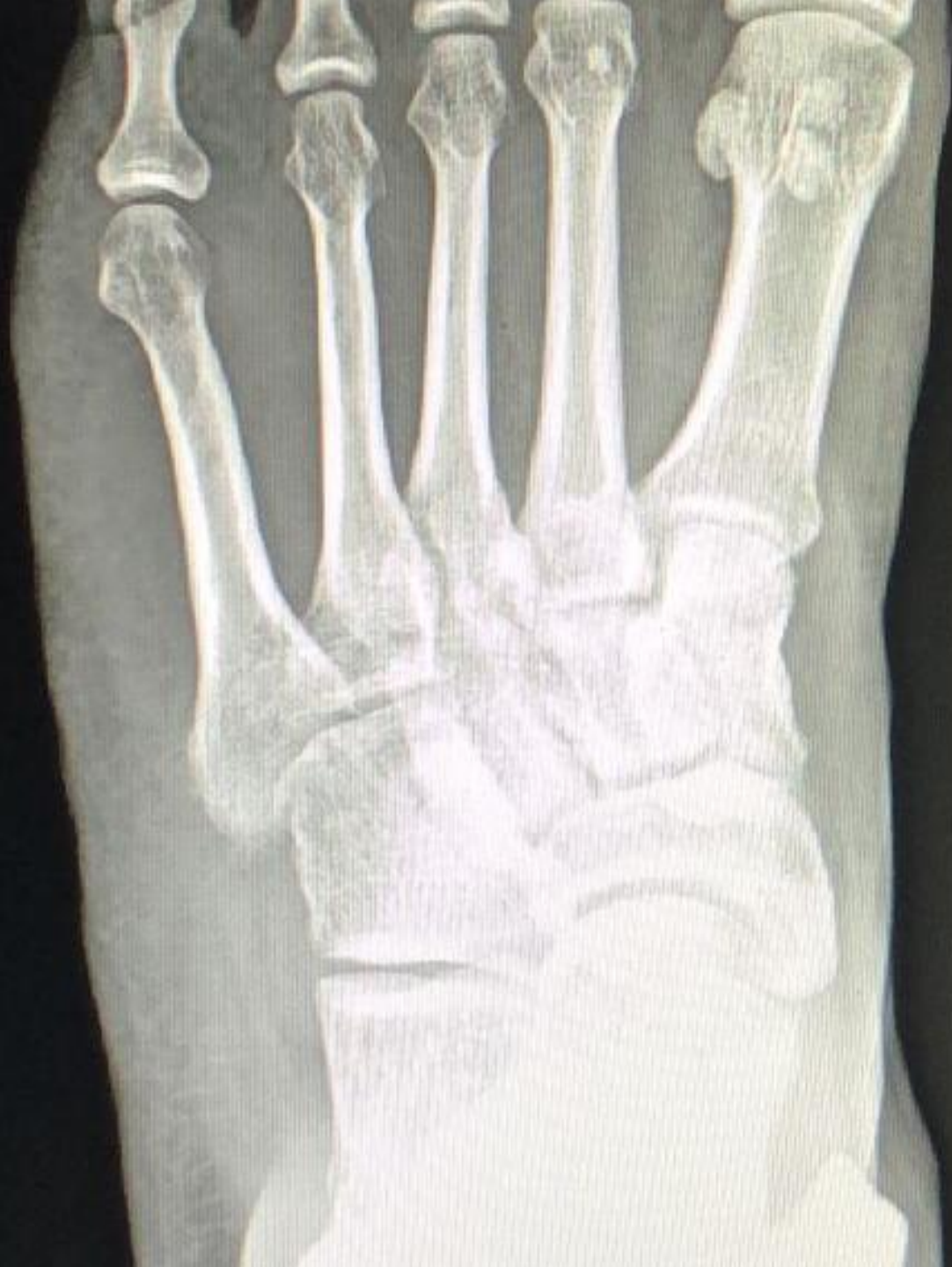MSS INDIA- Case Of the Day

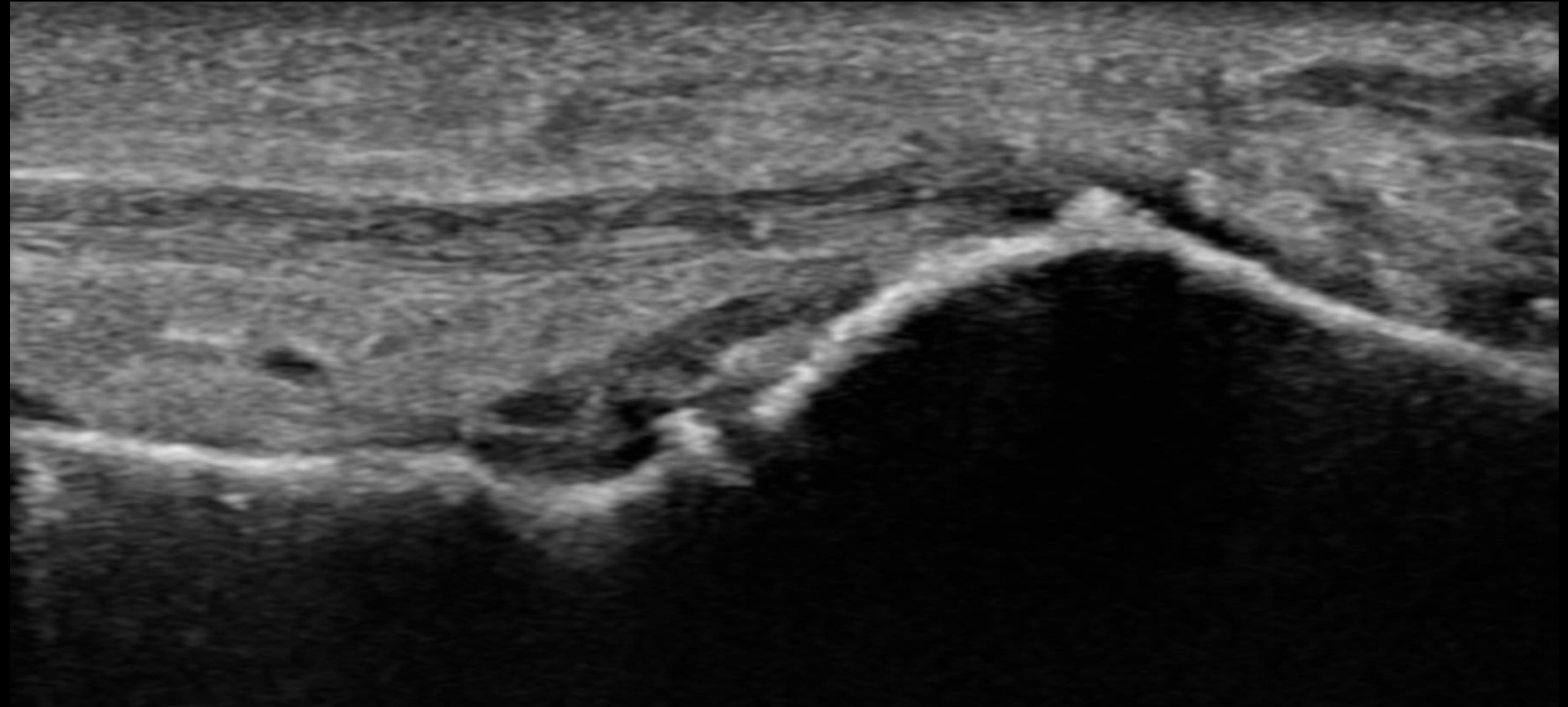


34 Y MAN WITH LATERAL FOOT
PAIN FOR 8 MONTHS
AFFECTING DAILY ACTIVITIES-
MILD RESPONSE TO NSAID'S
AND PHYSIO

XRAY







HS50

