

MICOD –12/07/2024

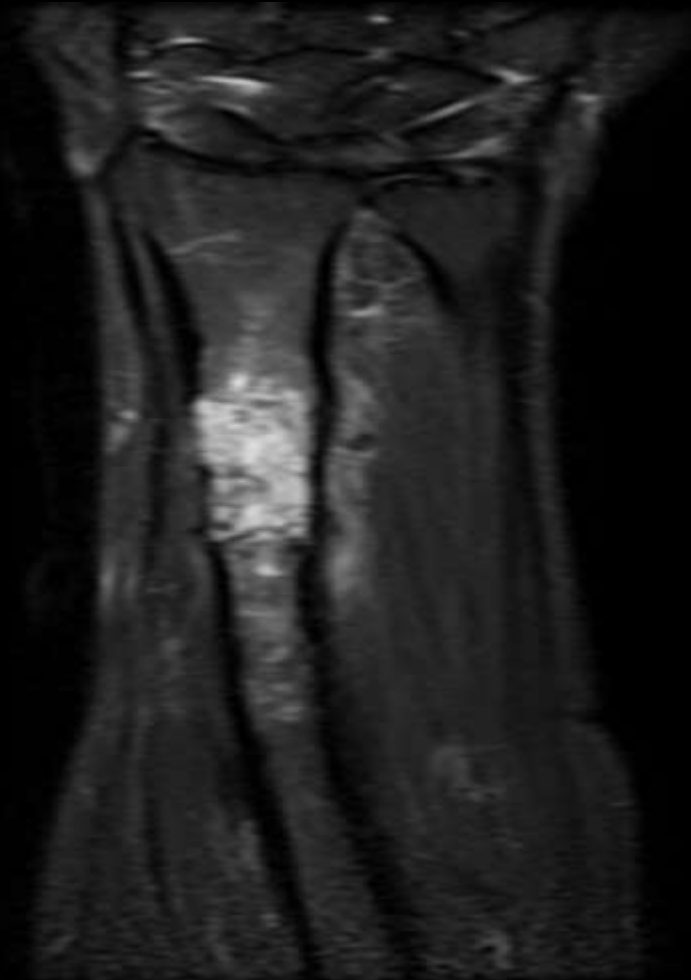
Case contributor – Dr. Suvinay Saxena

MI-COD

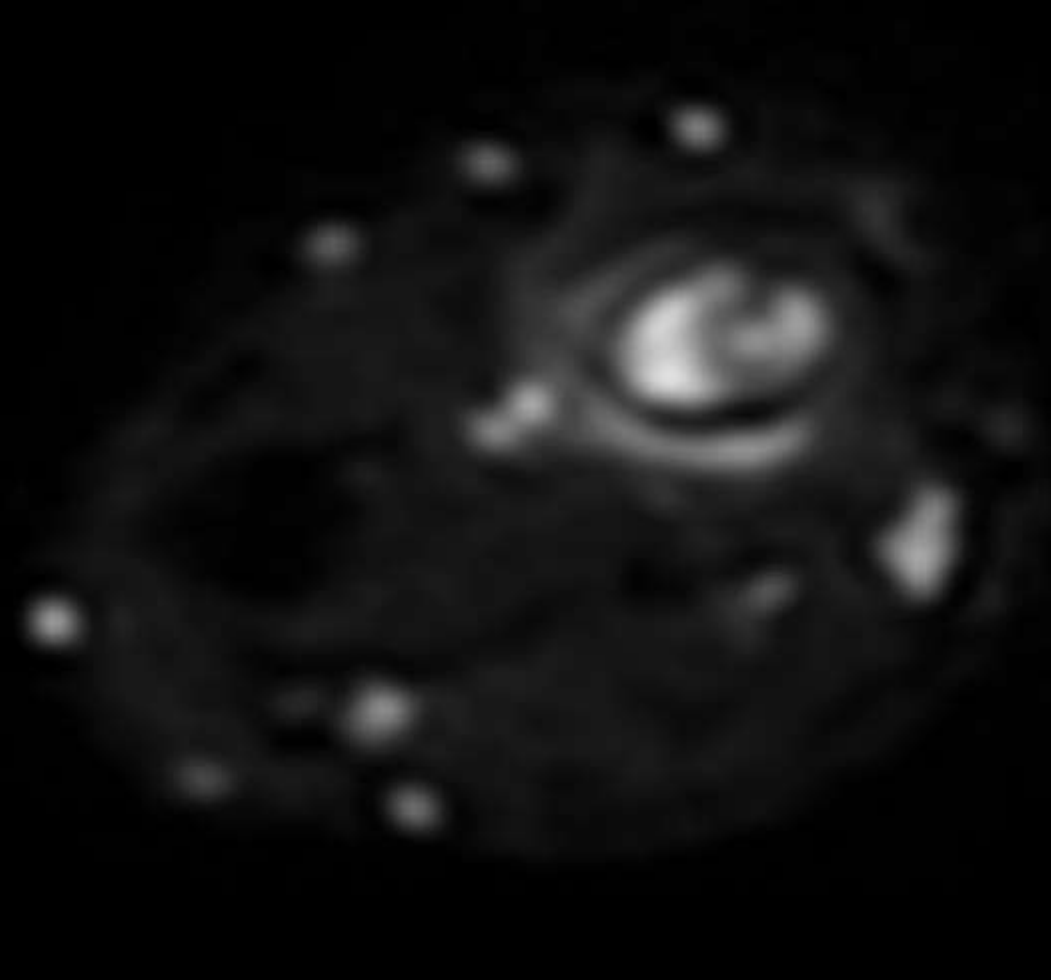
MSS INDIA- Case Of the Day



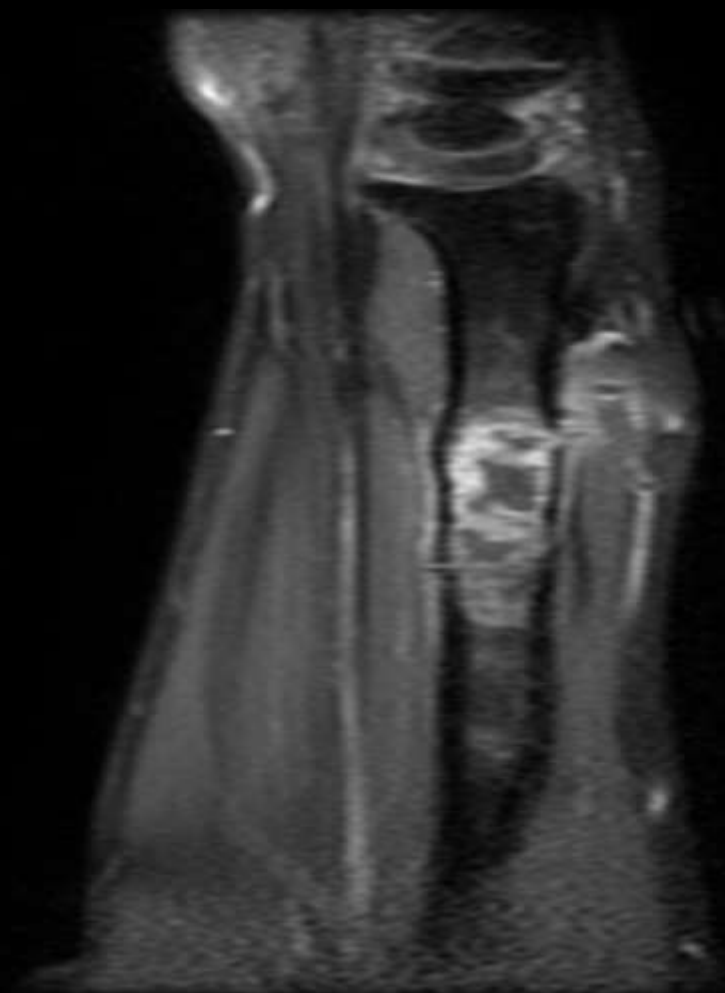
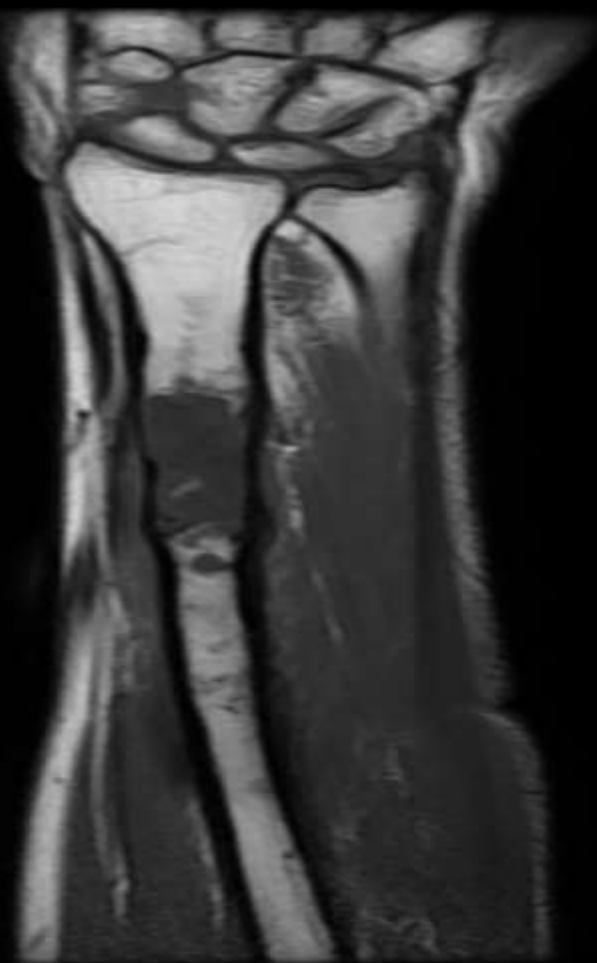A 41 year male patient presented with swelling and pain in his left forearm region, No hx of fever. Had trivial trauma and radiograph showed a lesion for which an open biopsy was performed which was inconclusive. Repeat MRI and CT guided biopsy was performed.



COR STIR



DWI



T1+C



Diagnosis ?