


MICOD –08/07/2024

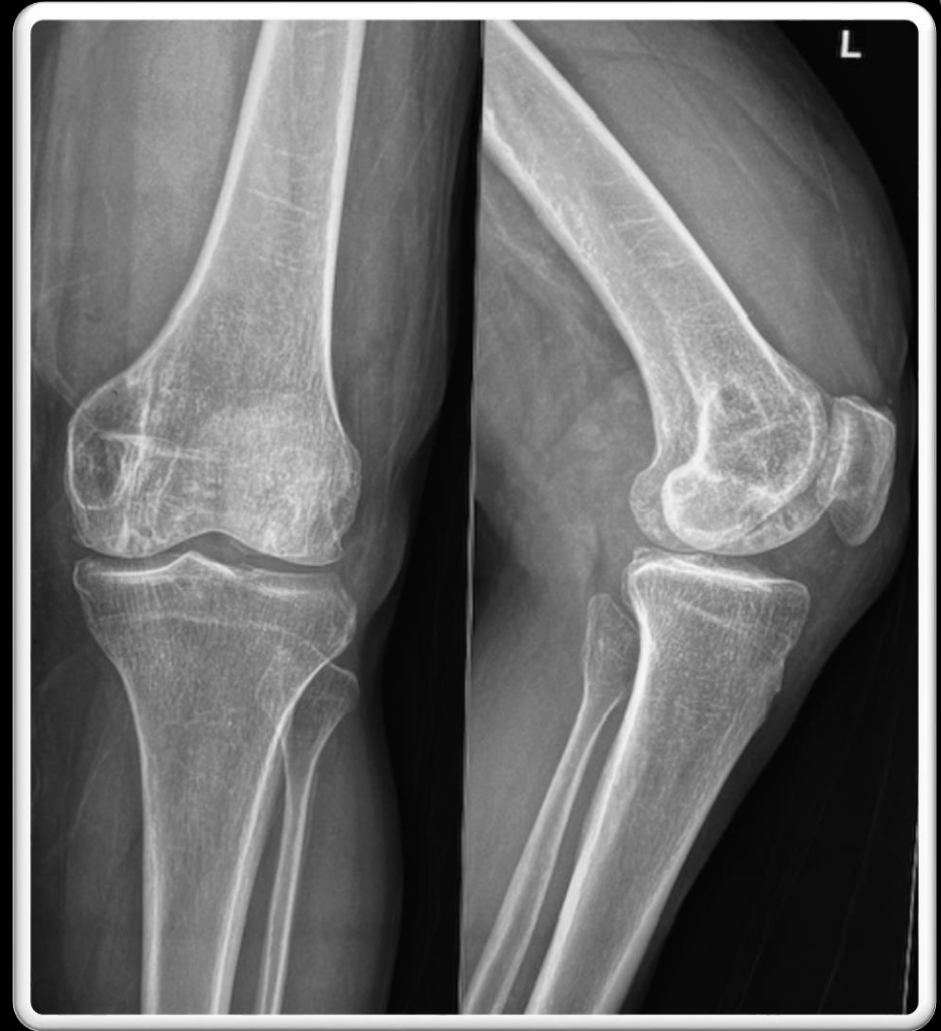Case contributor – Dr Vaishali Upadhyaya

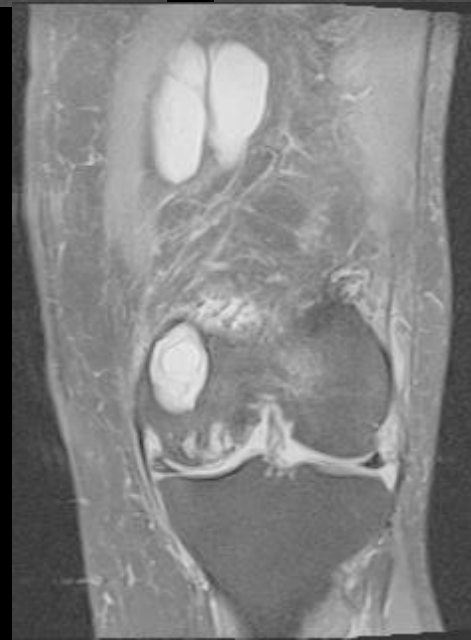
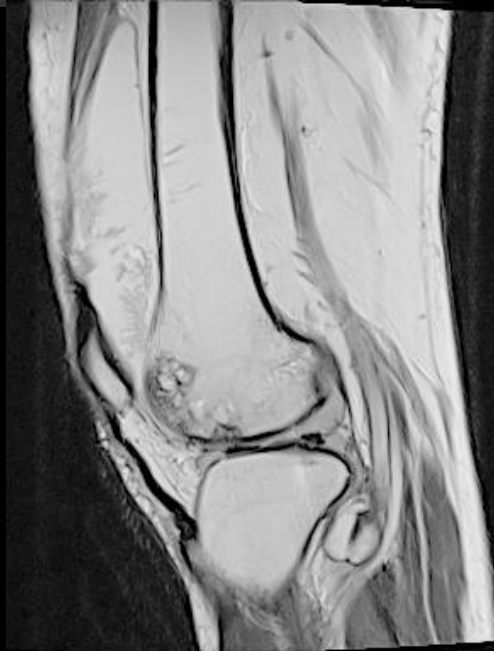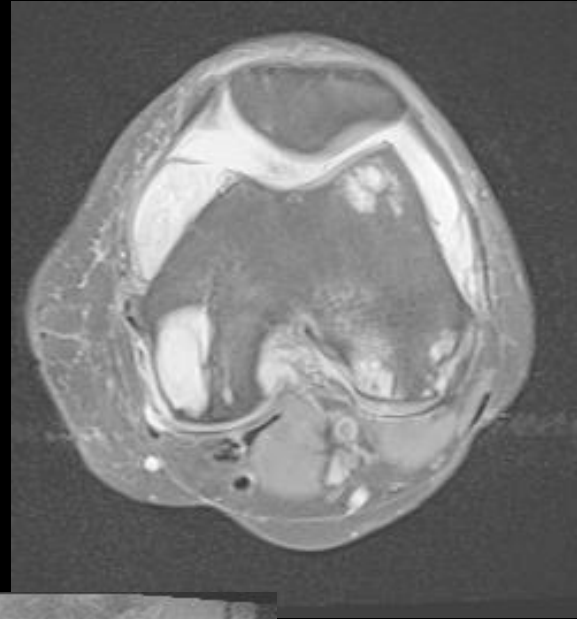
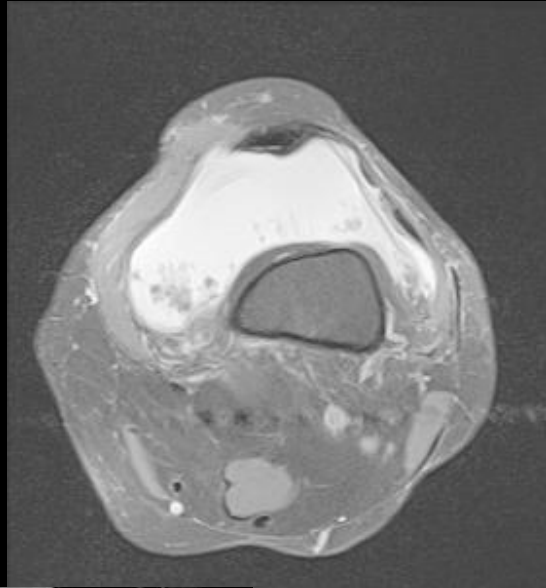
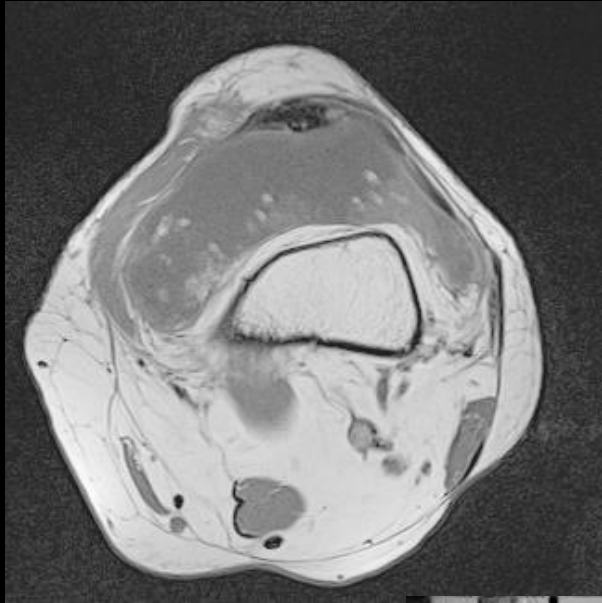
MI-COD

MSS INDIA- Case Of the Day



- 57-year-old lady with slowly and progressively increasing swelling in left suprapatellar region.
- No h/o fever
- No other joint involvement





AXIAL, CORONAL AND SAGITTAL
MR IMAGES

The background of the image consists of a dense field of vertical lines of varying heights and colors, including shades of blue, green, and yellow, set against a solid black background. The lines are scattered across the entire frame, creating a textured, digital-like effect.

Diagnosis ?