

MICOD -05/07/2024

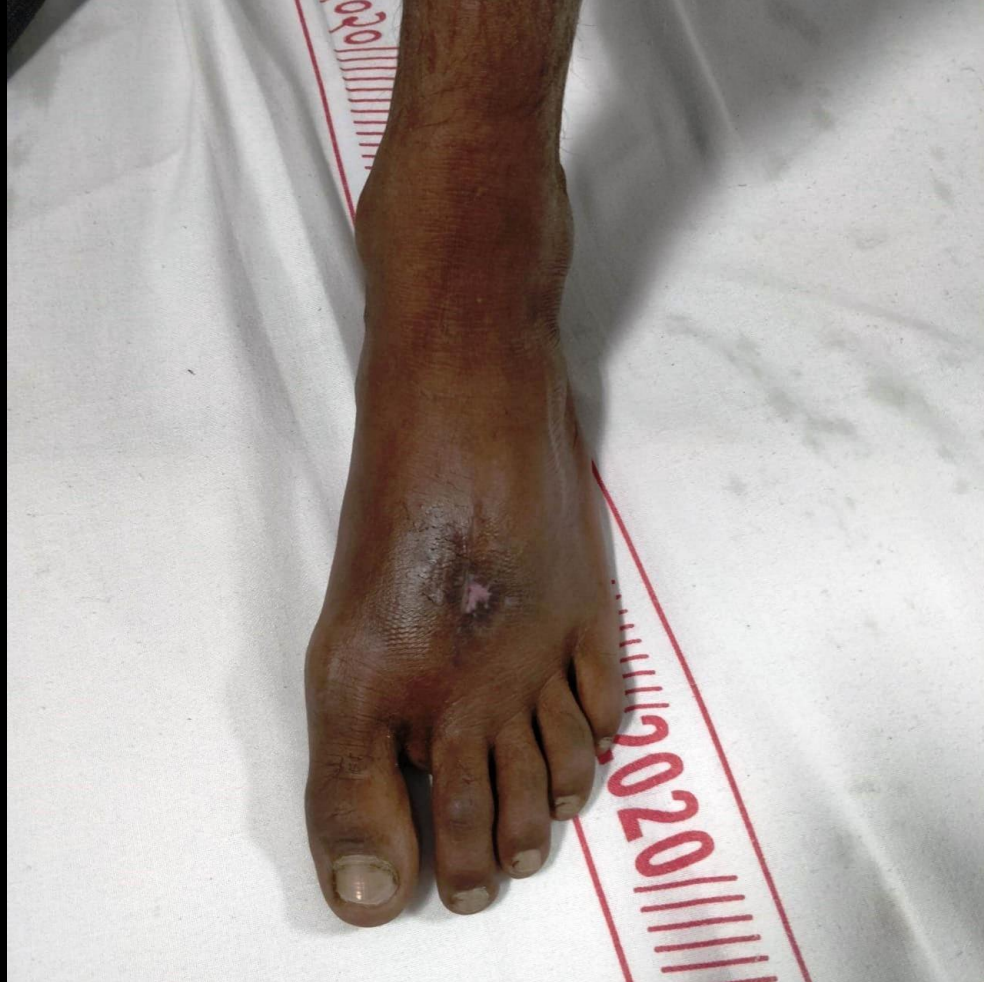Case contributor – Dr. Sonal Saran

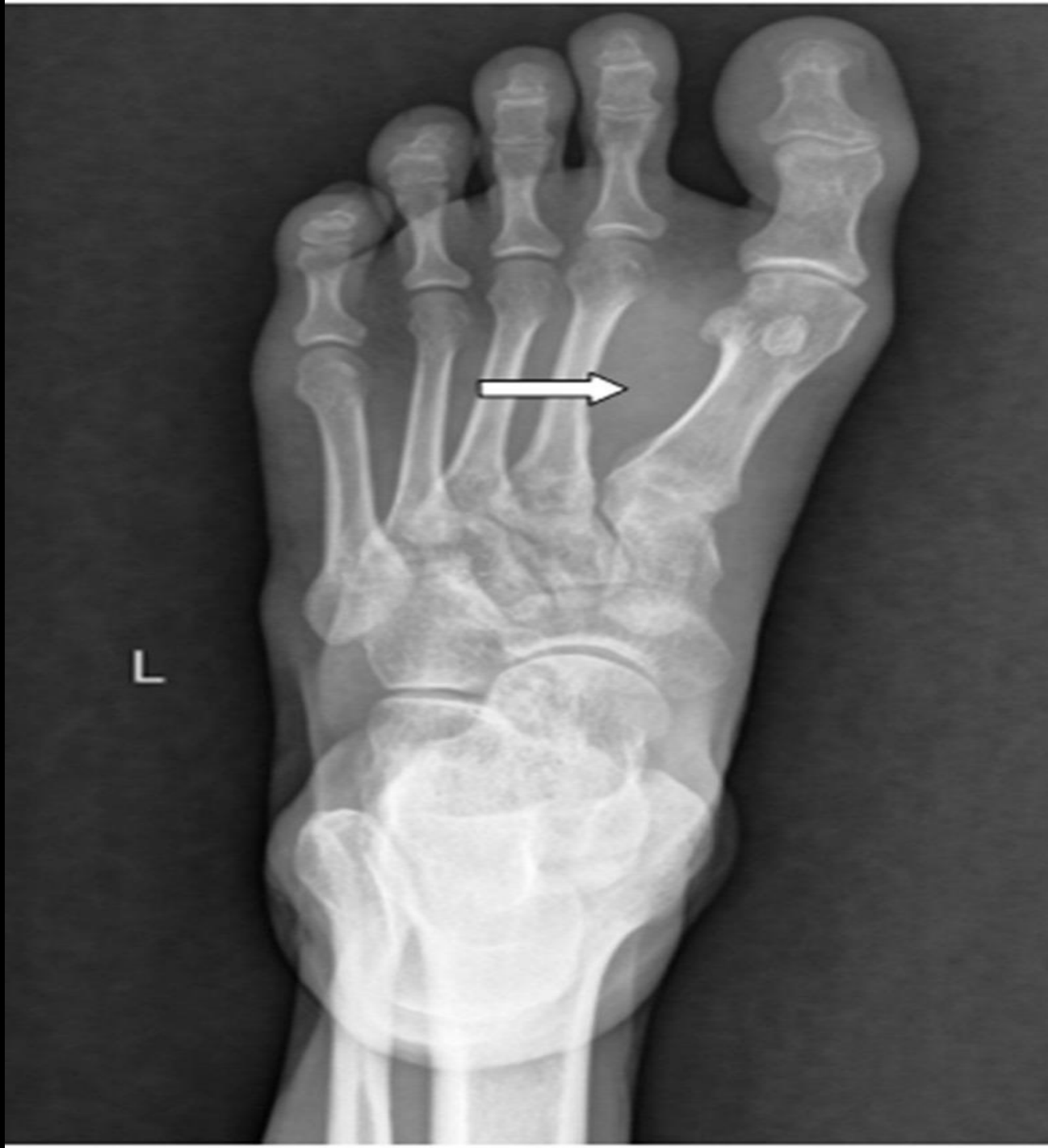MI-COD

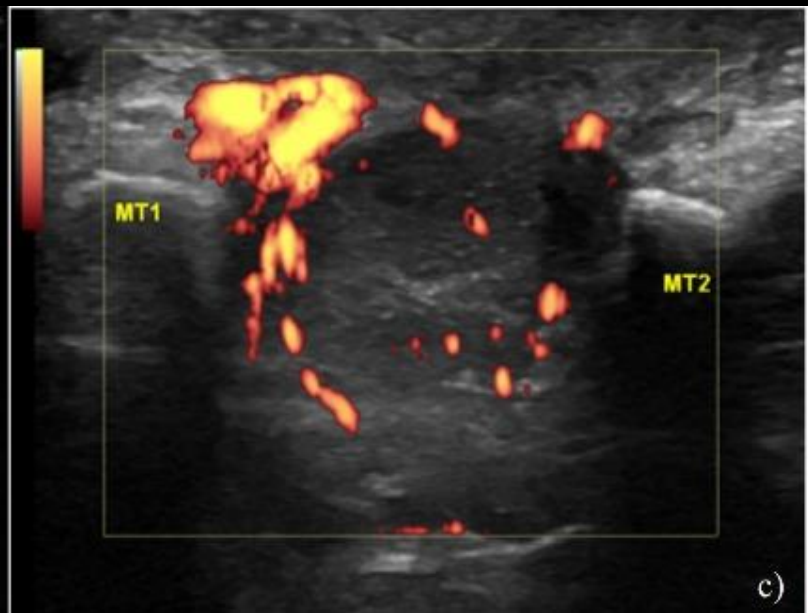
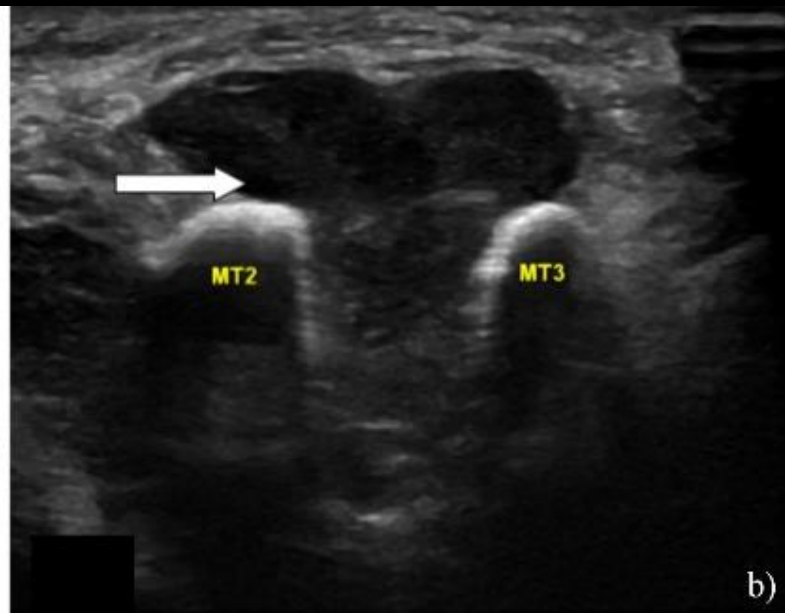
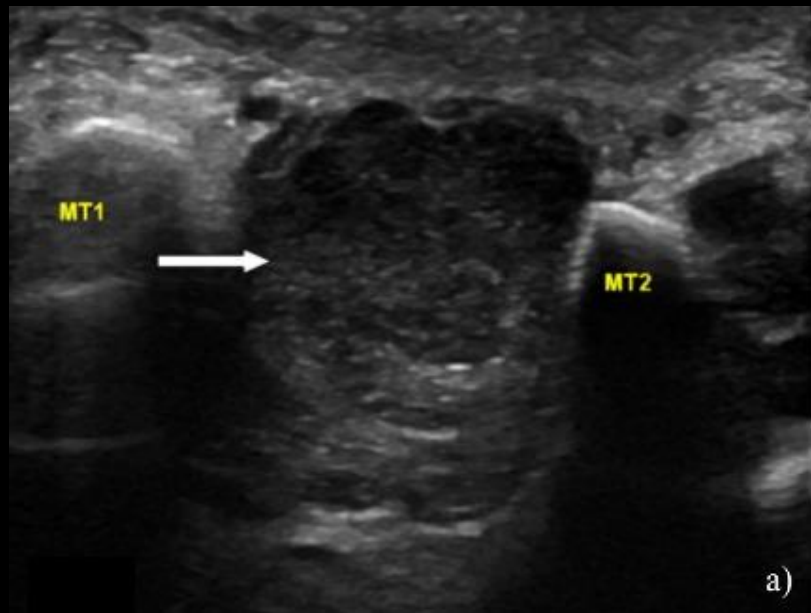
MSS INDIA- Case Of the Day

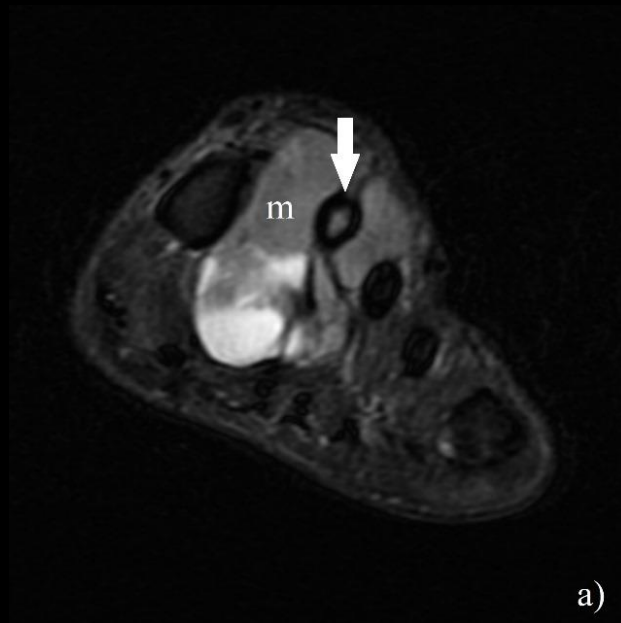


46-year-old male presented with a history of gradually progressive swelling and pain in the left foot for 2 years. The patient denied any history of trauma and any significant past medical or surgical history.

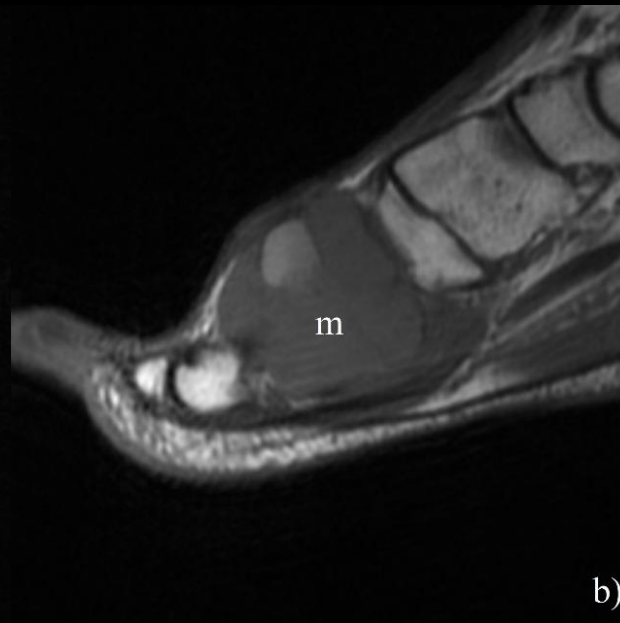




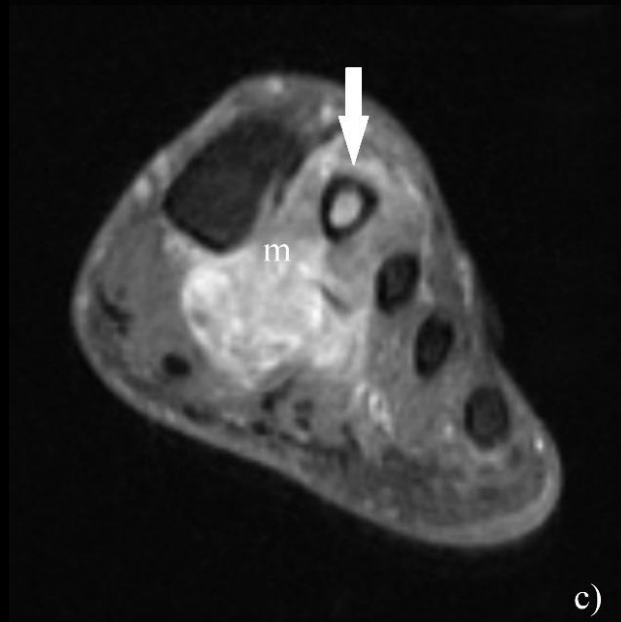




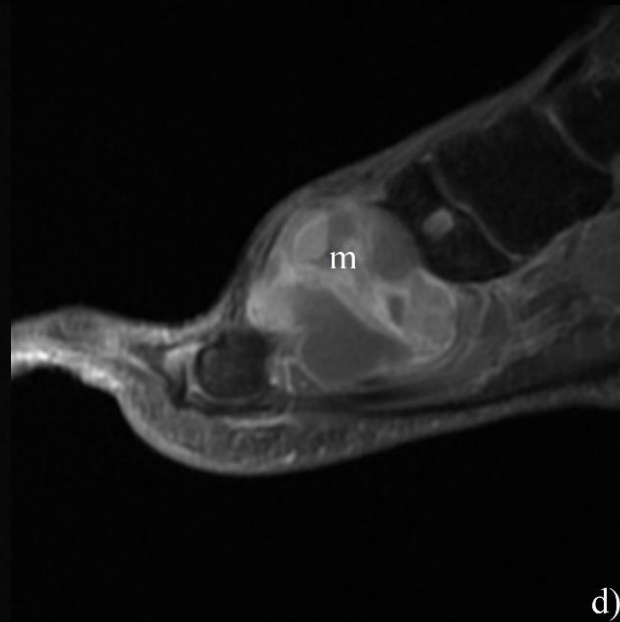
a)



b)



c)



d)

Diagnosis??

