

MICOD -04/07/2024

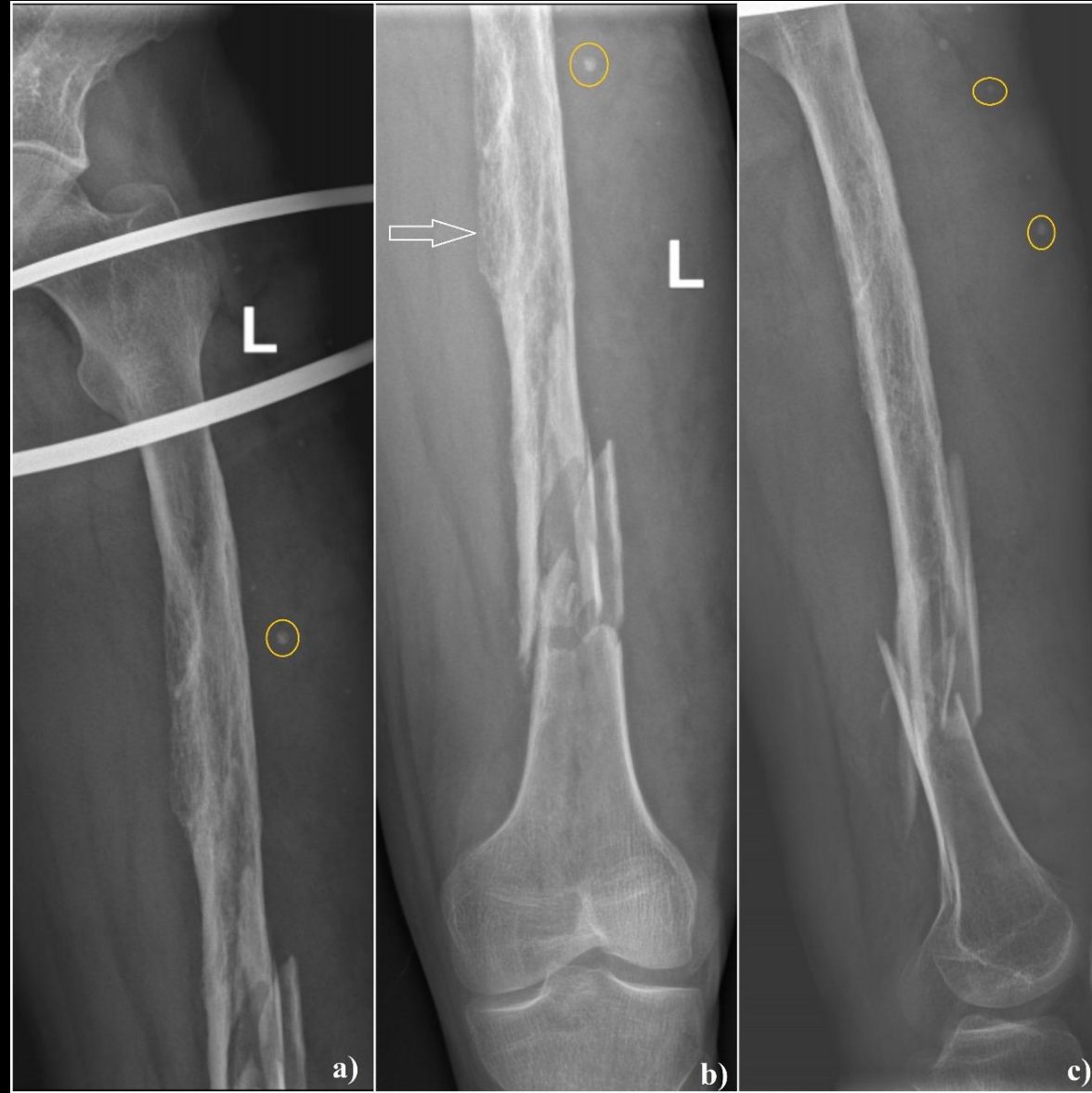
Case contributor – Dr. Sonal Saran

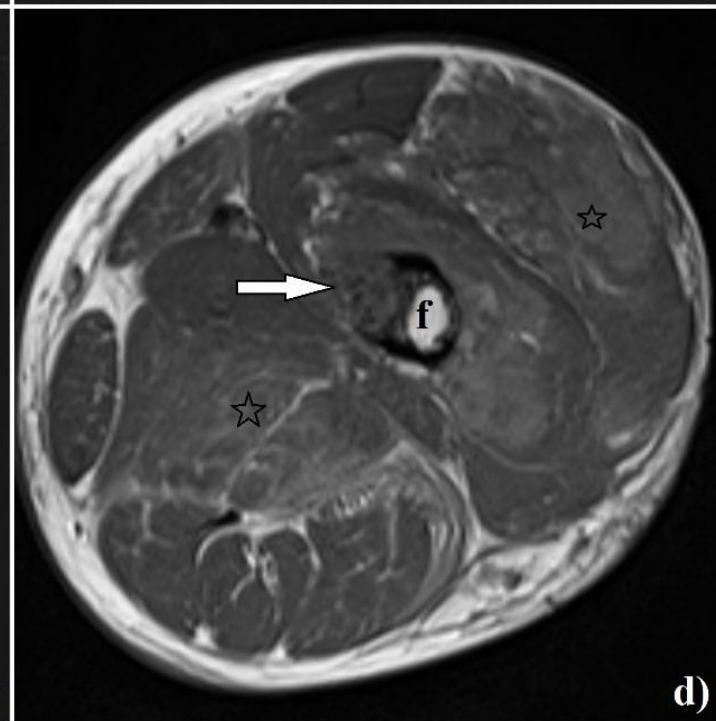
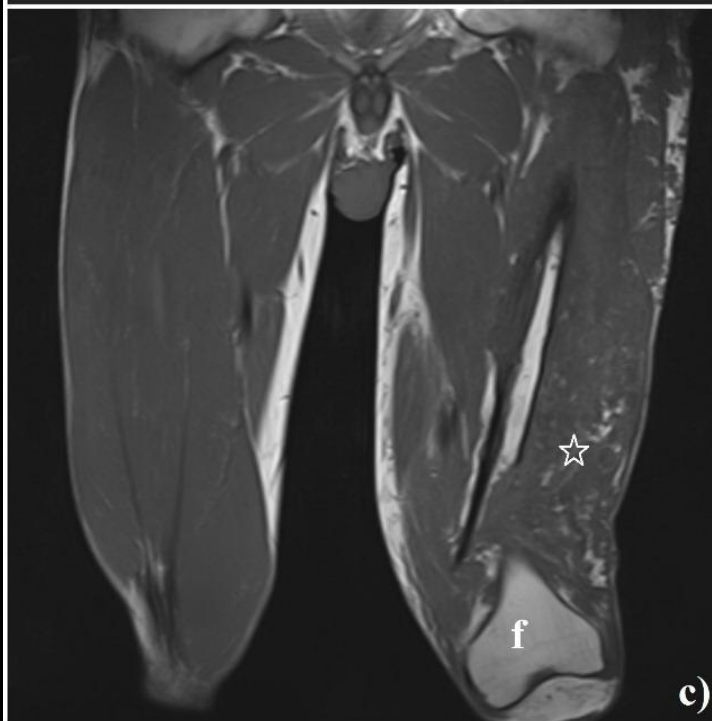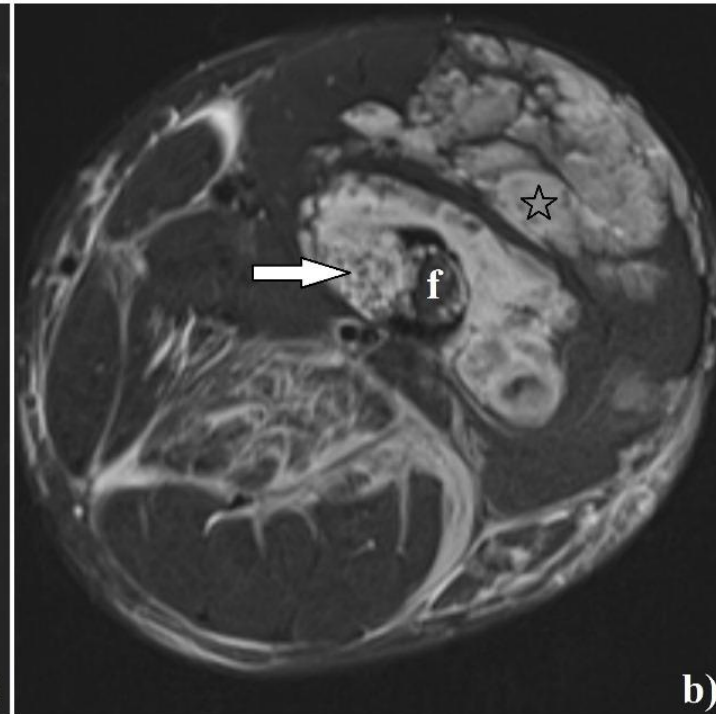
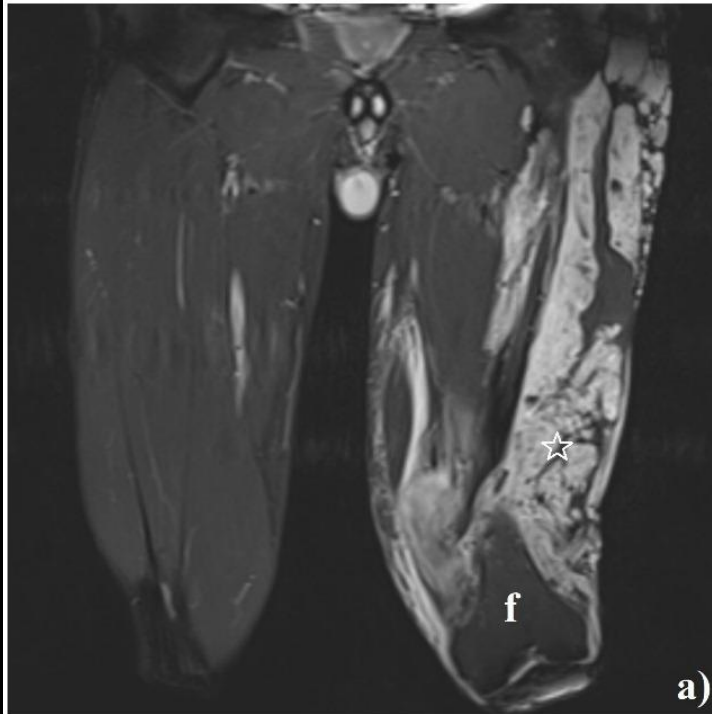
# MI-COD

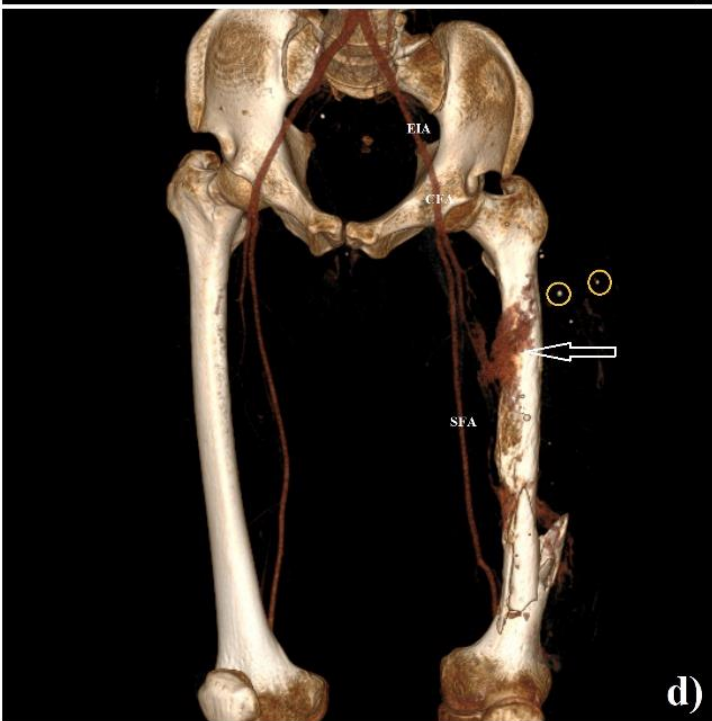
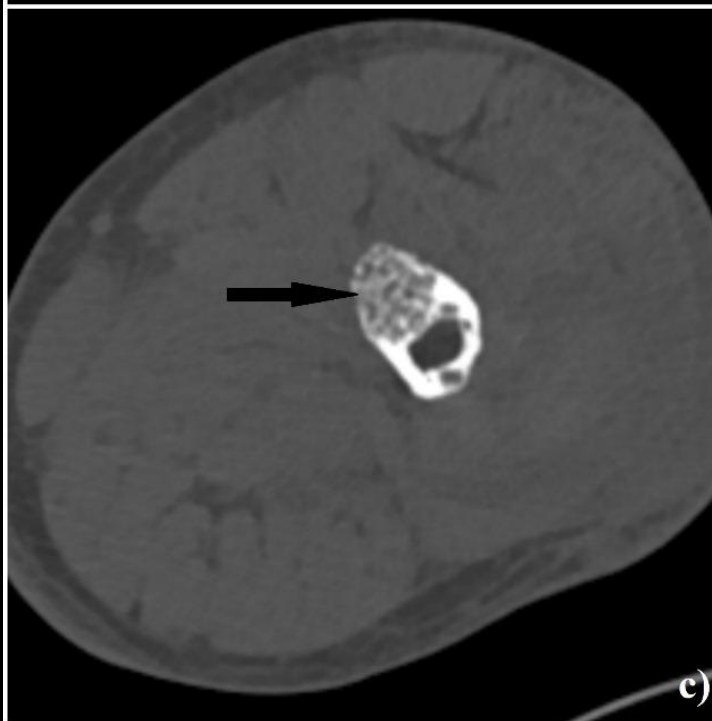
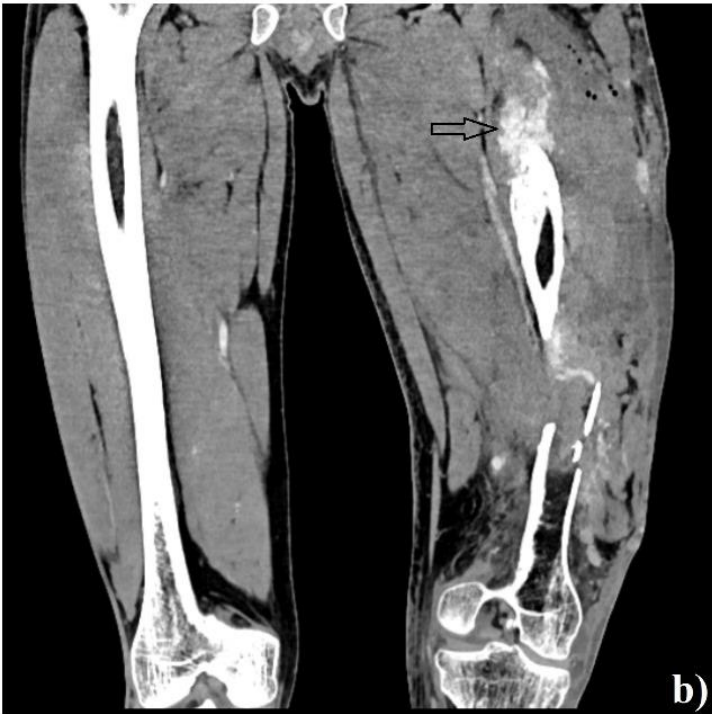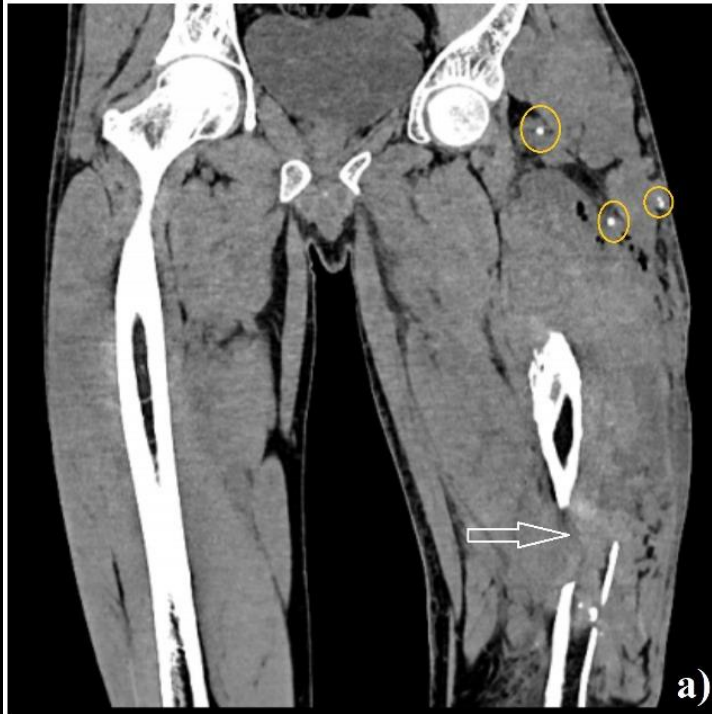MSS INDIA- Case Of the Day

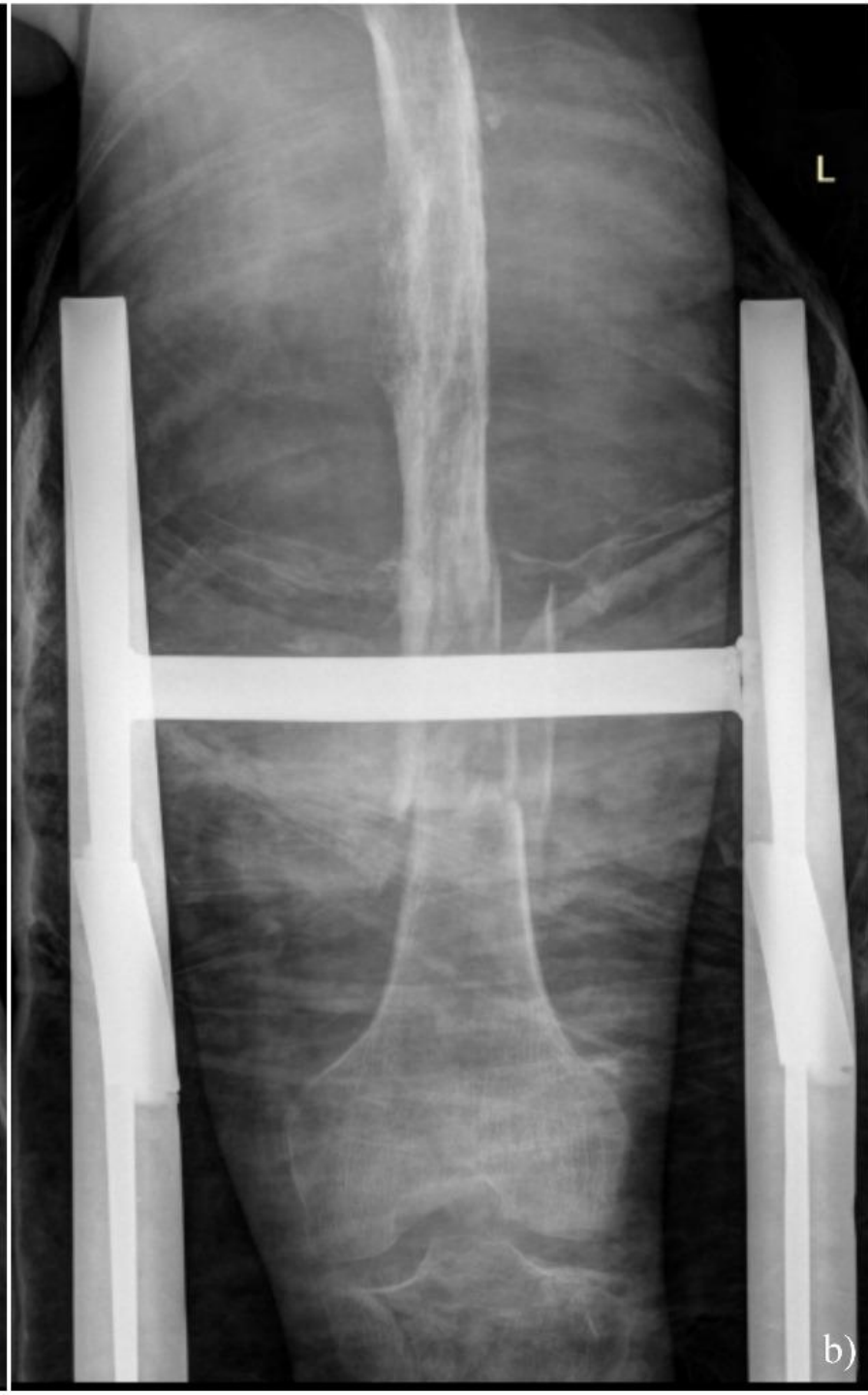
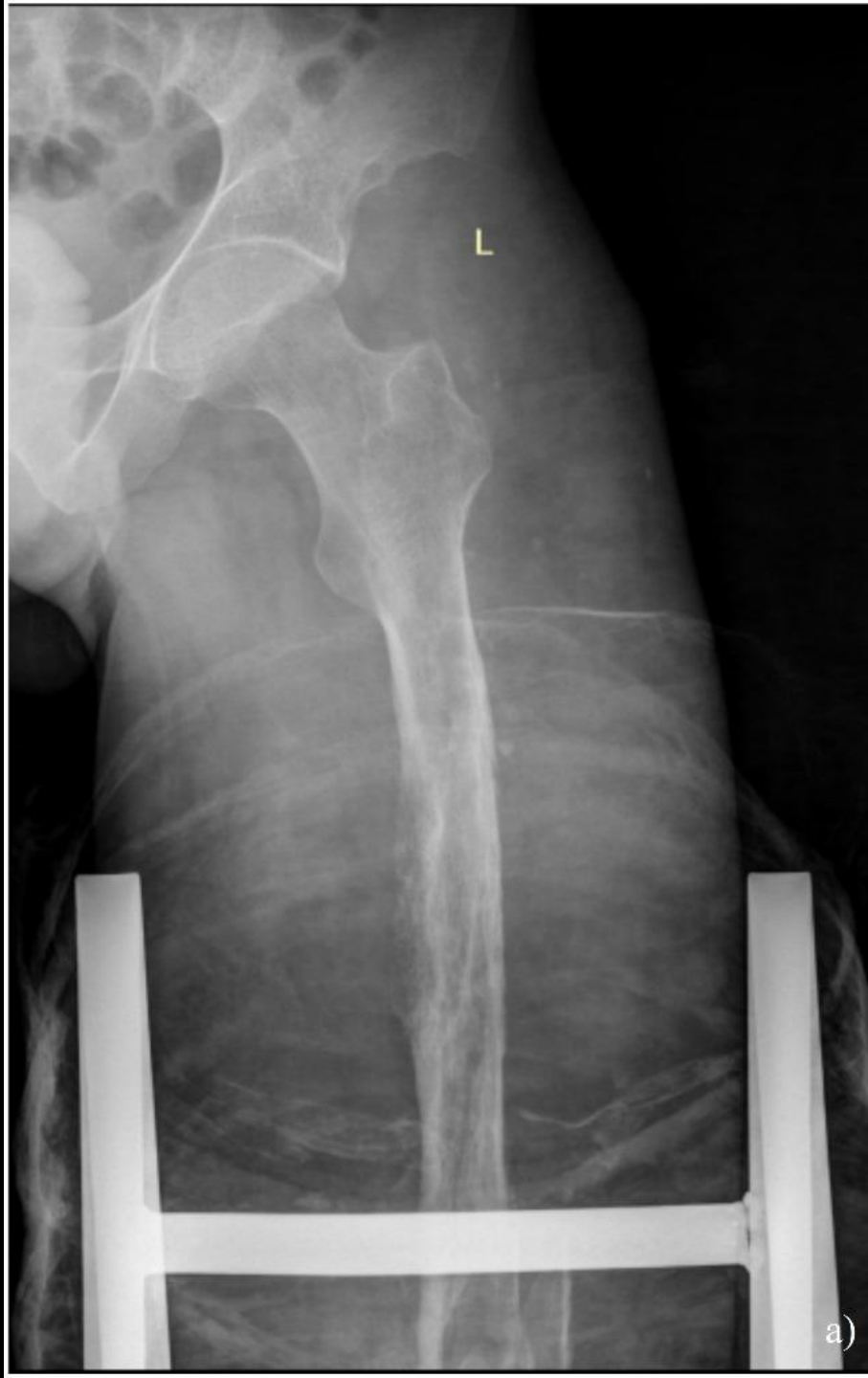
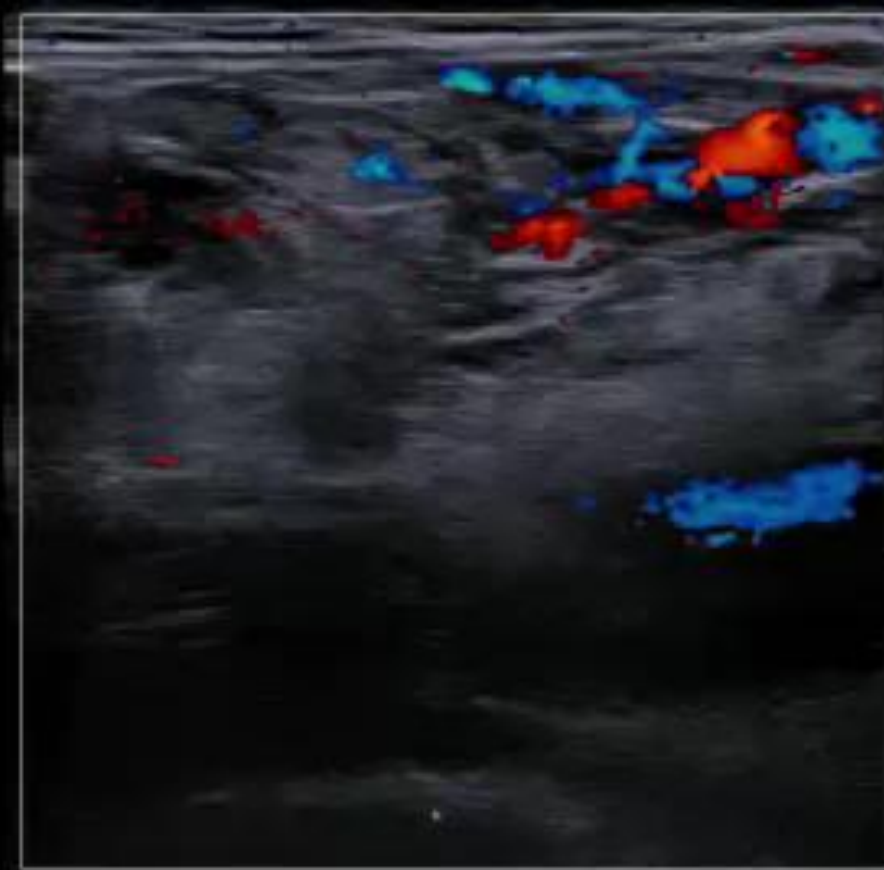
30-year-old male who presented with a pathological fracture of the left femur following trivial trauma.











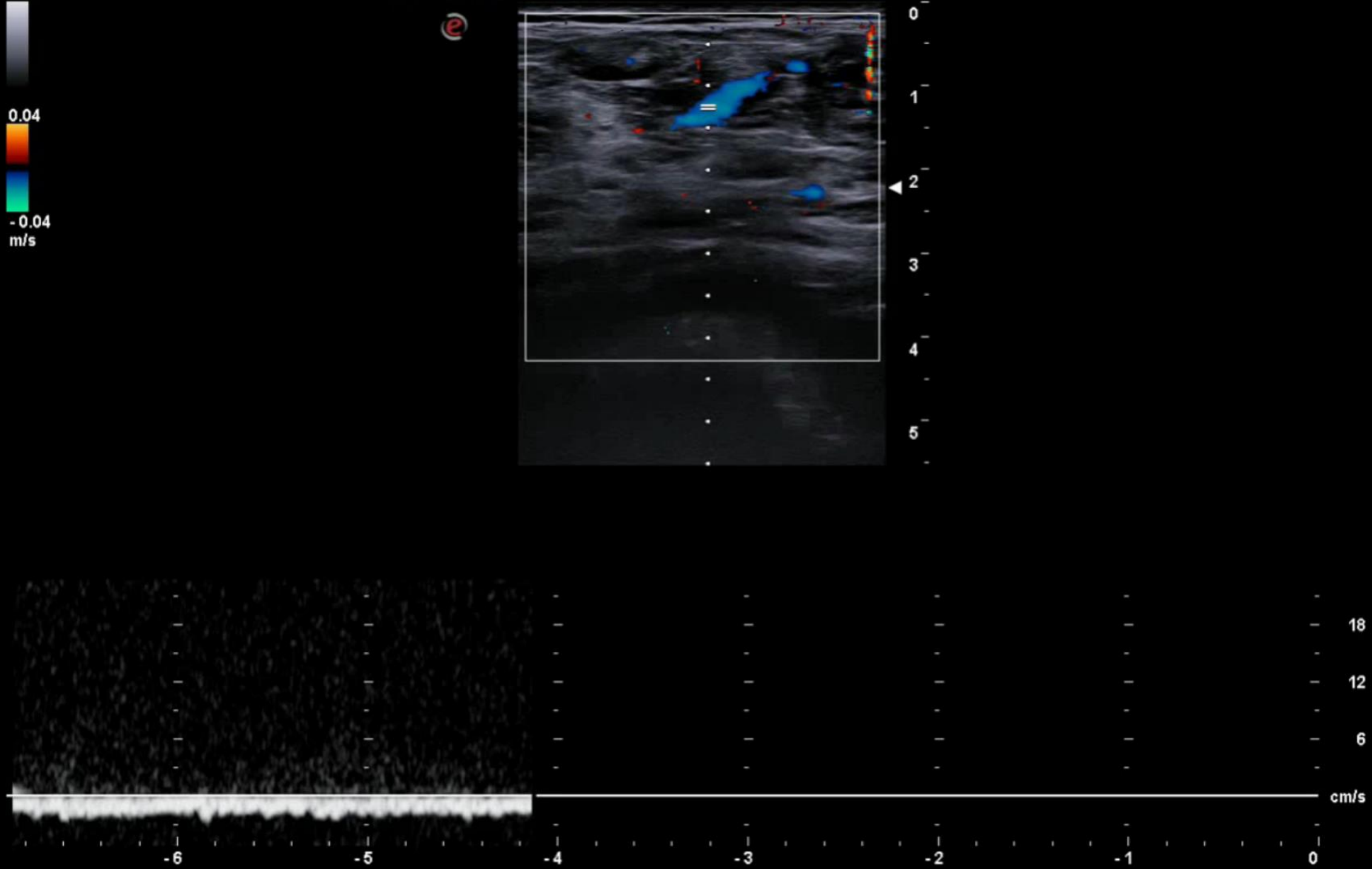
C

1

2

3

4



Diagnosis??

