

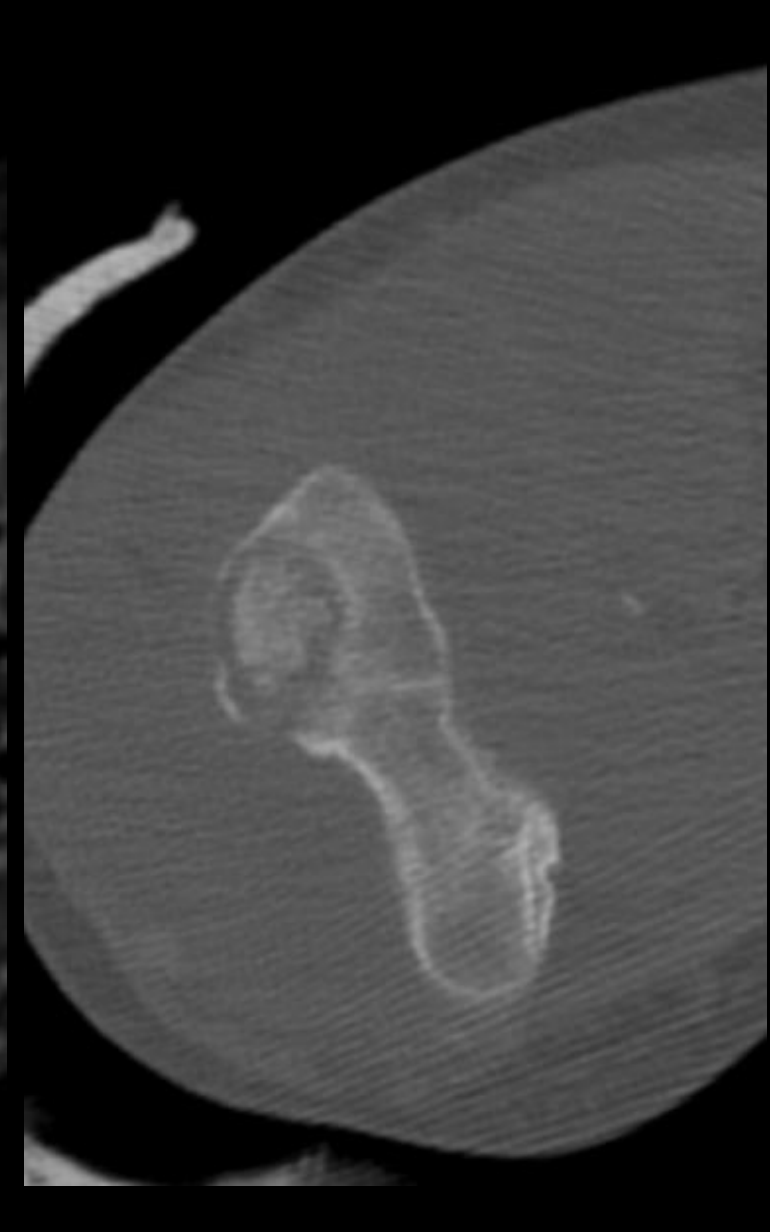
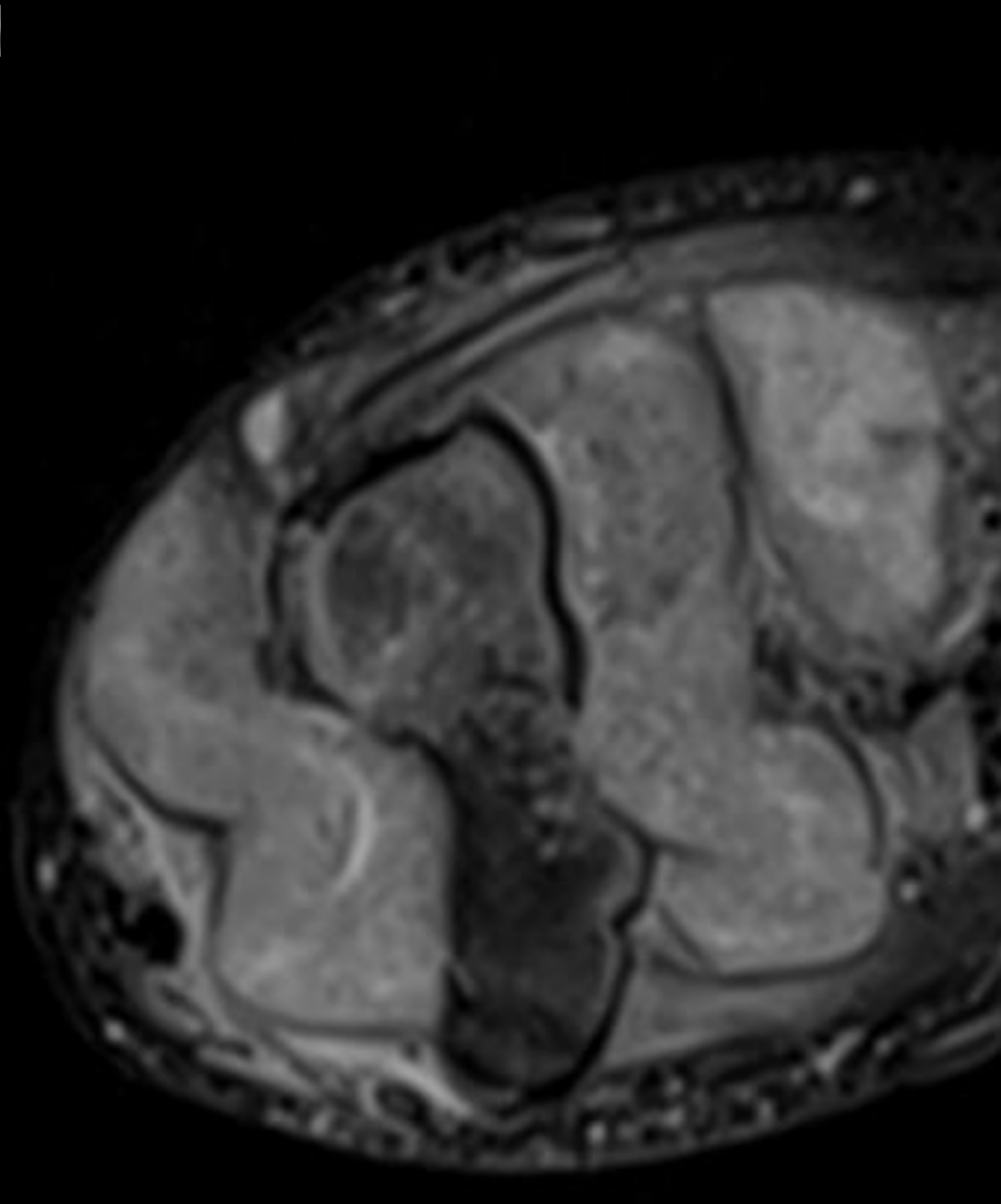
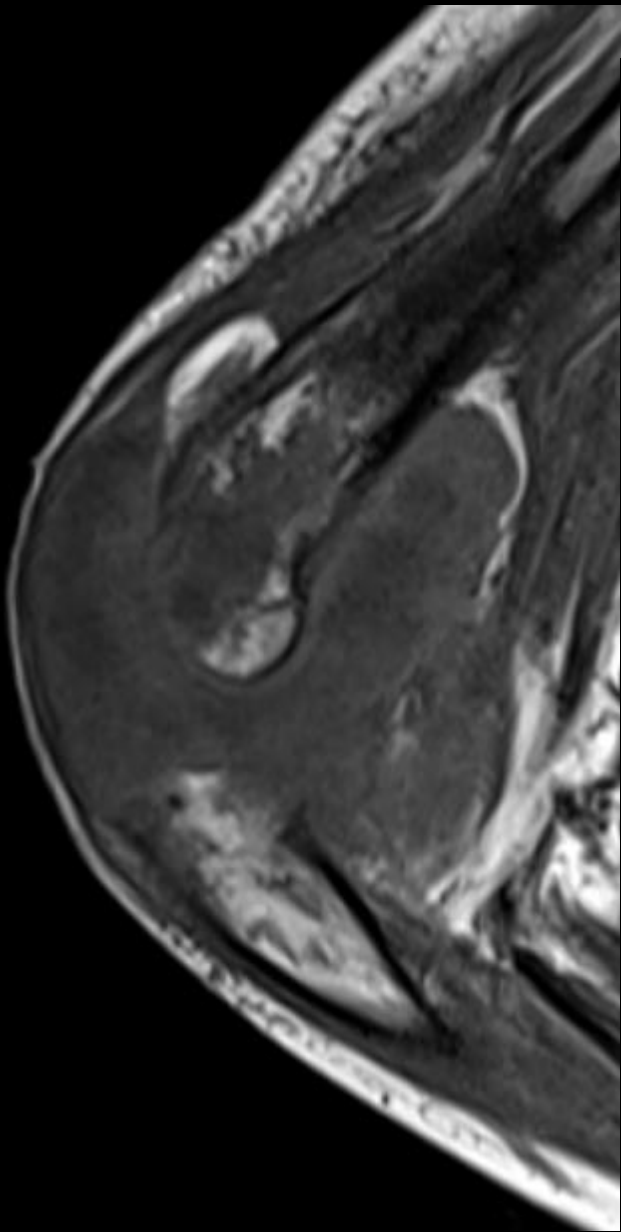
MICOD – 02/07/2024

Case contributor – Dr. Praveen Kumar Chinniah

# MI-COD

MSS INDIA- Case Of the Day





**T1 sag, STIR axial and CT axial section of left elbow of 7-year-old child**