

MICOD – 26/06/2024

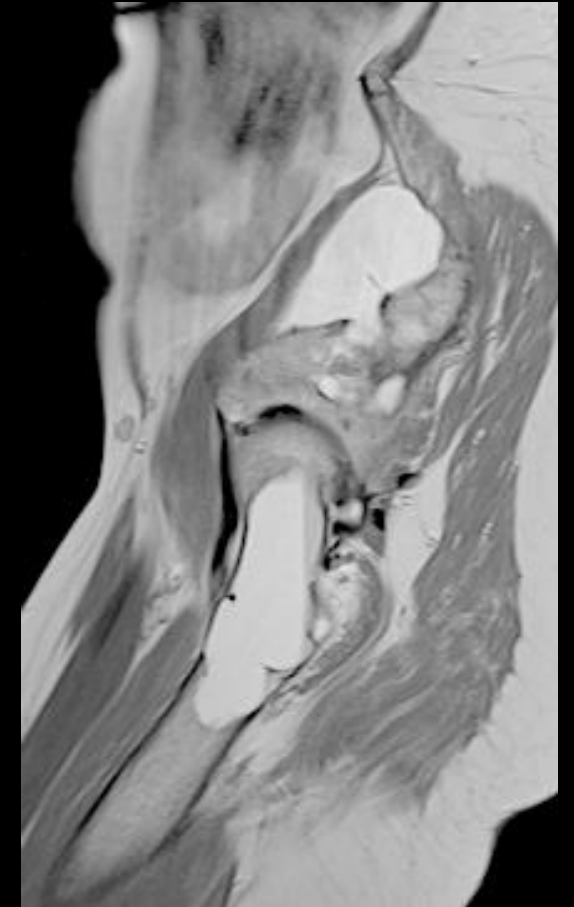
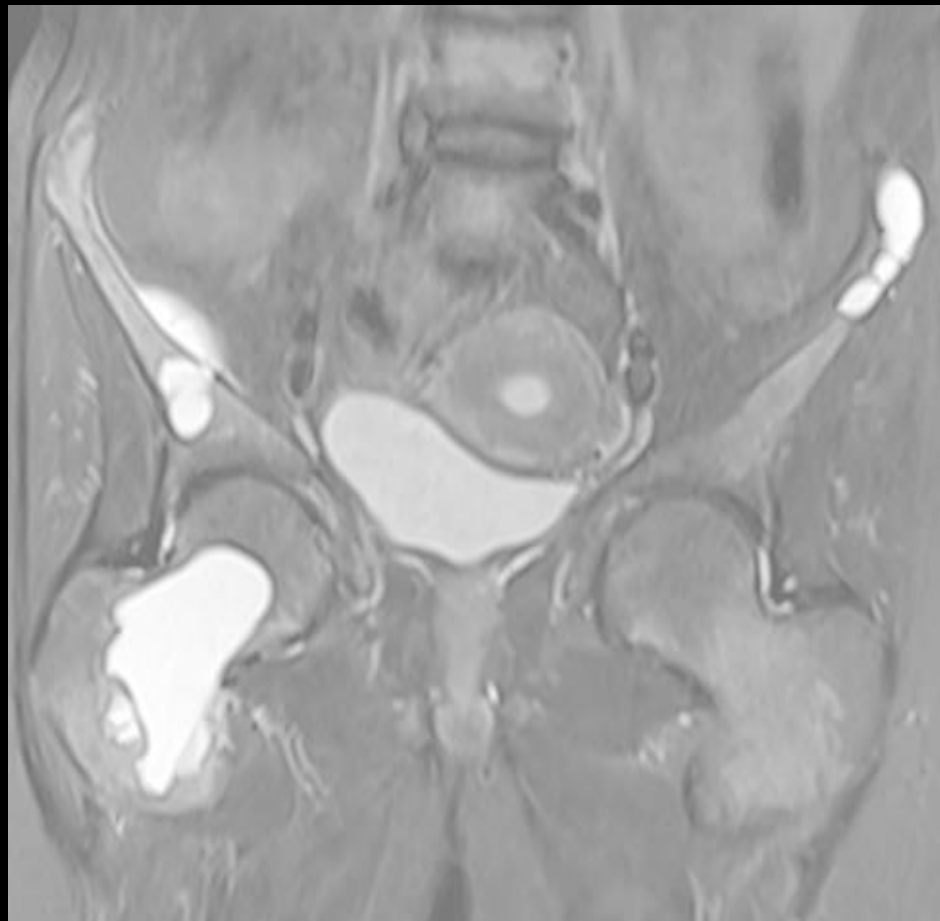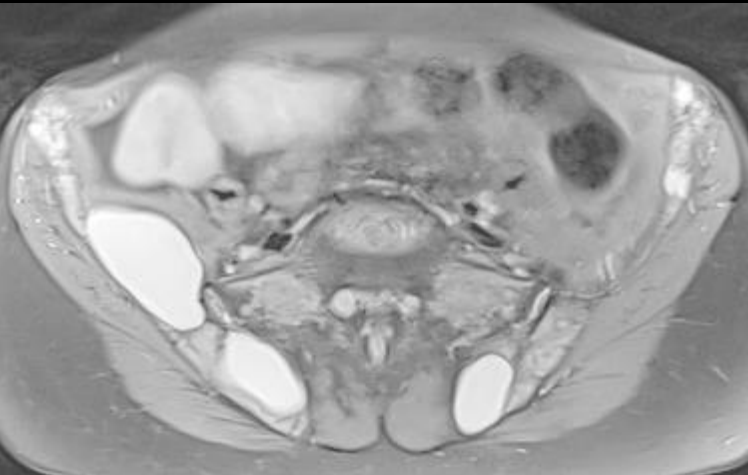
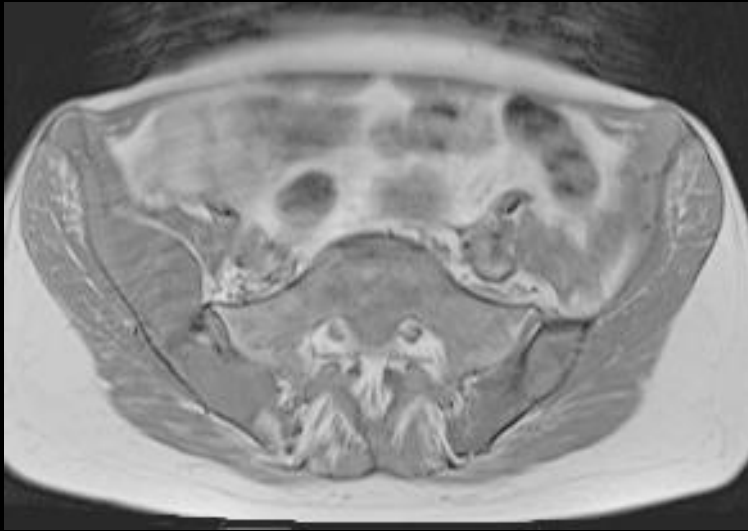Case contributor – Dr. Vaishali Upadhyaya

MI-COD

MSS INDIA- Case Of the Day



20-year-old lady with weakness and history of pain in the pelvic region for past few months (history partially withheld)



Axial T1, PD Fat sat, Coronal STIR & Sagittal PD MR images