

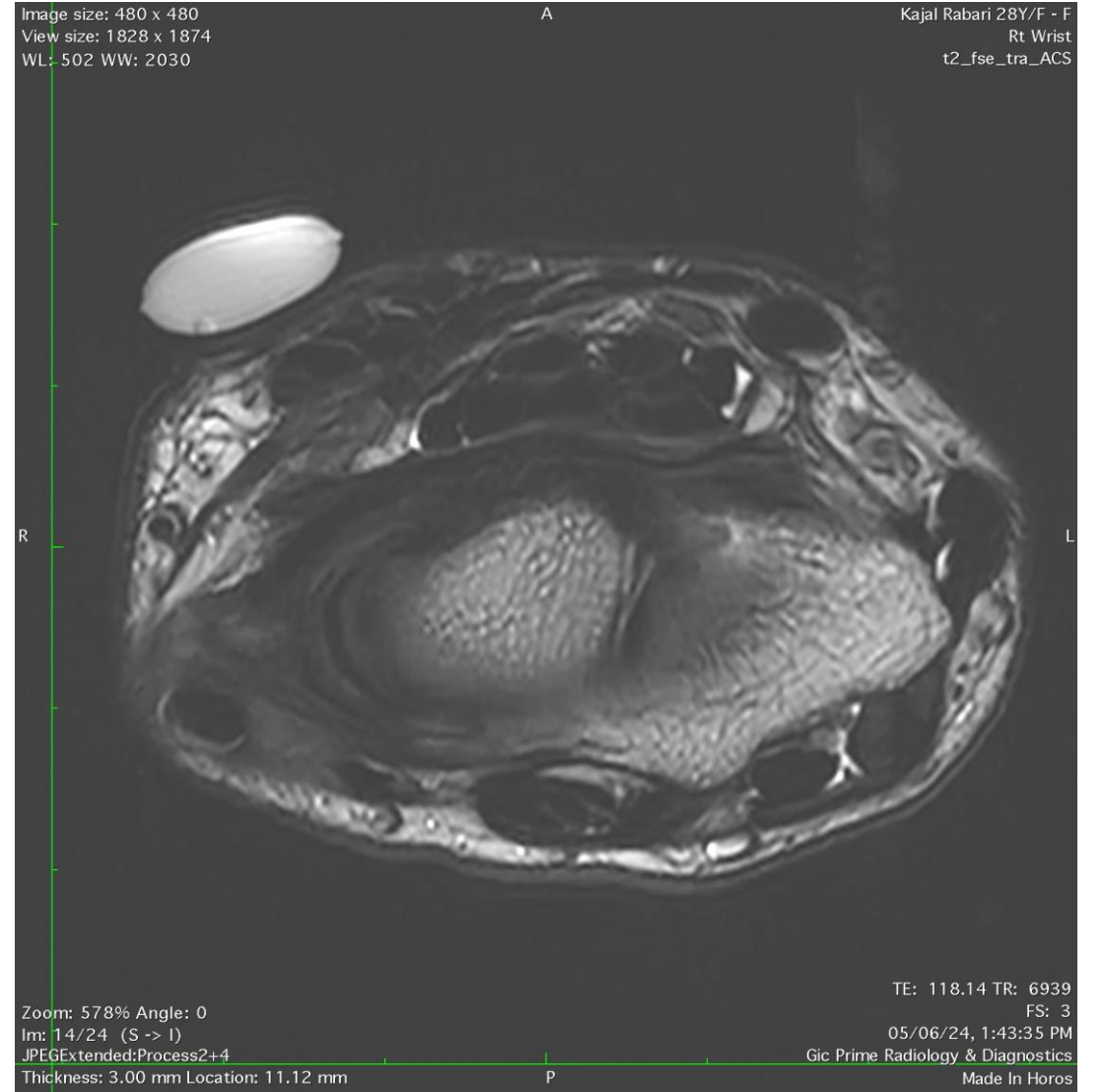
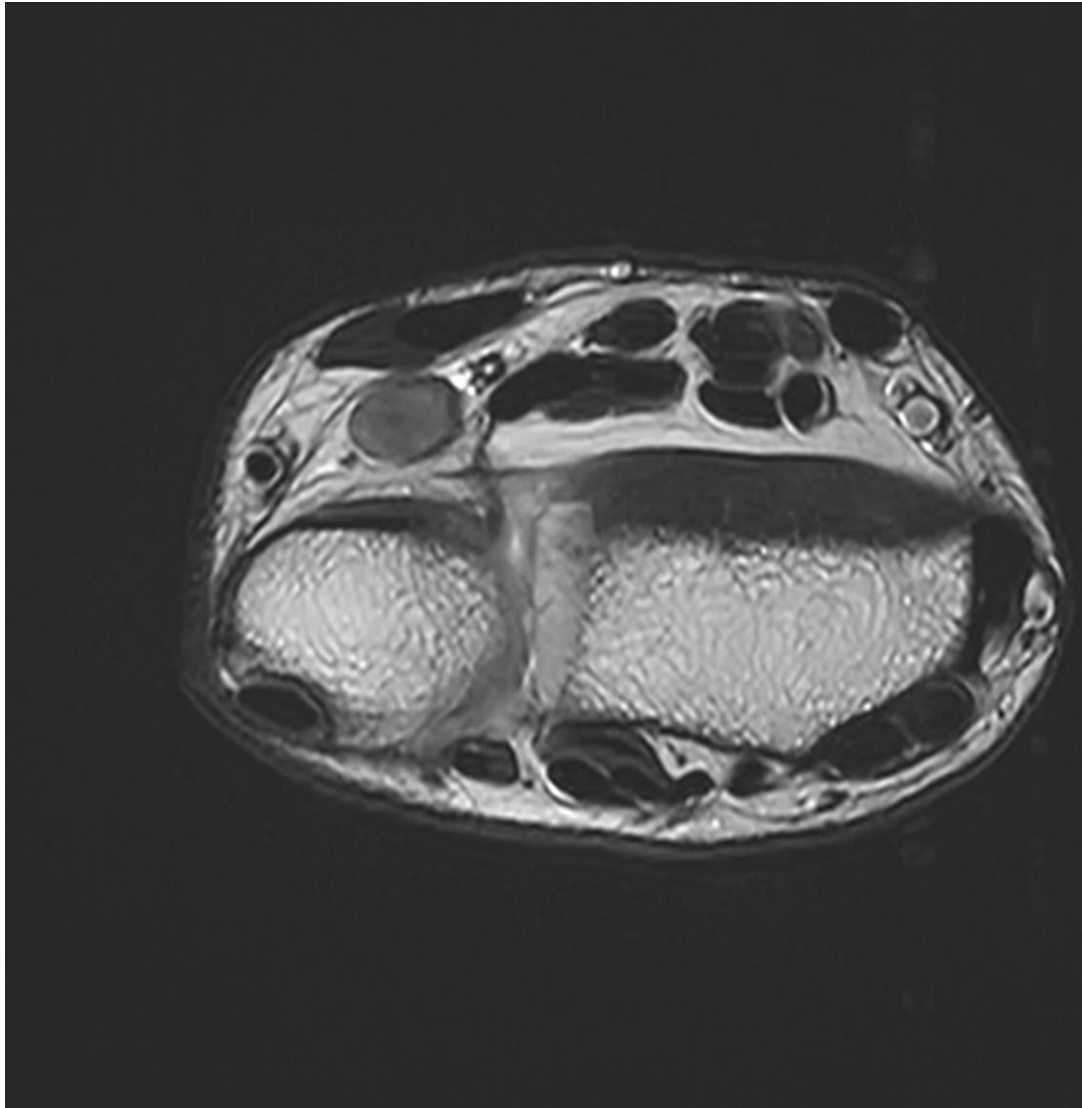
MICOD –17/06/2024

Case contributor – Dr. Ankur Shah

MI-COD

MSS INDIA- Case Of the Day





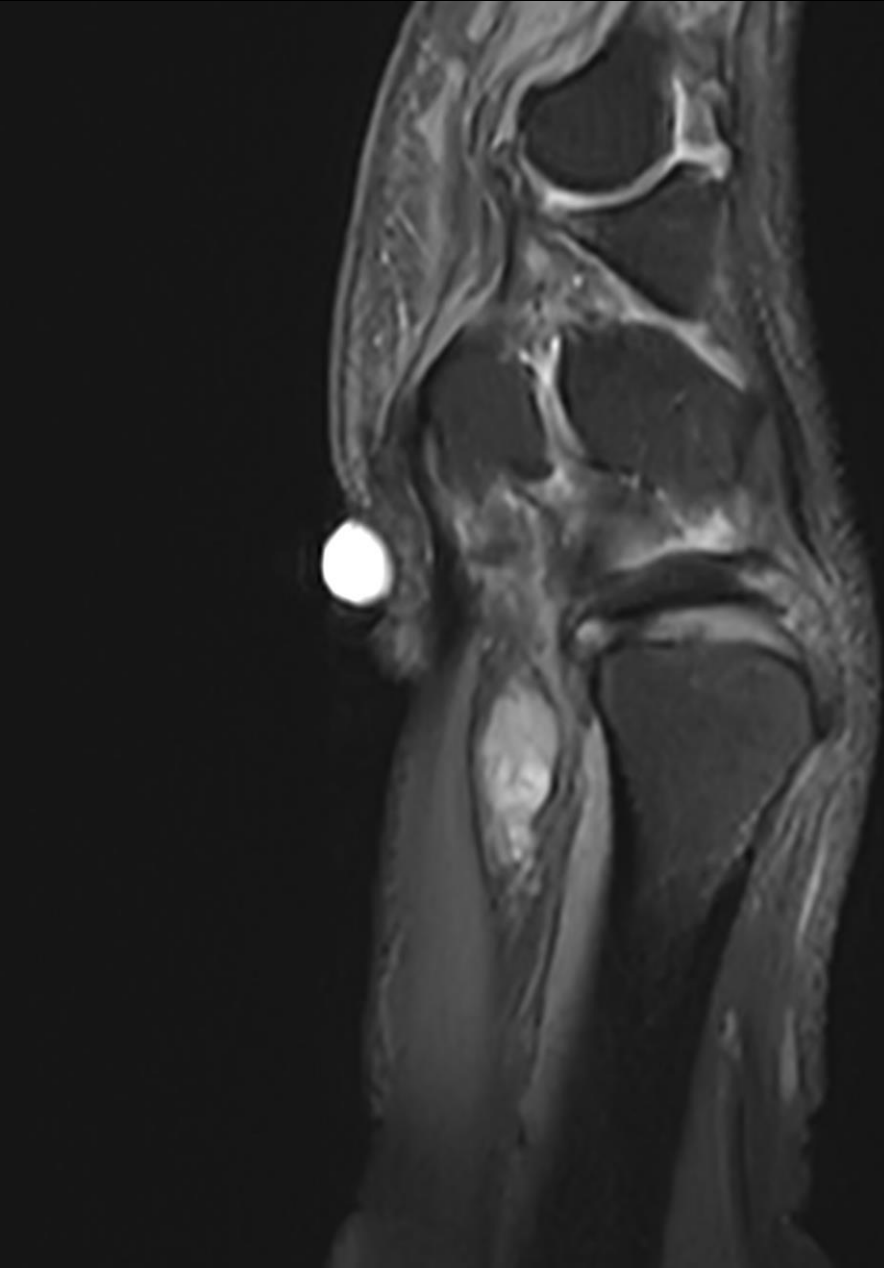
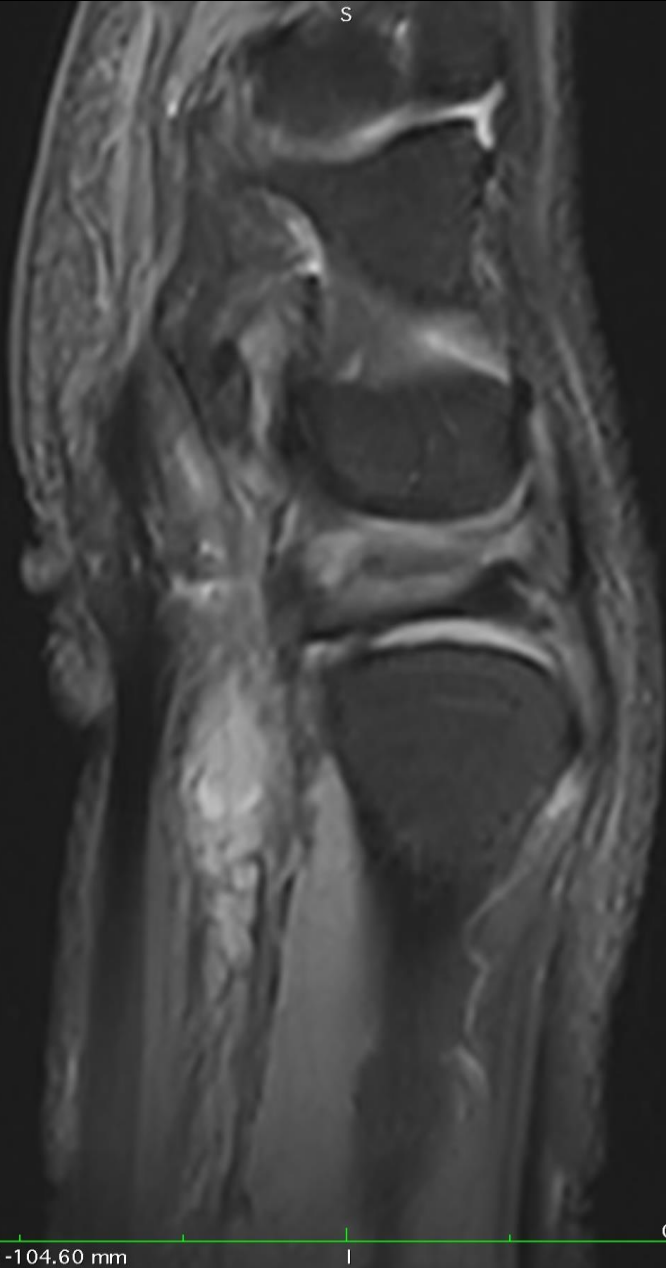


Image size: 408 x 397
View size: 1828 x 1874
WL: 784 WW: 1964



Kajal Rabari 28Y/F
Rt Wr
pd_fse_sag_fs_A

A

Zoom: 701% Angle: 0
Im: 6/23 R (R -> L)
JPEGExtended:Process2+4

Thickness: 2.50 mm Location: -104.60 mm

TE: 40.48 TR: 248
FS:

05/06/24, 1:46:51 PM

Gic Prime Radiology & Diagnostic

Made In Hong Kong

- History of injury with a sharp glass before 2 months.
C/o numbness in the ring and little fingers.

