

MICOD – 13/06/2024  
Case contributor – Dr. Ankur Shah

# MI-COD

MSS INDIA- Case Of the Day



- 
- MRI OF A RYAN (DOG)-----  
DIAGNOSIS ????

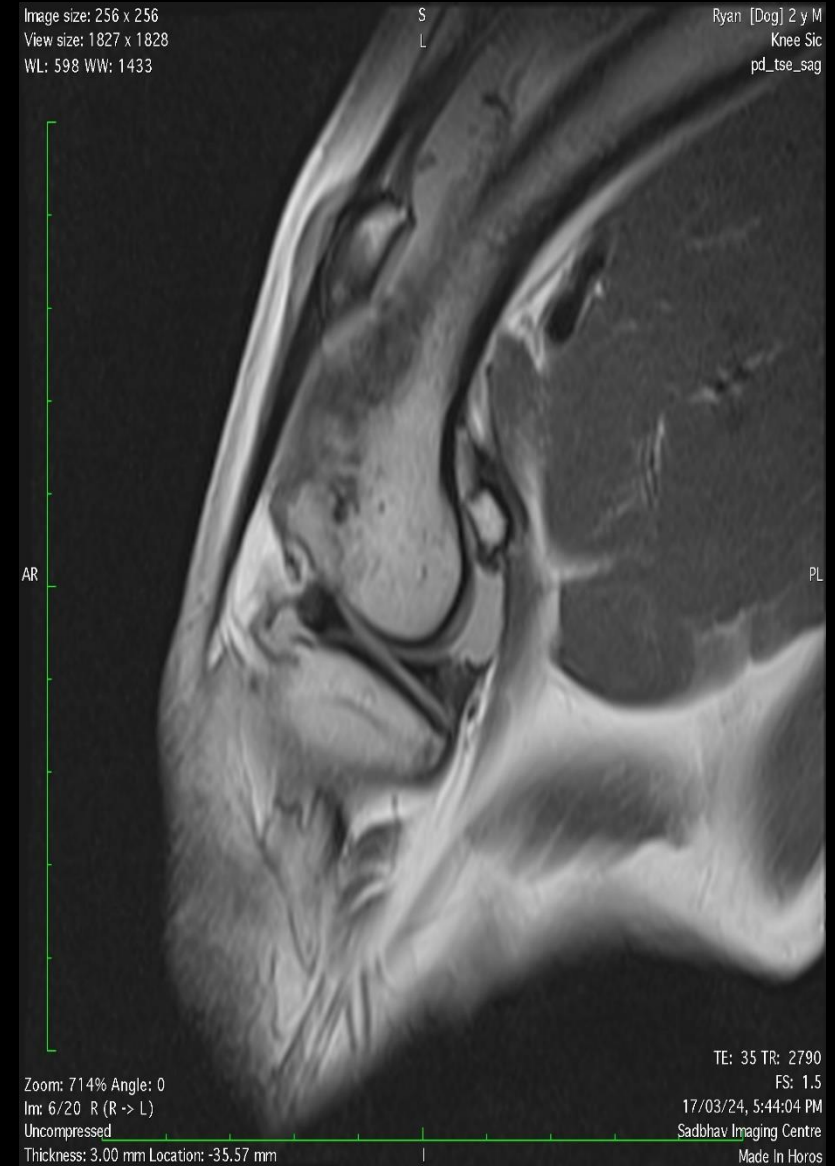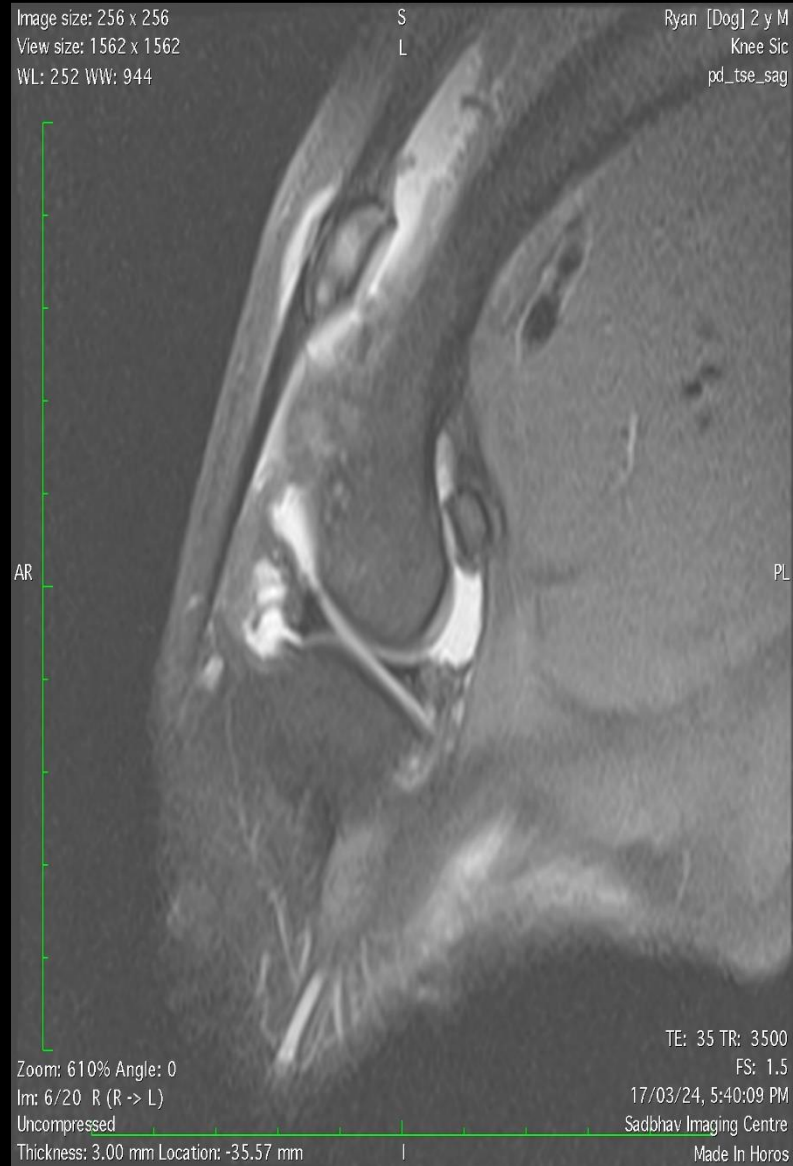


Image size: 256 x 256  
View size: 1827 x 1828  
WL: 599 WW: 1636

ASR  
L

Ryan [Dog] 2 y M  
Knee Sic  
t2\_tse\_tra\_320

