

MICOD – 12/06/2024
Case contributor – Dr. Ankur Shah

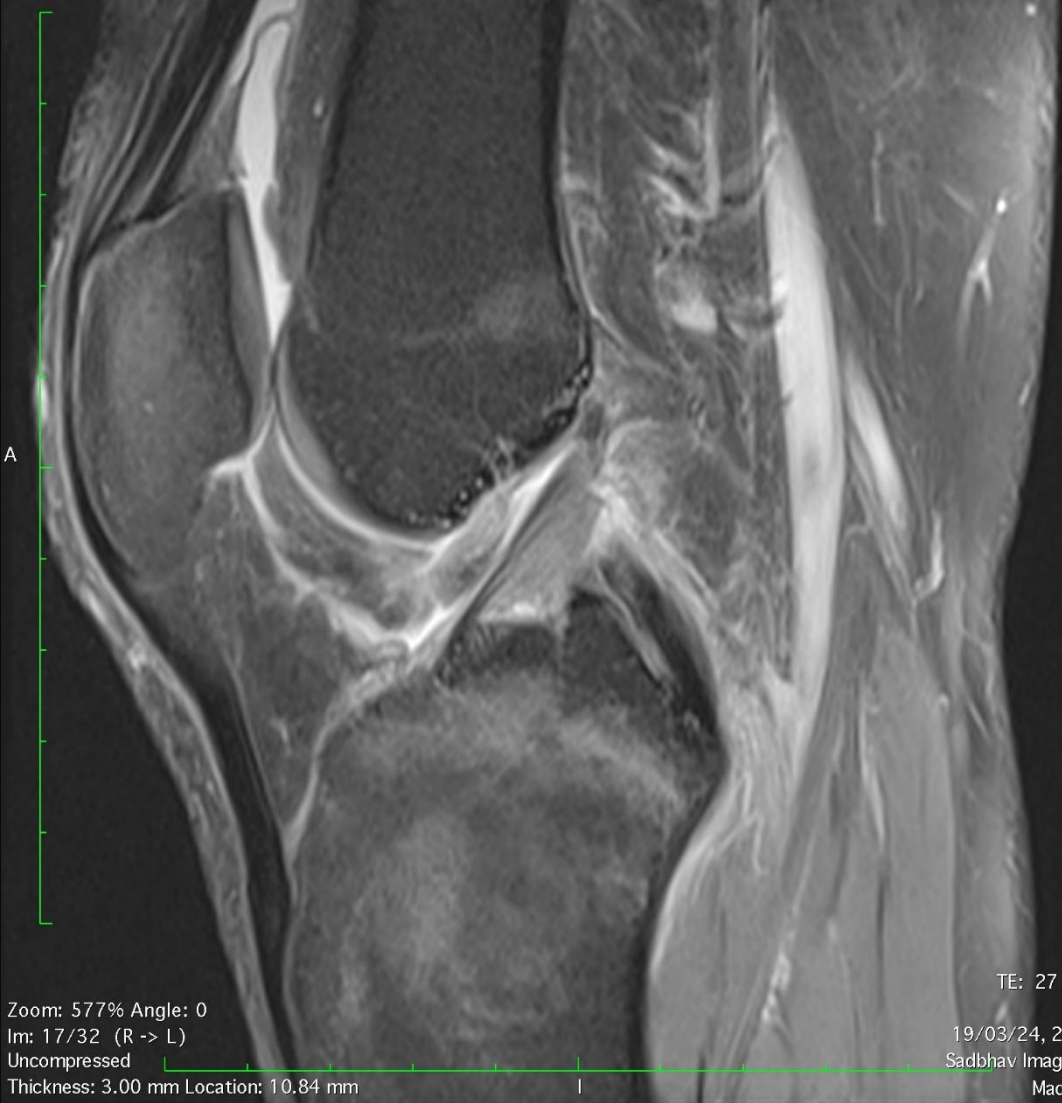MI-COD

MSS INDIA- Case Of the Day



Image size: 320 x 320
View size: 1845 x 1841
WL: 497 WW: 1233

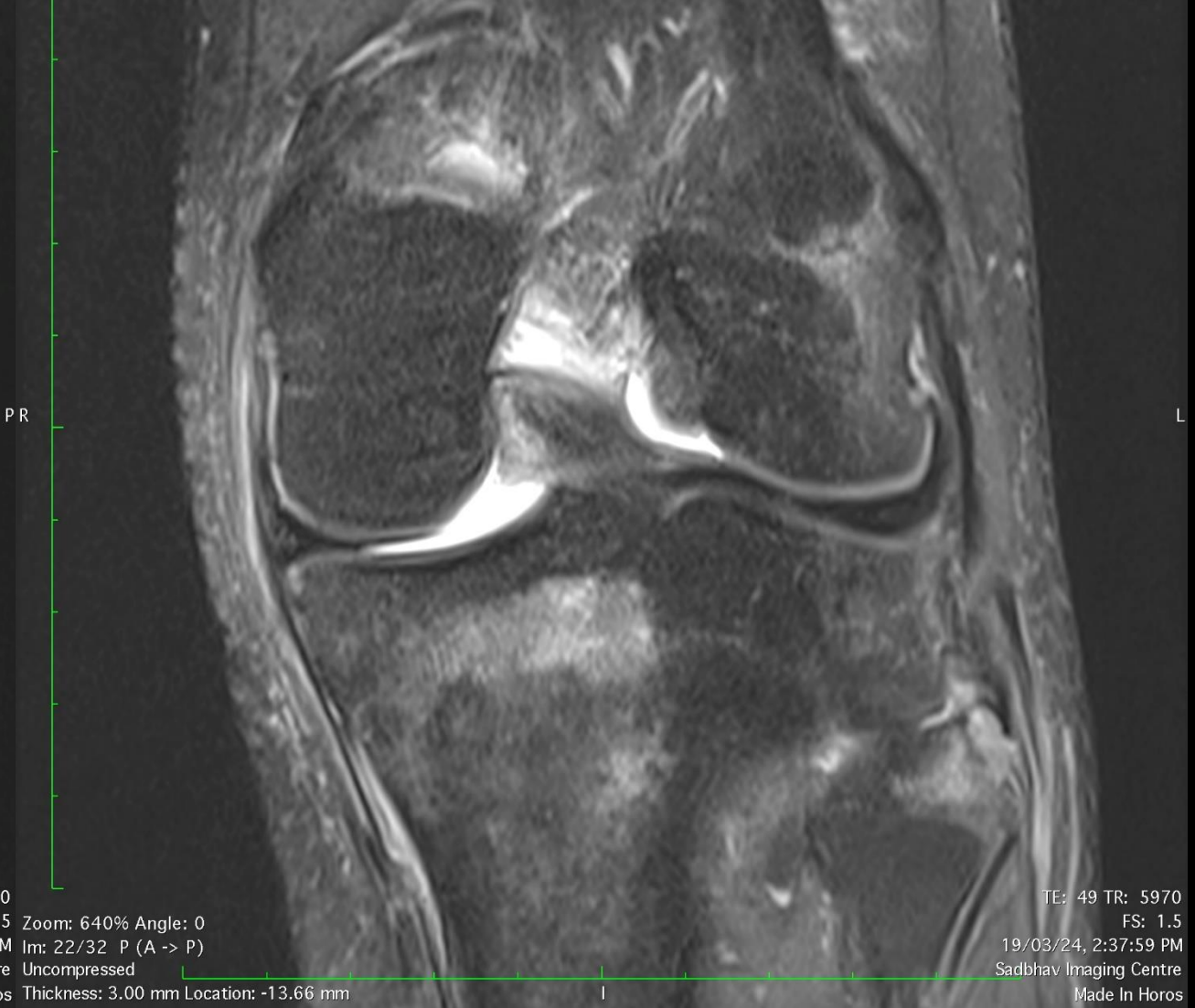S



Zoom: 577% Angle: 0
Im: 17/32 (R -> L)
Uncompressed
Thickness: 3.00 mm Location: 10.84 mm

Image size: 320 x 320
View size: 2047 x 1845
WL: 345 WW: 914

S

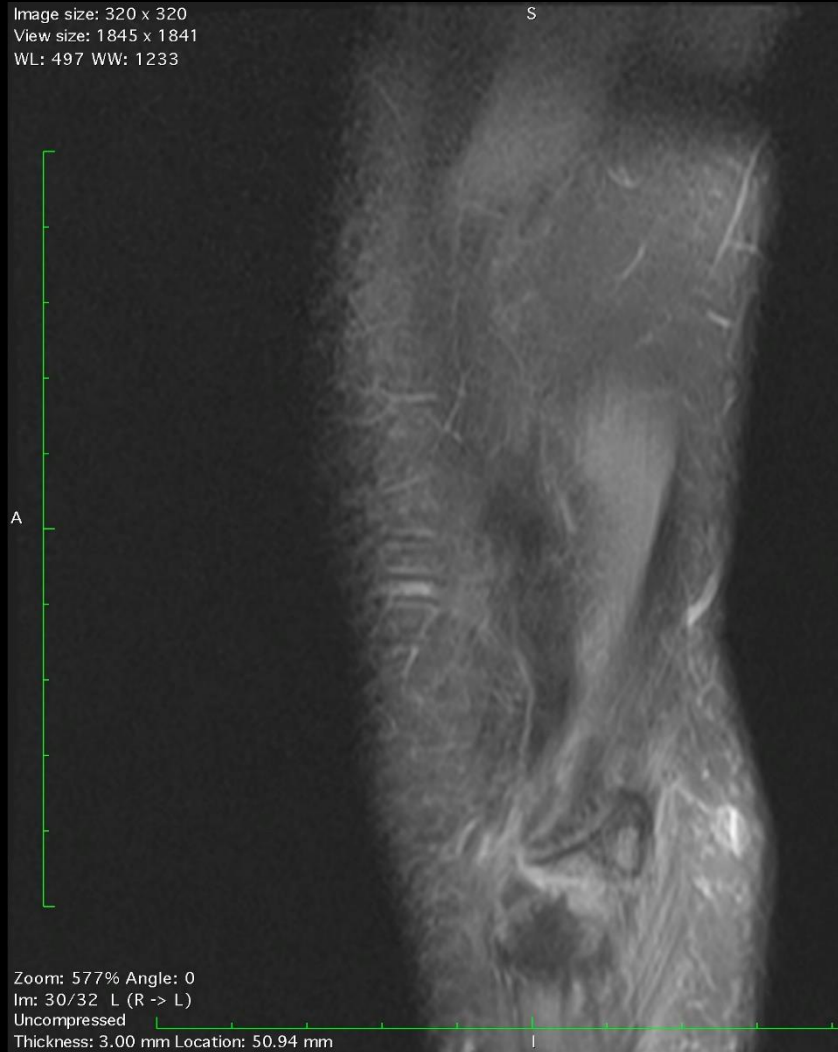


Zoom: 640% Angle: 0
Im: 22/32 P (A -> P)
Uncompressed
Thickness: 3.00 mm Location: -13.66 mm

TE: 27 TR: 3820
FS: 1.5
19/03/24, 2:33:08 PM
Sadbhav Imaging Centre
Made In Horos

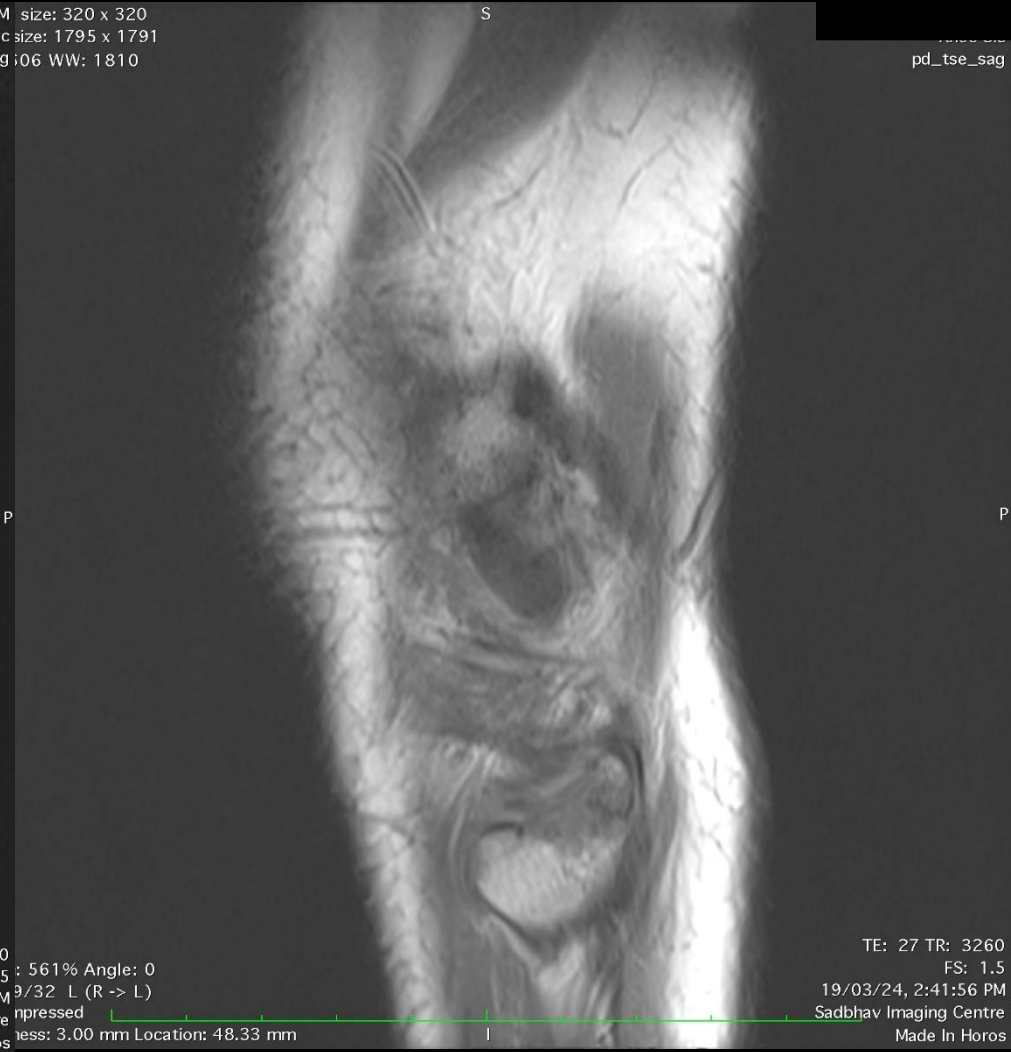TE: 49 TR: 5970
FS: 1.5
19/03/24, 2:37:59 PM
Sadbhav Imaging Centre
Made In Horos

Image size: 320 x 320
View size: 1845 x 1841
WL: 497 WW: 1233



Zoom: 577% Angle: 0
Im: 30/32 L (R -> L)
Uncompressed
Thickness: 3.00 mm Location: 50.94 mm

M size: 320 x 320
View size: 1795 x 1791
pd_tse_fs_sag;06 WW: 1810



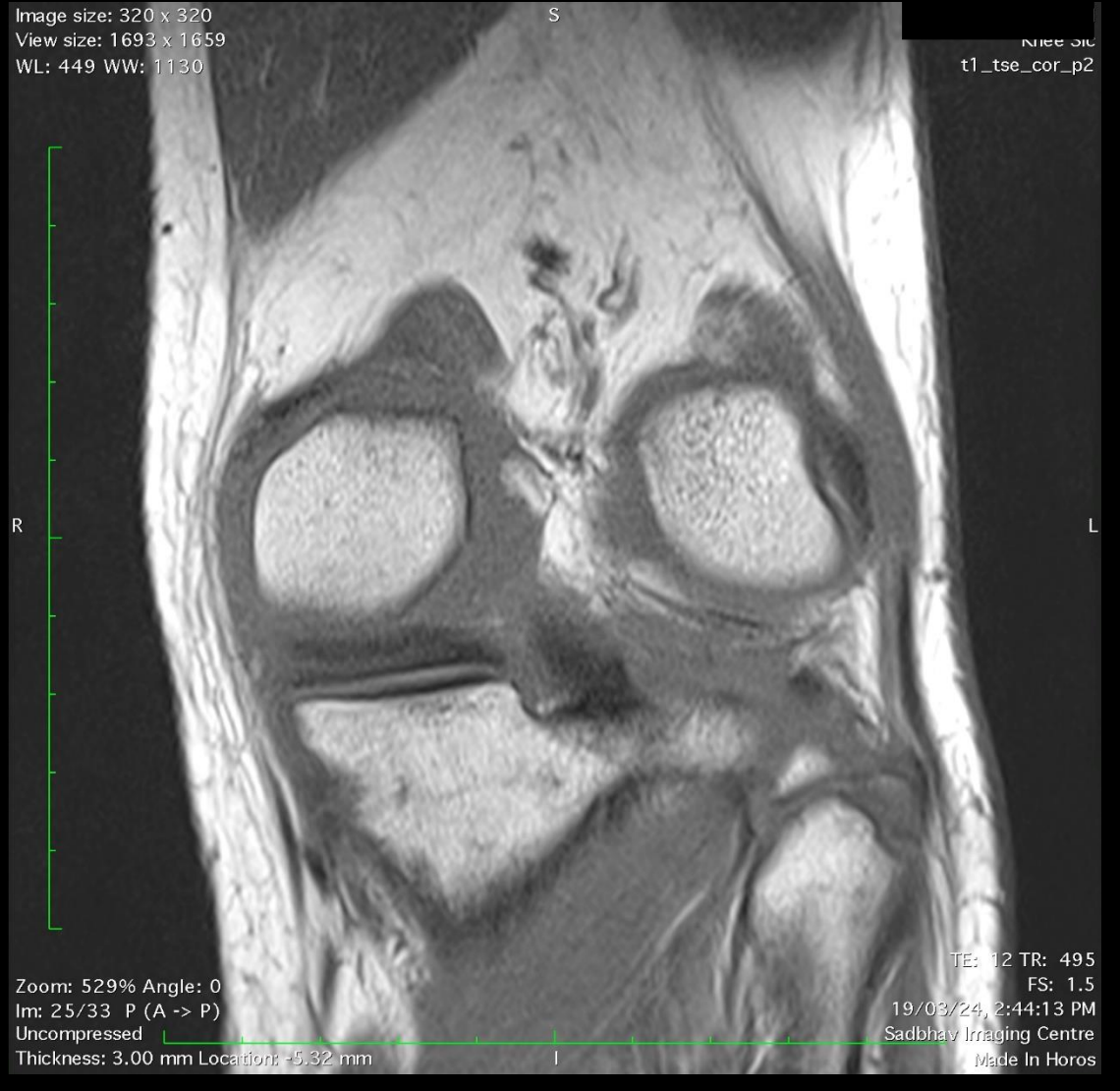
TE: 27 TR: 3820
FS: 1.5 : 561% Angle: 0
19/03/24, 2:33:07 PM 9/32 L (R -> L)
Sadbhav Imaging Centre npressed
Thickness: 3.00 mm Location: 48.33 mm
Made In Horos

TE: 27 TR: 3260
FS: 1.5
19/03/24, 2:41:56 PM
Sadbhav Imaging Centre
Made In Horos

Image size: 320 x 320
View size: 1939 x 1781
WL: 462 WW: 1258

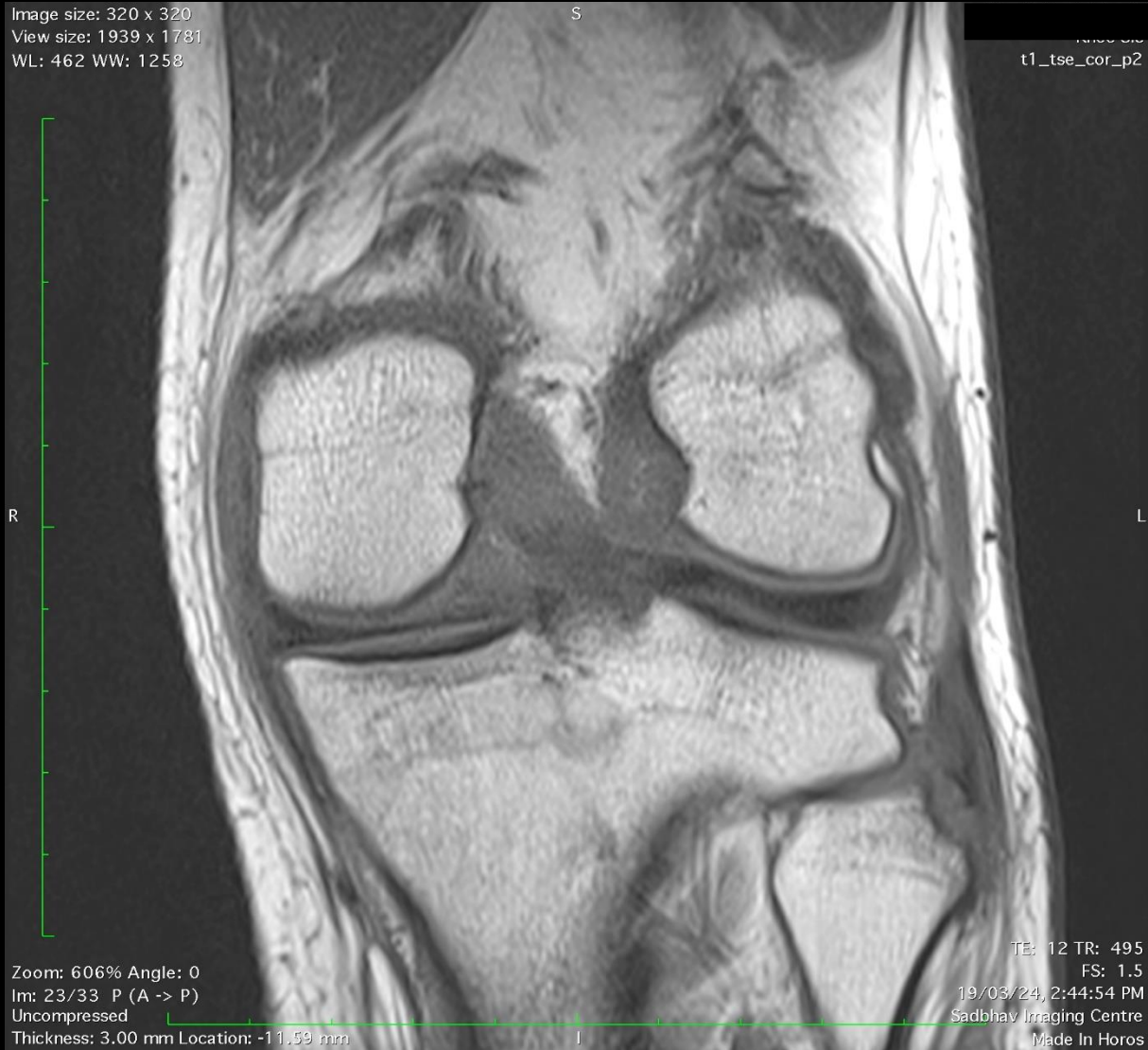

Image size: 320 x 320
View size: 1693 x 1659
WL: 449 WW: 1130



DIAGNOSIS

