

MICOD – 10/06/2024

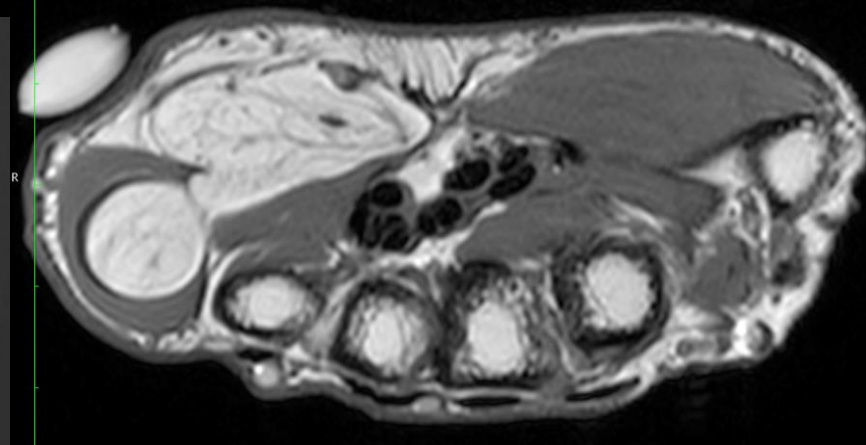
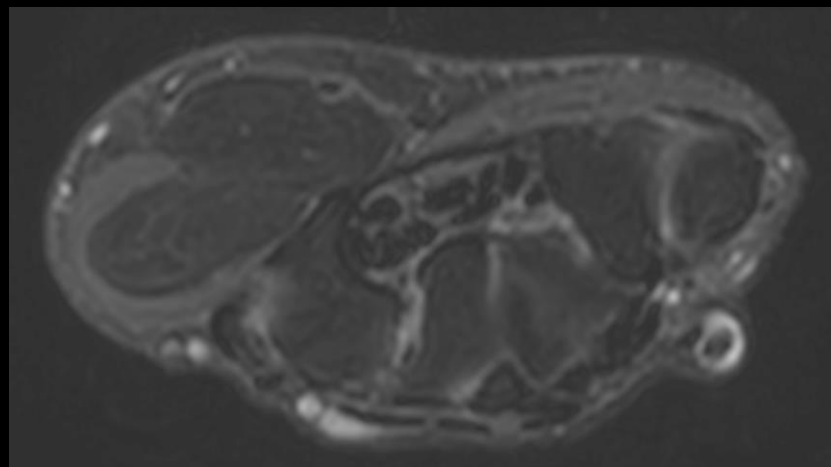
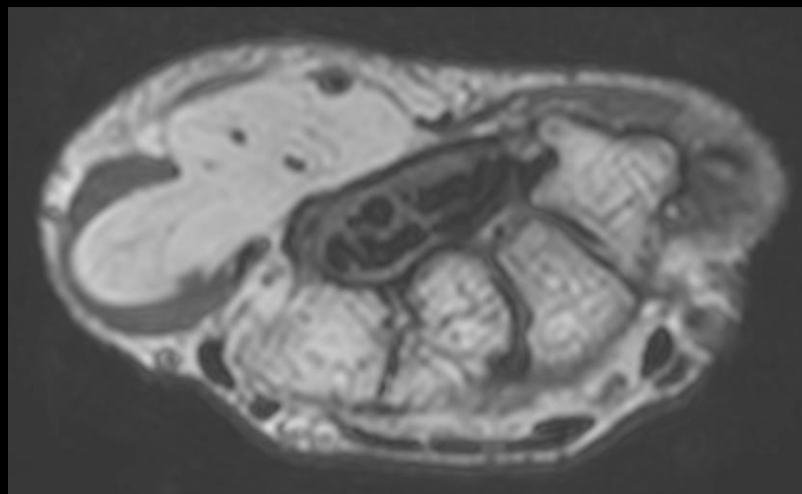
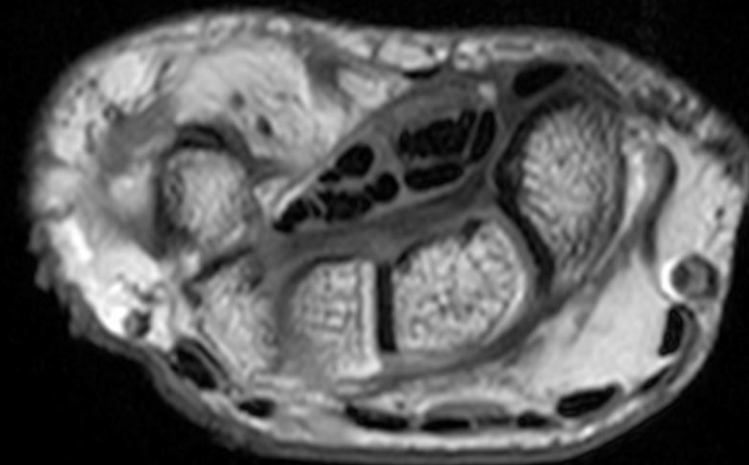
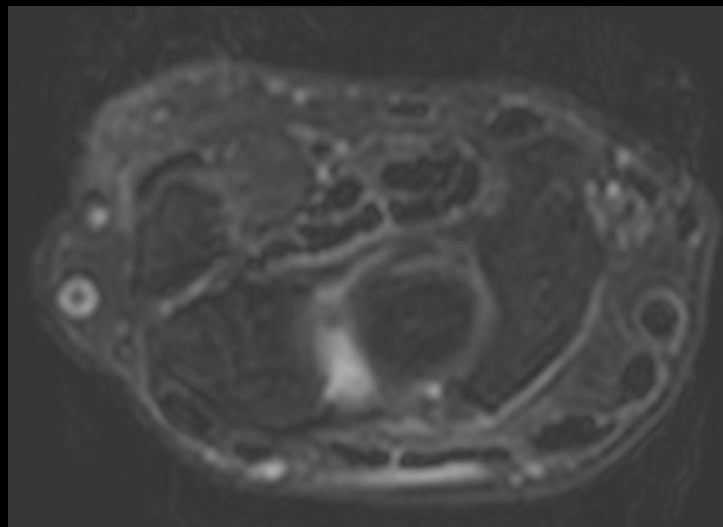
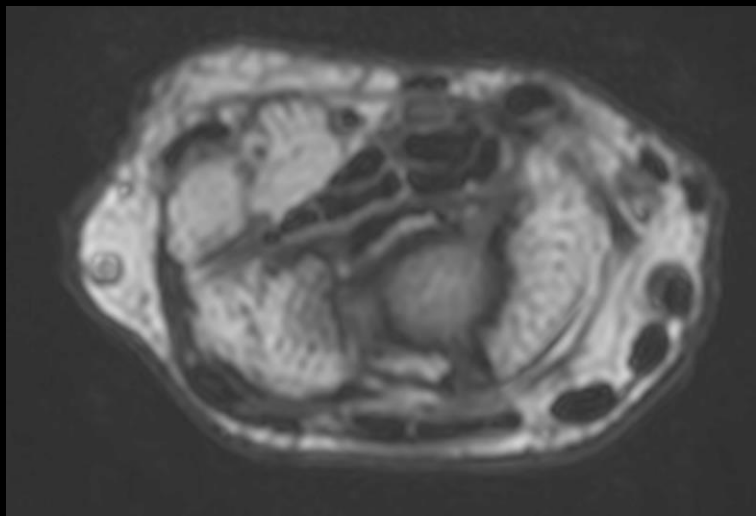
Case contributor – Dr. Ankur Shah

MI-COD

MSS INDIA- Case Of the Day



Diagnosis?



T2

STIR

T1

Diagnosis?

