

MICOD – 06/06/2024

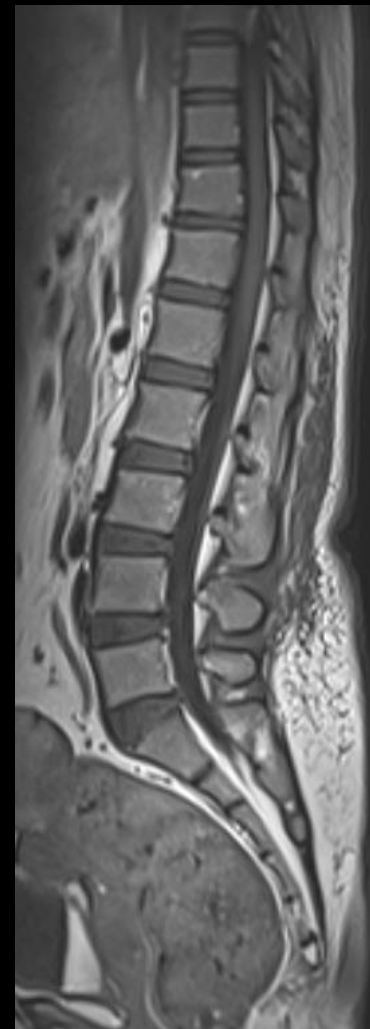
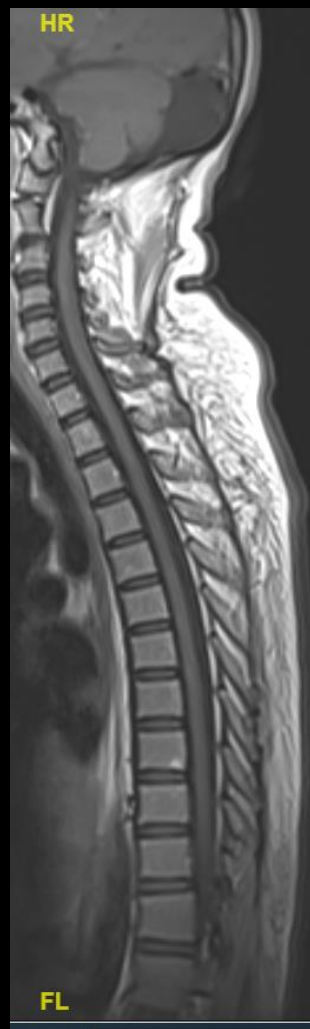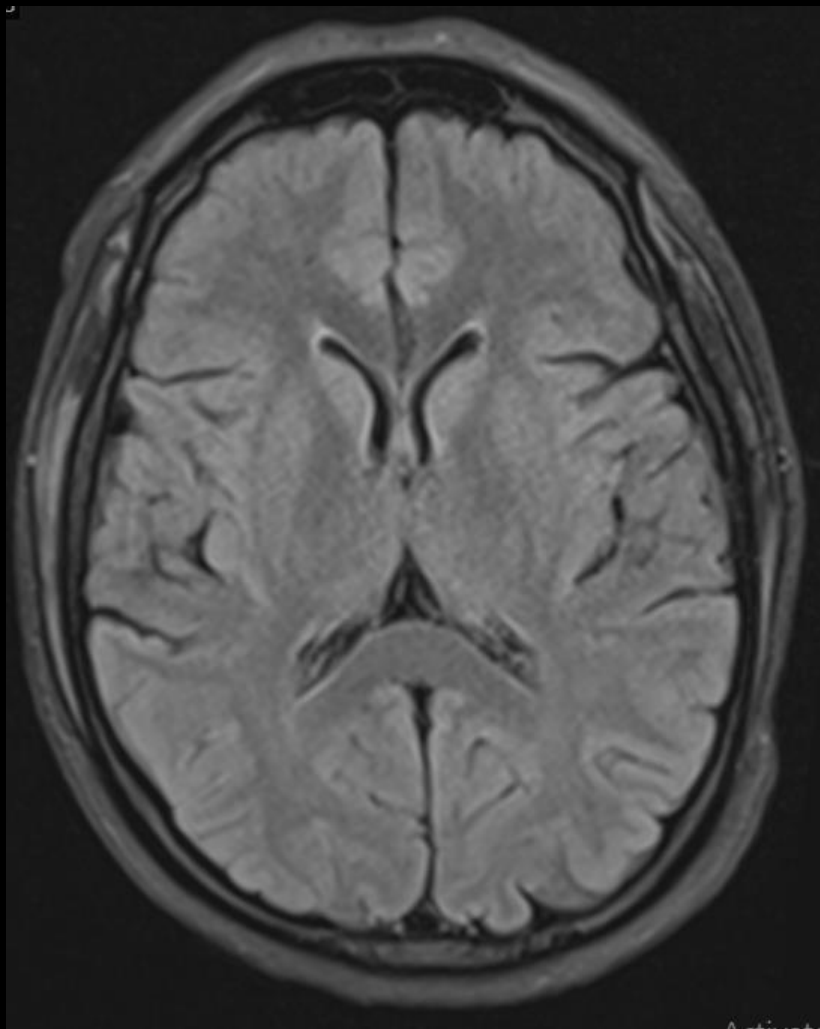
Case contributor – Dr. Praveen Kumar Chinniah

MI-COD

MSS INDIA- Case Of the Day



35-year-old lady with flaccid quadriplegia



Spoiler alert – Clue coming next



35-year-old lady with flaccid quadriplegia

