


MICOD – 03/06/2024

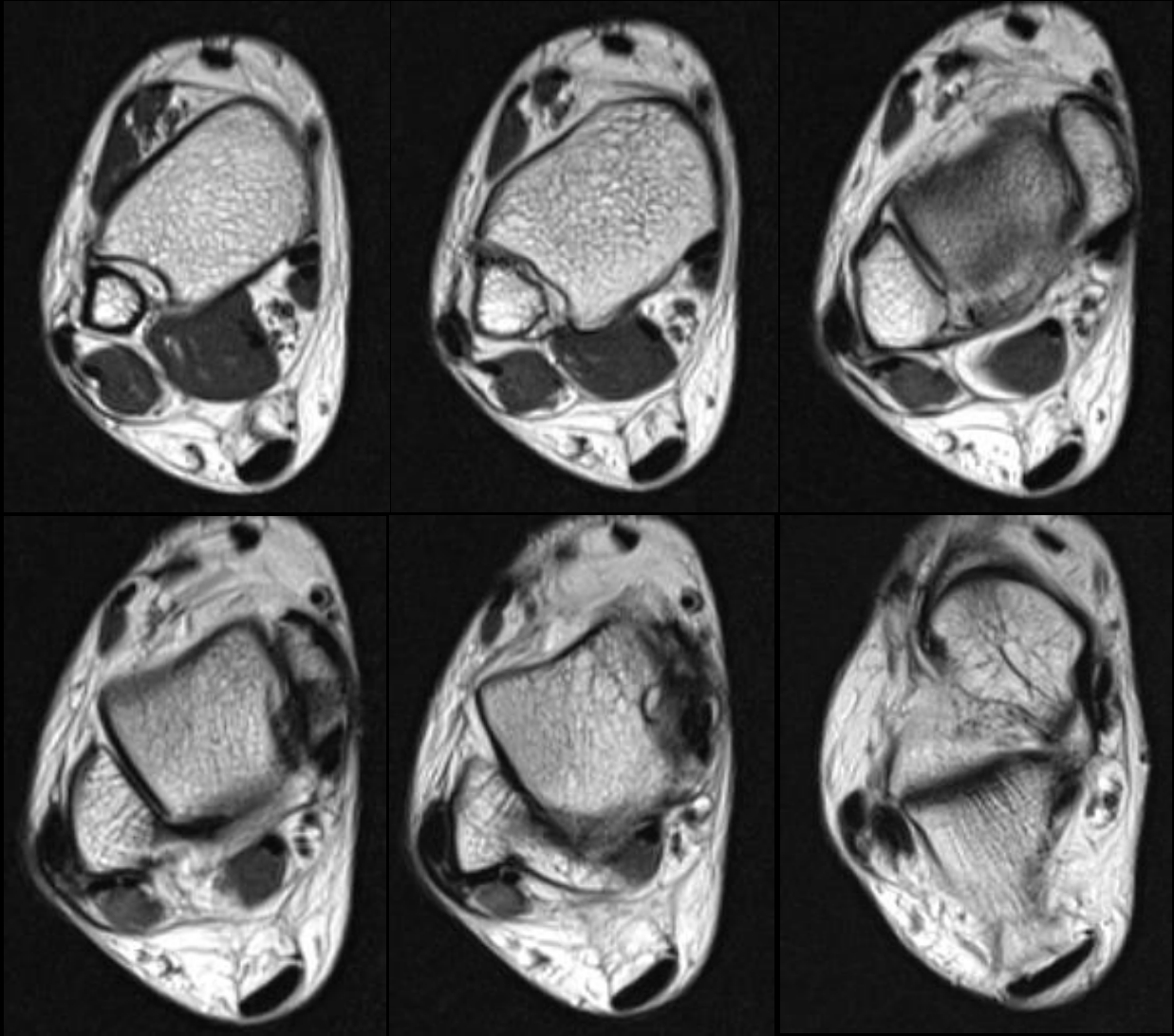
Case contributor – Dr. Surendra Kumar

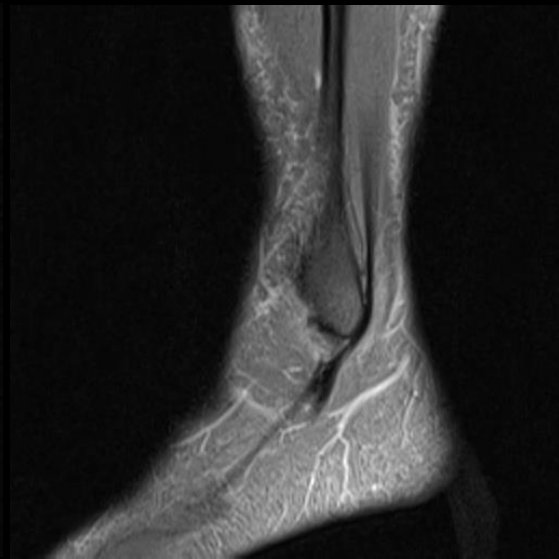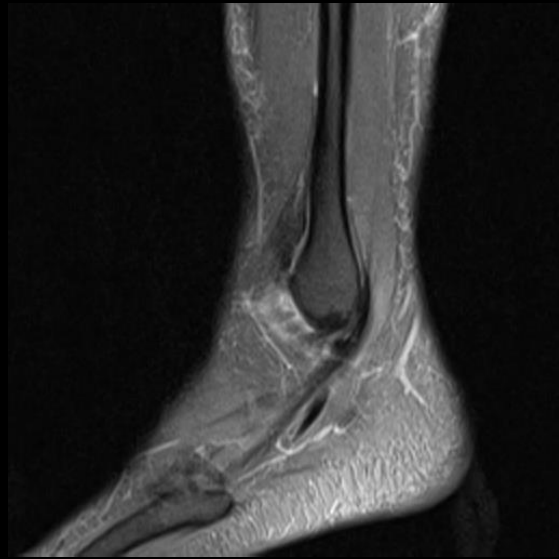
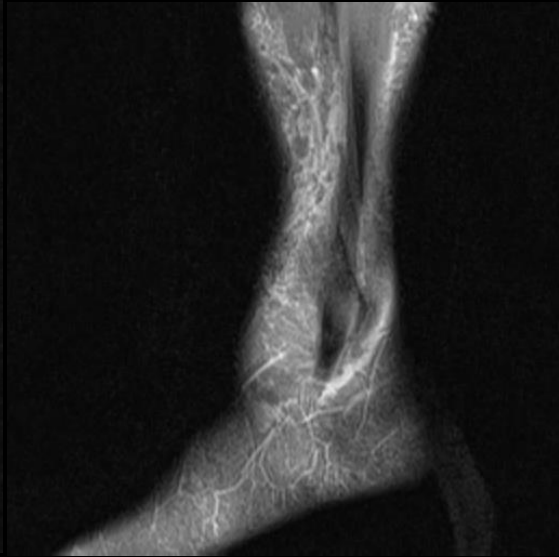
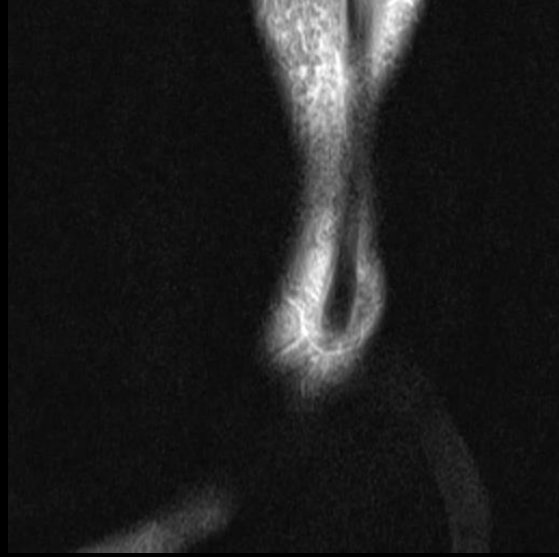
MI-COD

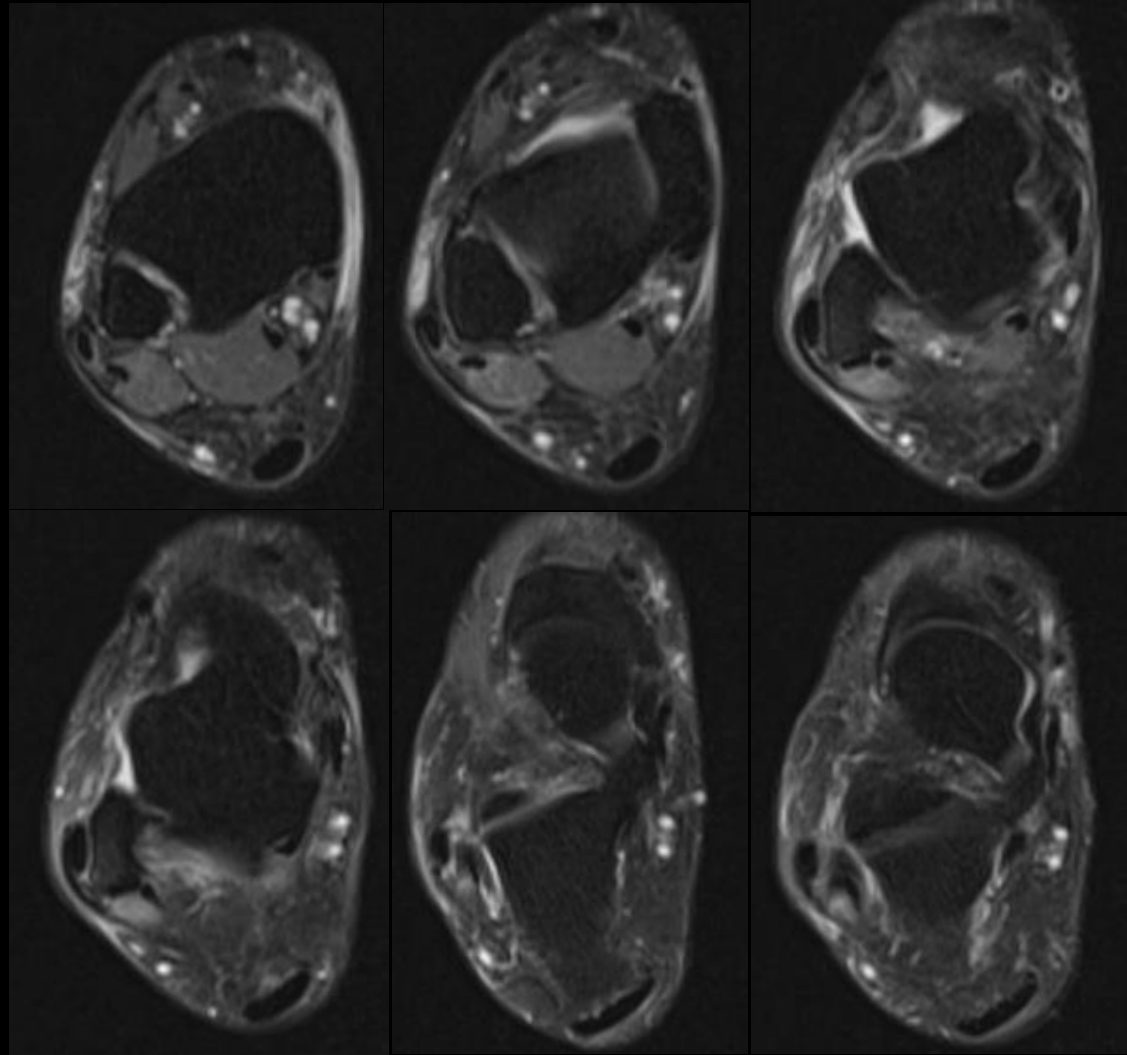
MSS INDIA- Case Of the Day



- 35 yr old female with pain in the lateral aspect of right ankle







ANSWER

