

MICOD – 28/05/2024

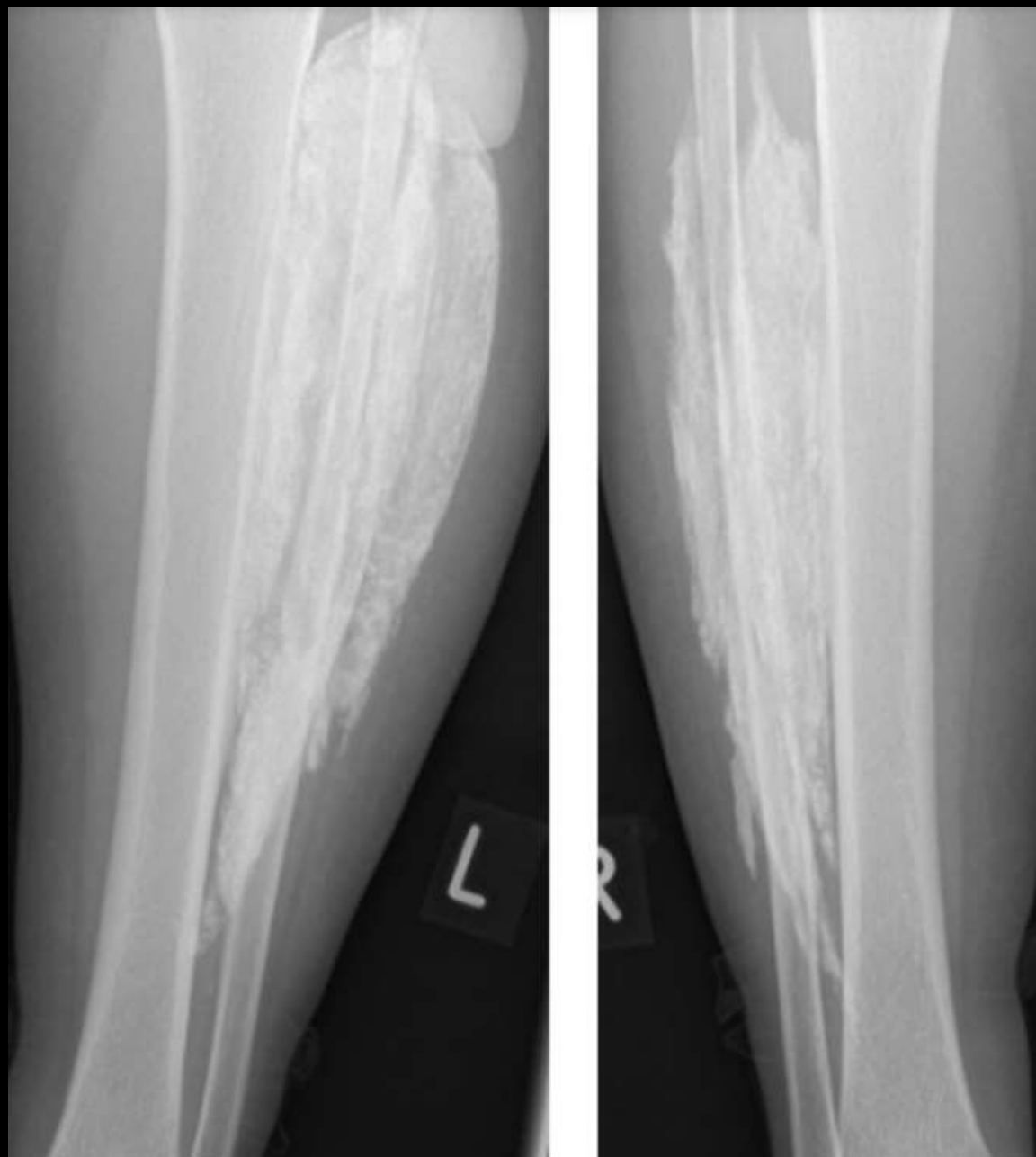
Case contributor – Dr. Rajesh Botchu

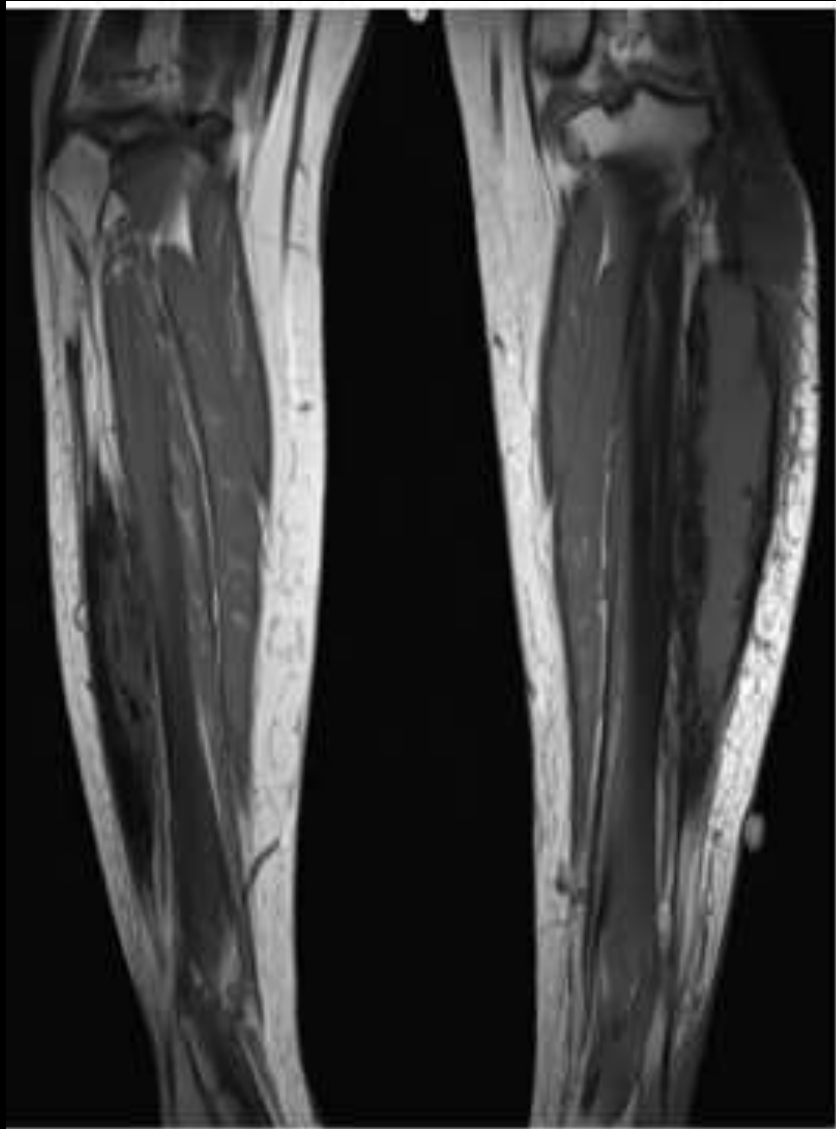
MI-COD

MSS INDIA- Case Of the Day

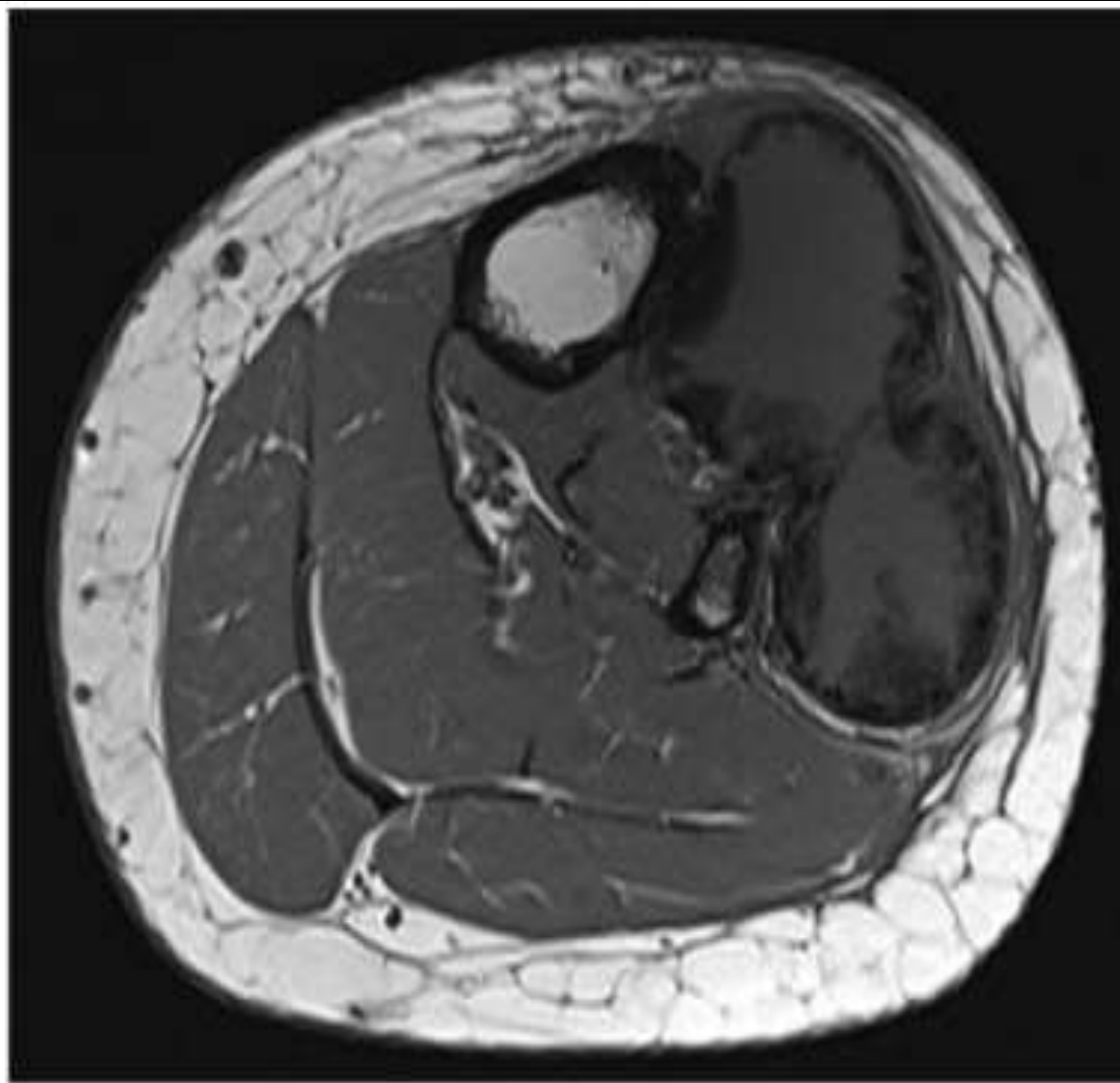


Female patient was referred to the outpatient clinic at Royal Orthopaedic Hospital, Birmingham with a 4-month history of a gradually enlarging, painful mass in the lateral aspect of left lower leg with similar history of right lower leg pain, but to a much lesser extent.





(a)



(b)

