

MICOD – 27/05/2024

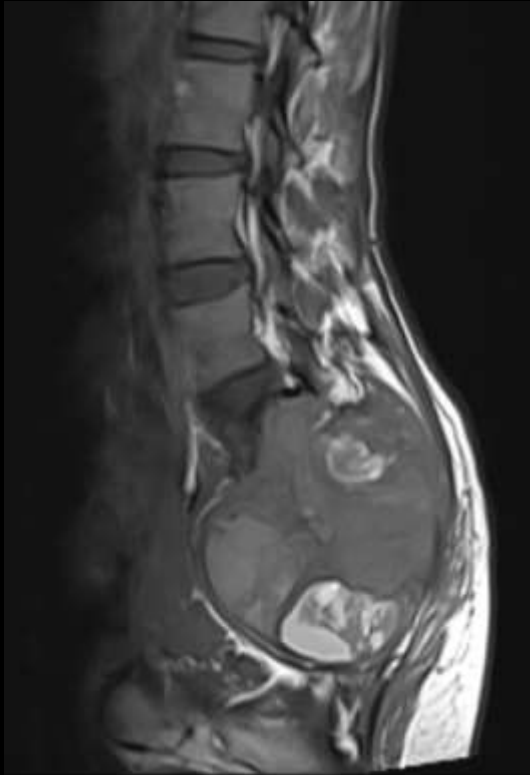
Case contributor – Dr. Harmeet Kaur (AIIMS Bathinda)

MSS INDIA- Case Of the Day

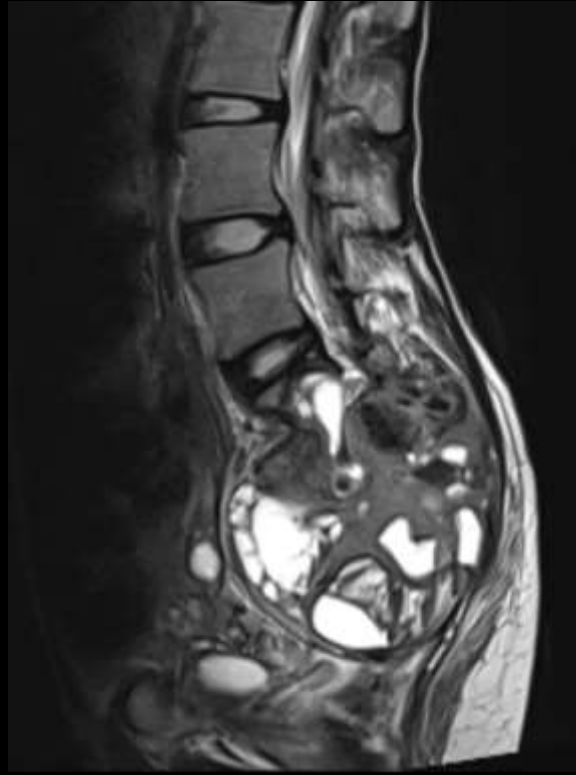


Chief complaints: A 25-year-old female presented with a progressively increasing radiculopathy in her right lower limb. No h/o trauma/Surgery in the past.

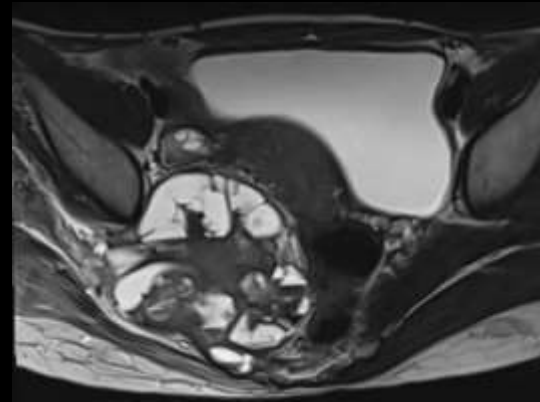
Plain MRI



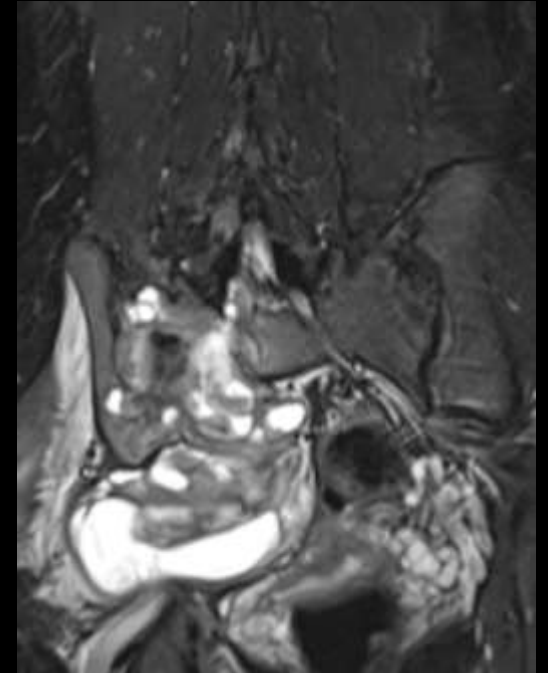
T1 (Sagittal)



Plain T1FS (Sagittal)

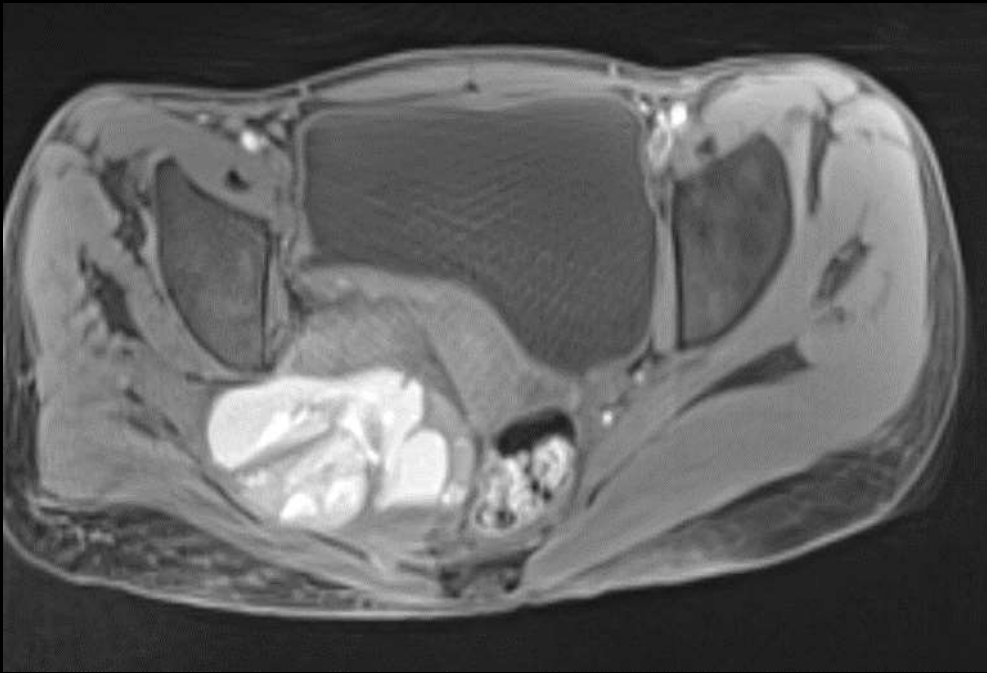


T2 (Axial)

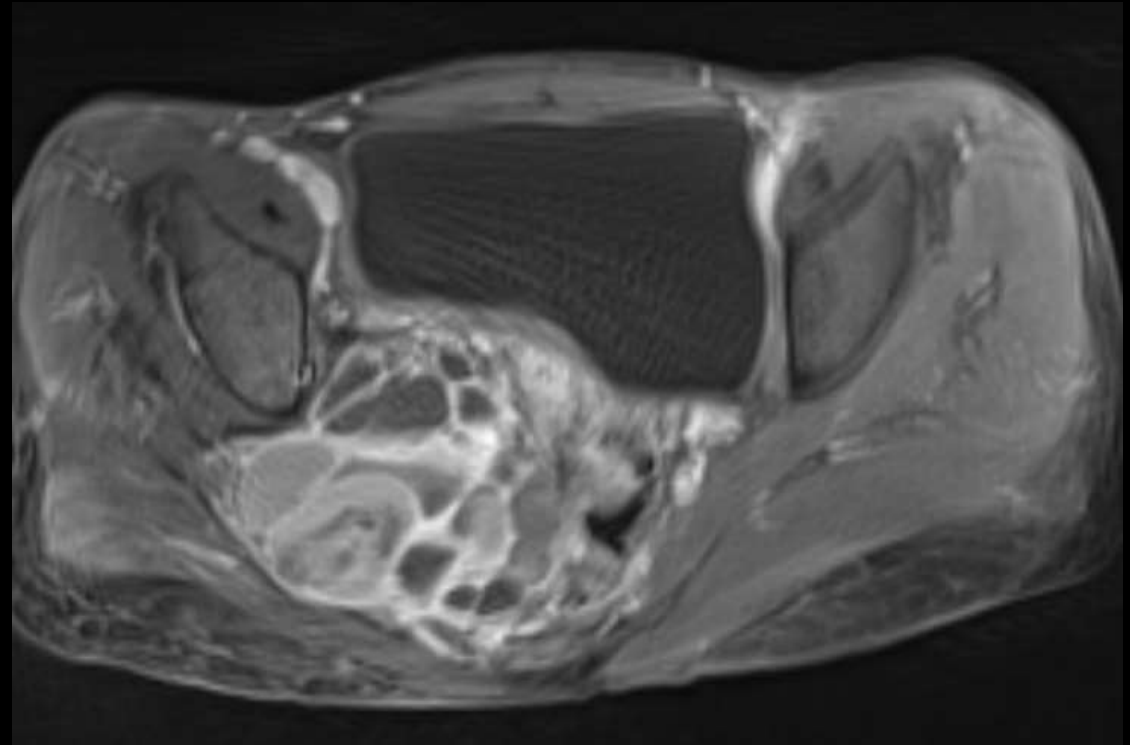


STIR Coronal

Pre & Post-Contrast MRI

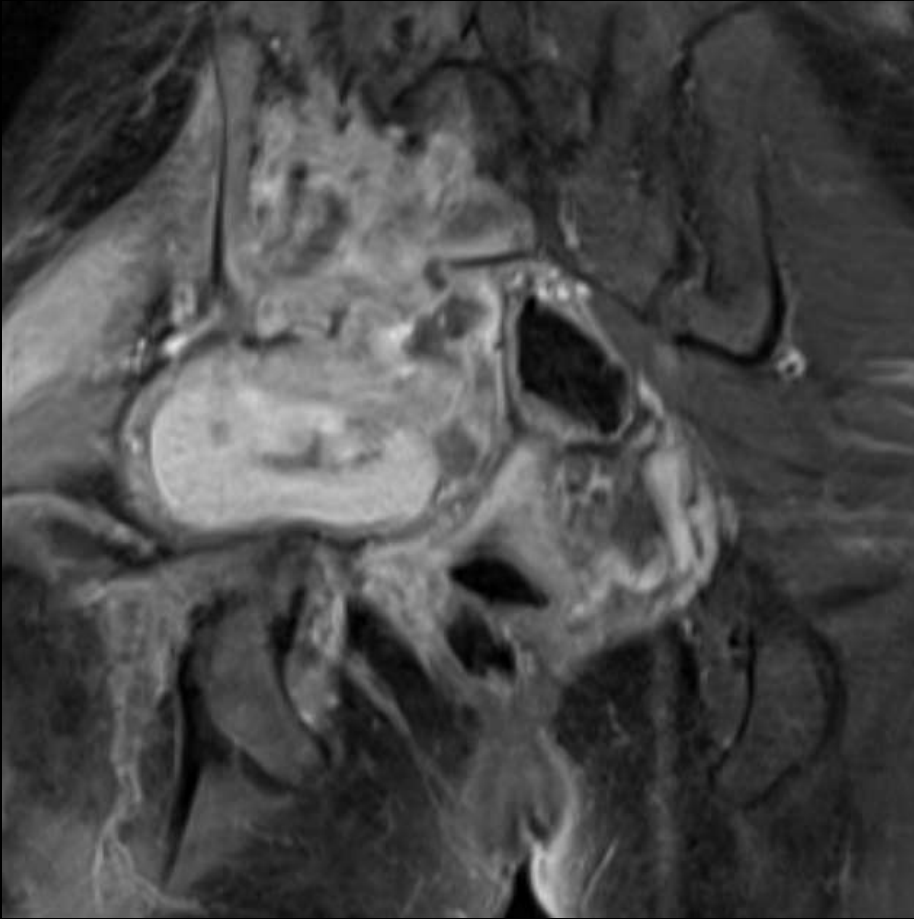


Plain T1FS (Axial)

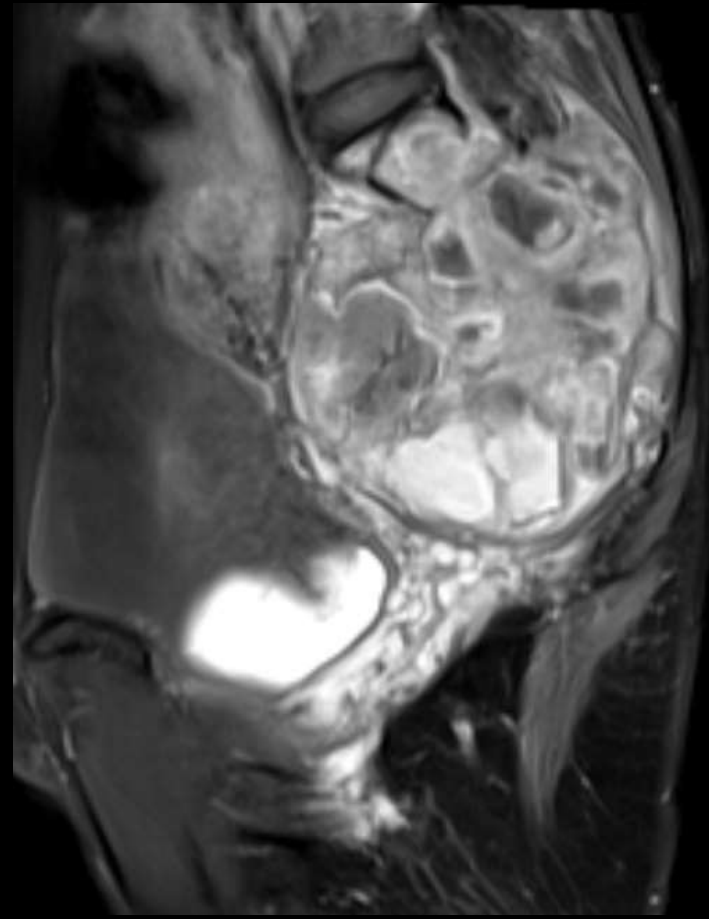


Post-contrast T1FS (Axial)

Contrast MRI



Coronal



Sagittal

