


MICOD – 23/04/2024

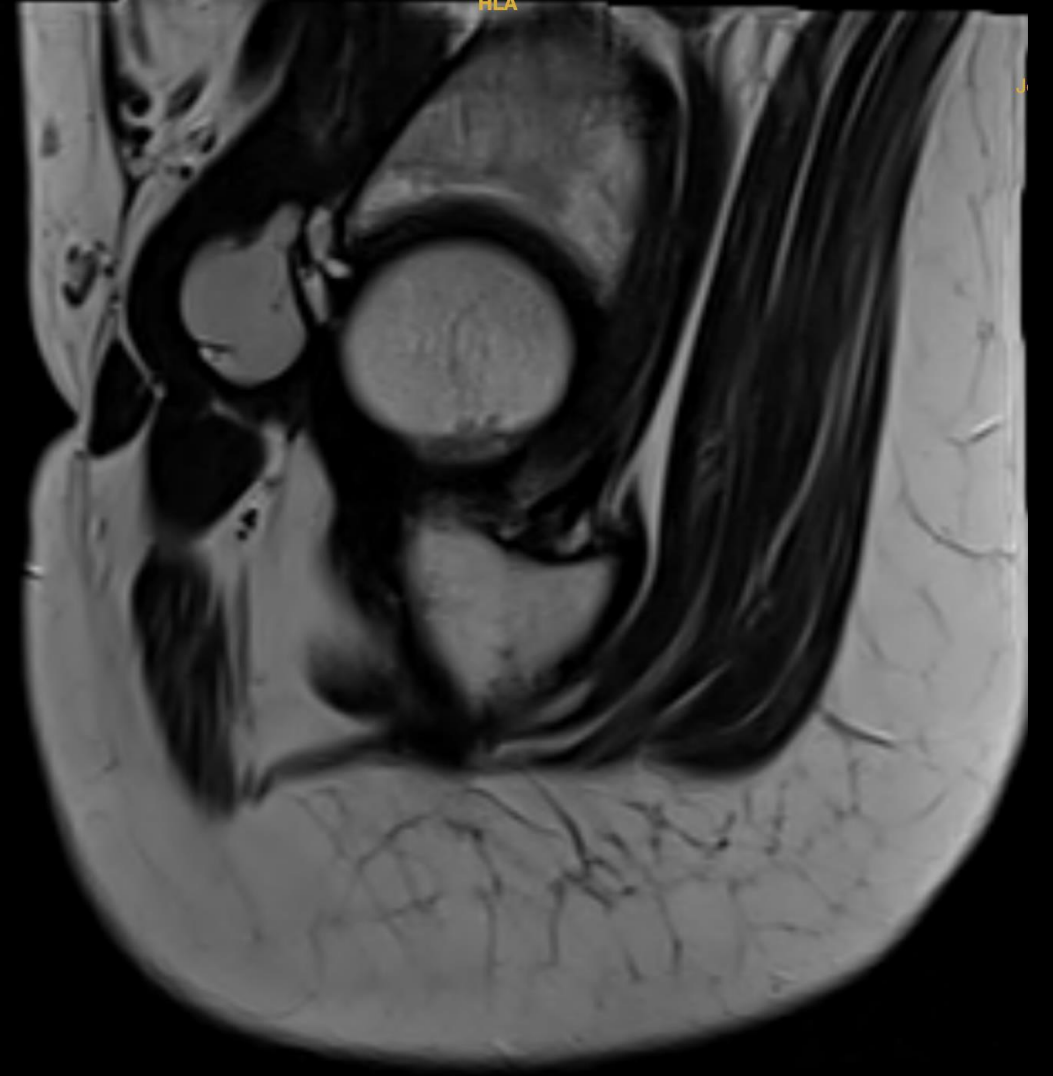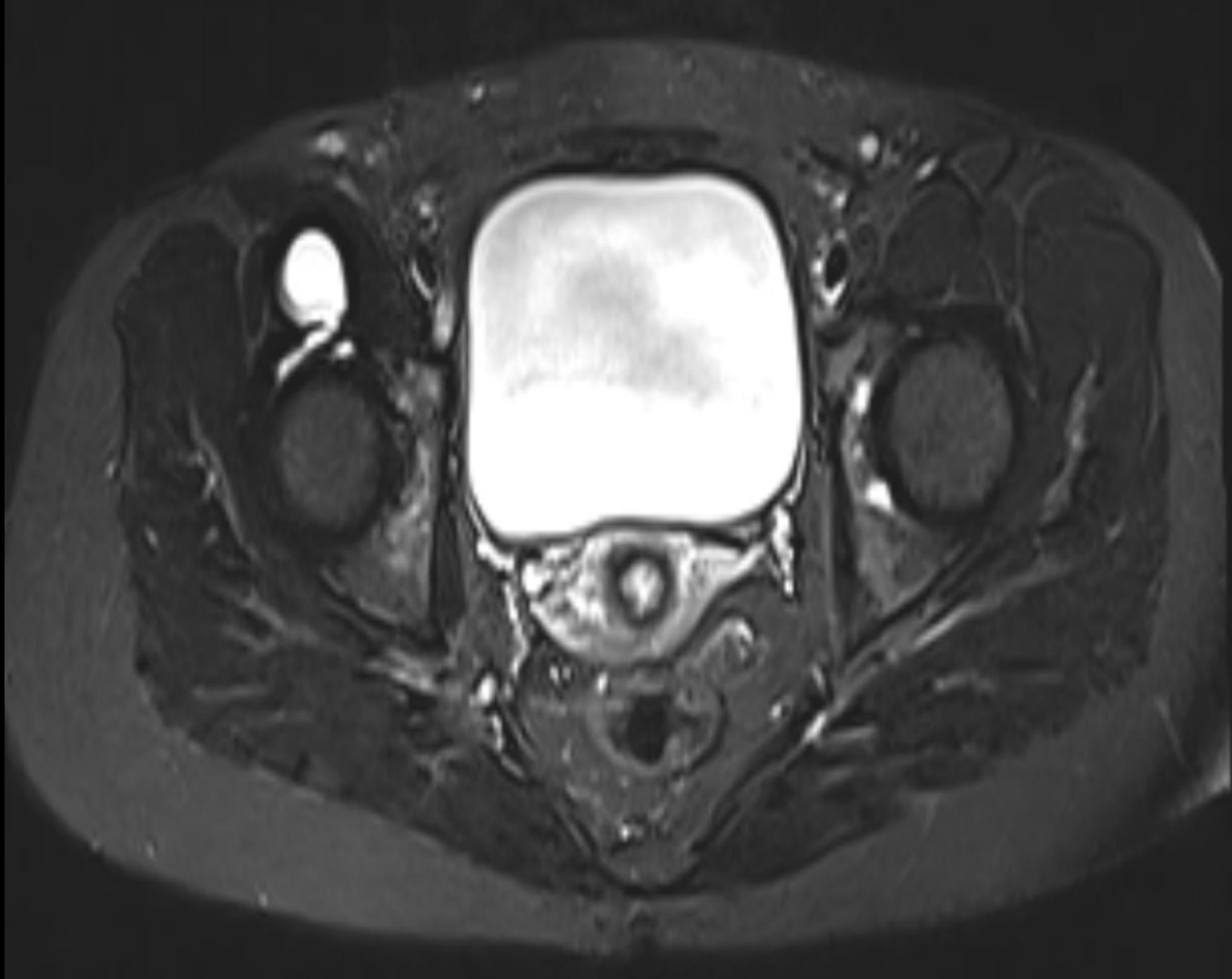
Case contributor – Dr. Karan Asthana

# MI-COD

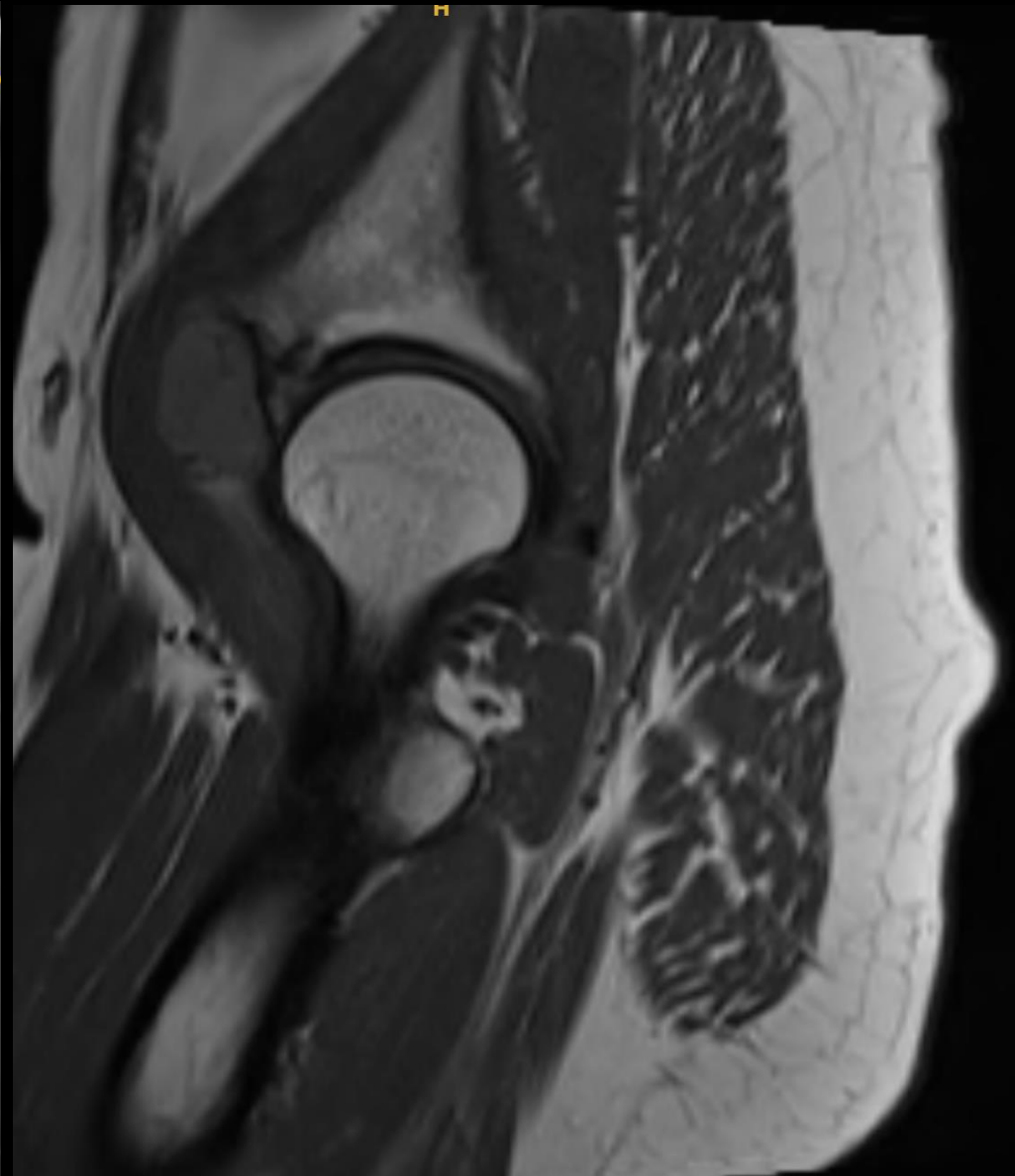
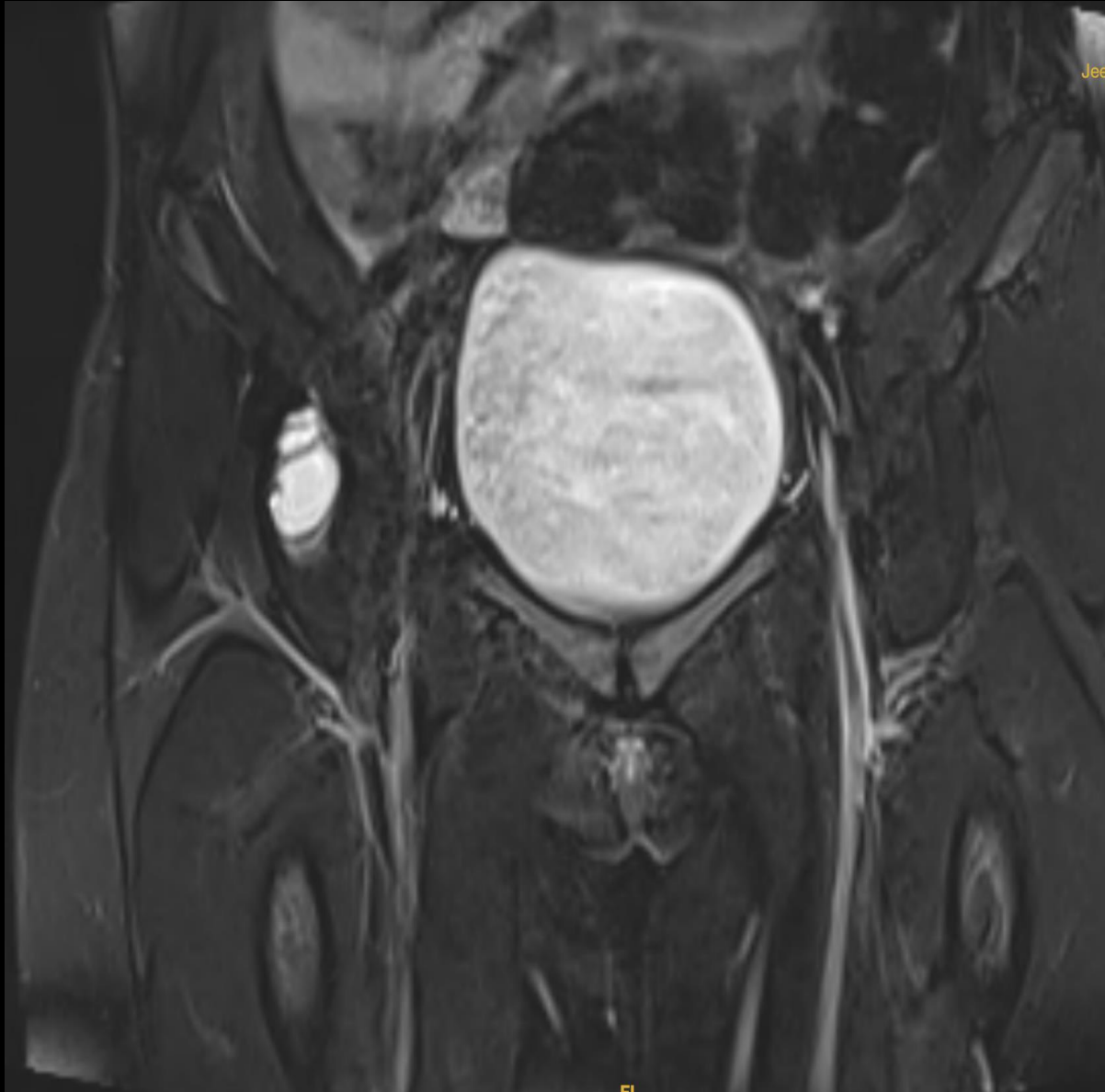MSS INDIA- Case Of the Day



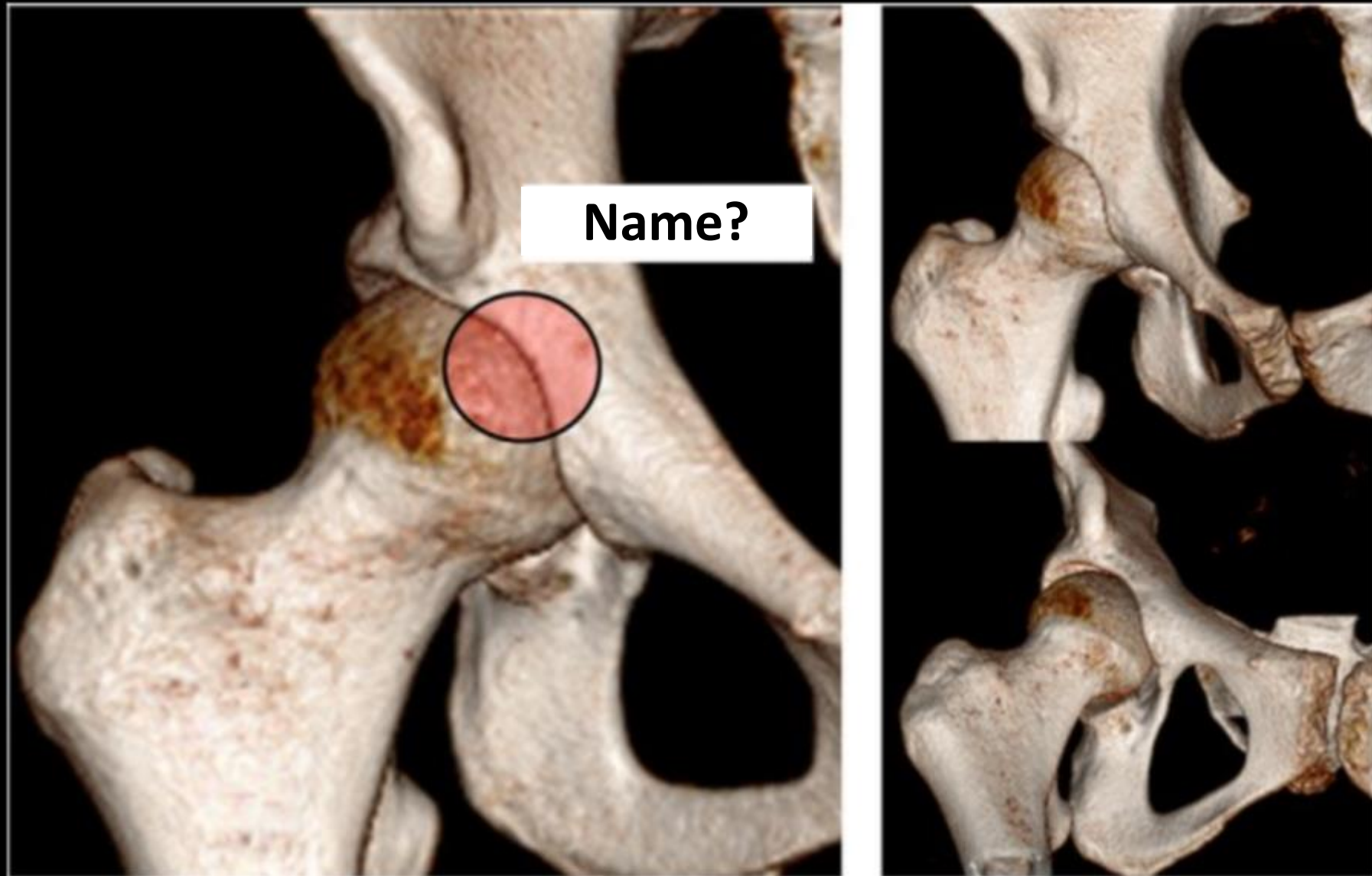
# Young lady with right hip pain



# Diagnosis?



Identify the anatomical spot?



# Clue

